
SINUS PERICRANII IN THE RIGHT FRONTAL REGION AND THROMBOSIS

**HONG-CAI WANG
YAN-BIN MA
ZHI-XIN DUAN
HONG ZHANG**

Department of Neurosurgery
No. 3 People's Hospital Affiliated to Shanghai Jiao Tong
University School of Medicine, Baoshan District
Shanghai, China

ZHI-XIN LI

Department of Radiology
No. 3 People's Hospital Affiliated to Shanghai Jiao Tong
University School of Medicine
Shanghai, China

Sinus pericranii is a rare vascular anomaly in which an abnormal communication exists between the extracranial venous system and the underlying dural venous sinus via the diploe of the skull. We describe a case of a spontaneous thrombosis of the sinus pericranii which was located in the right frontal region and presented as a focal, leathery, and noncompressible mass distinguished in character from the typical manifestation of sinus pericranii. In this case, CT, DSA, MRI, MR venography (MRV), and pathologic examination were performed. The CT showed the bone depression in the skull and the MRI demonstrated the mass, but they were not sufficiently sensitive to detect the thrombus. Pathologic examination and MRV

Received 17 April 2009.

We are grateful to our patient and her parents for giving us permission to publish this case with the pictures.

Address correspondence to Yan-bin Ma, M.D., Department of Neurosurgery, No. 3 People's Hospital Affiliated to Shanghai Jiao Tong University School of Medicine, No. 50 Mohe Road, Baoshan District Shanghai 201900, China. E-mail: mybxj@yahoo.com.cn

2262

were helpful in depicting the thrombus. She underwent a surgical resection, and at the 5-month follow-up there was no evidence of recurrence.

Keywords diploic vein, MRV, sinus pericranii, thrombosis

INTRODUCTION

Sinus pericranii, an unusual vascular anomaly involving a venous communication between the intracranial and extracranial venous systems via the diploe of the skull, was first reported by Hecker in 1845 and named by Stromeyerin in 1850 (Amano et al., 2002; Jung, Lee, Kim, Kang, & Lee, 2000). Sinus pericranii is asymptomatic in most cases and sometimes involves headache, vertigo, a feeling of fullness, or local pain (Sheu et al., 2002). Although sinus pericranii and its general features have been reported, the clinical manifestations and imaging characteristics of thromboses have been seldom discussed in detail. Here, we report a patient with sinus pericranii presenting with a focal, leathery, and noncompressible mass (approximately 2.8 cm × 2.5 cm × 1.4 cm) secondary to spontaneous thrombosis.

CASE REPORT

Clinical Manifestations

A 27-year-old female was admitted to our hospital with a chief complaint of a leathery and vague painful mass in the right frontal region, with a sudden significant increase (from approximately 1–3 cm) and nonreducibility. There were no neurologic deficits on physical examination and she denied prior neurologic problems or trauma to this area. The mass lesion was incidentally discovered two months before admission, which had been soft, fluctuant, nonpulsatile, compressible with pressure, and varied in size with changes in intracranial pressure. Over a two-month period, the mass did not increase significantly and she also did not feel any discomfort.

Neurologic Imaging

The CT showed a prominent soft tissue mass superficial to the thinning skull and the well-defined defects of the outer and inner bone plates in the right frontal region. The lesion was extracranial and intimately associated with the skull (Figure 1). Digital subtraction cerebral angiography (DSA) did not confirm the transosseous connection with the flow of blood from the sagittal

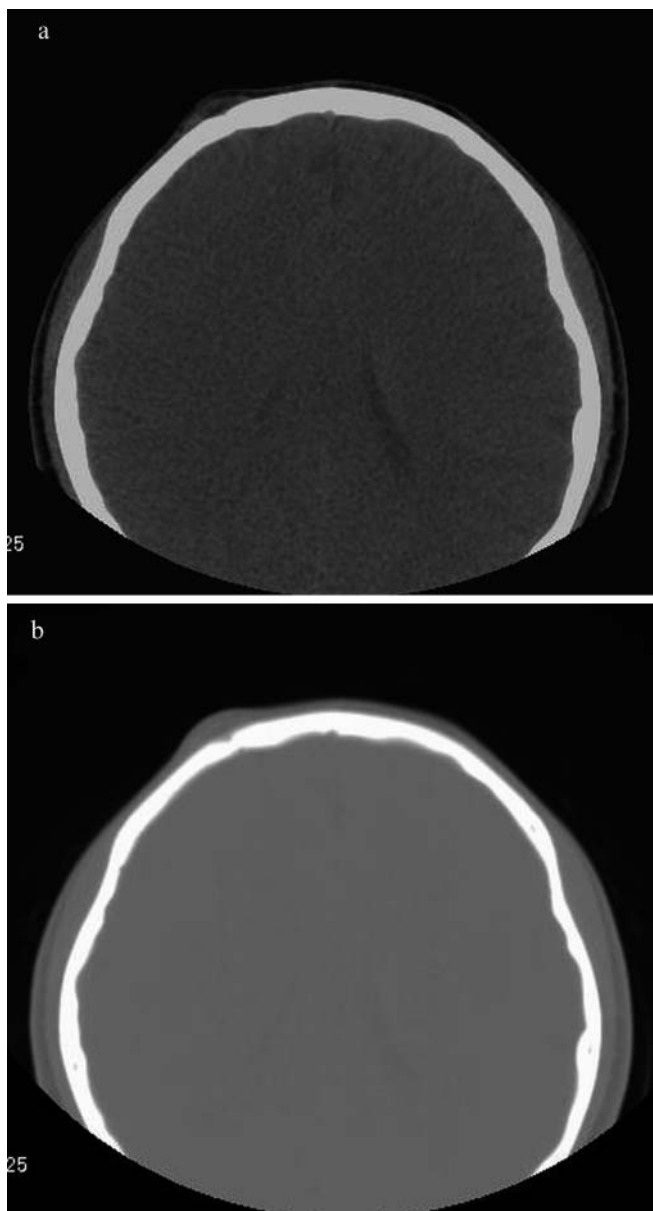


Figure 1. Axial CT scans. Plain (a) and bone (b) windows showing a subcutaneous mass and the well-defined defects of the outer and inner bone plates in the right frontal region, but without evidence of a diploic vein traversing the defect.

sinus to the mass and from the mass to an adjacent intracranial vein, but it demonstrated no vessel abnormalities in cerebral parenchyma and no arterial supply to the mass. An MRI revealed an extracalvarial mass that was isointense on T1-weighted MRI and slightly hyperintense on T2-weighted MRI. In addition, the T2-weighted MRI also depicted the diploic vein, but no distinct thrombus was demonstrated (Figure 2). MR venography (MRV) manifested the typical features of sinus pericranii and provided more information about the thrombosis; specifically, the mass was not distinctly enhanced and one diploic vein with a dilated vein in the mass was apparently enhanced. No other abnormalities were demonstrated (Figure 3).

Surgical Procedure

In consideration of cosmetics and for prevention of traumatic bleeding or air embolism, surgical resection was offered to the patient. Under general anesthesia, the patient was placed in the supine position. To reduce bleeding, her head was elevated to approximately 15°. A semicoronal skin incision around the mass within the hair-line was made in the right frontal region. Then, the scalp was gently separated from the periosteum and a purplish firm mass without a superficial draining vein was observed through the periosteum on the skull. Numerous vascular communications were present in the crater-like depression of the skull. The emissary veins were coagulated and resected. Then, the bone holes just beneath the mass were packed with fibrin sealant and bone wax following careful coagulation of the ends of the resected veins (Figure 4). The course of the surgery was uncomplicated and there was no transfusion required. No blood leakage from the diploic holes was confirmed during bilateral jugular vein compression and a Valsalva maneuver before closure.

Pathologic Finding and Follow-up

Paraffin sections showed that numerous irregular sinuses lined by a single layer of endothelial cells were filled with thrombi (Figure 5). The postoperative recovery was uneventful, and she was discharged four days after surgery. No recurrence was noted five months after surgery.

DISCUSSION

Sinus pericranii is a condition in which there is a collection of nonmuscular venous blood vessels adhering tightly to the outer surface of the skull and in

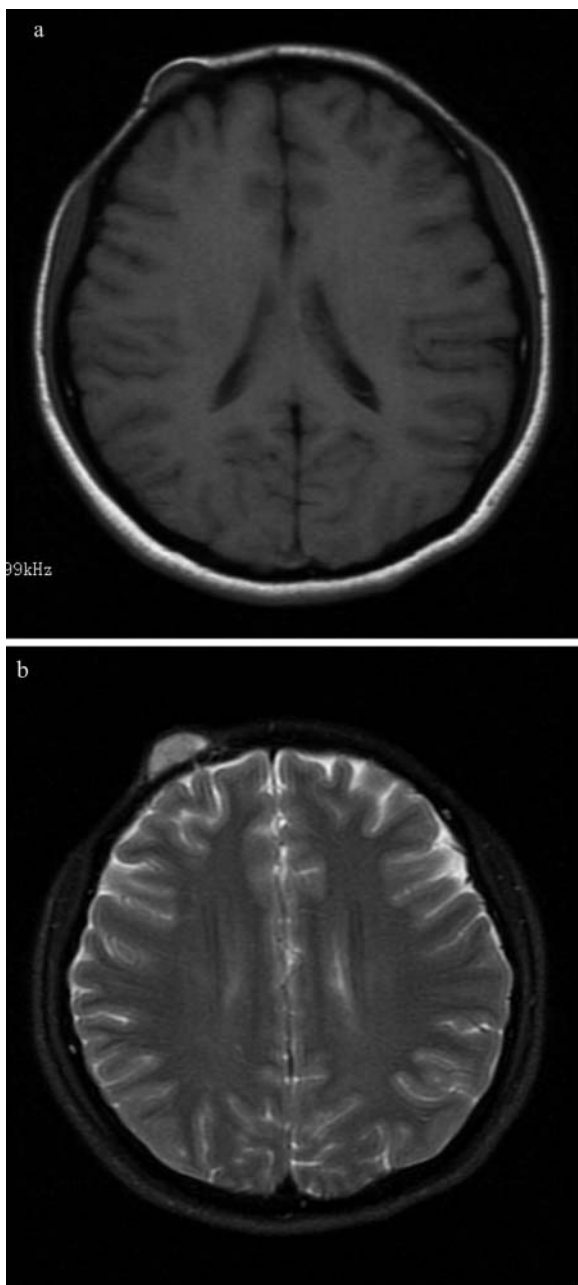


Figure 2. Axial MRI showing the subperiosteum mass to be isointense on T1-weighted MRI (a) and slightly hyperintense on T2-weighted MRI (b). A distinct diploic vein was also shown and the rest of the cortical veins showed no abnormalities.

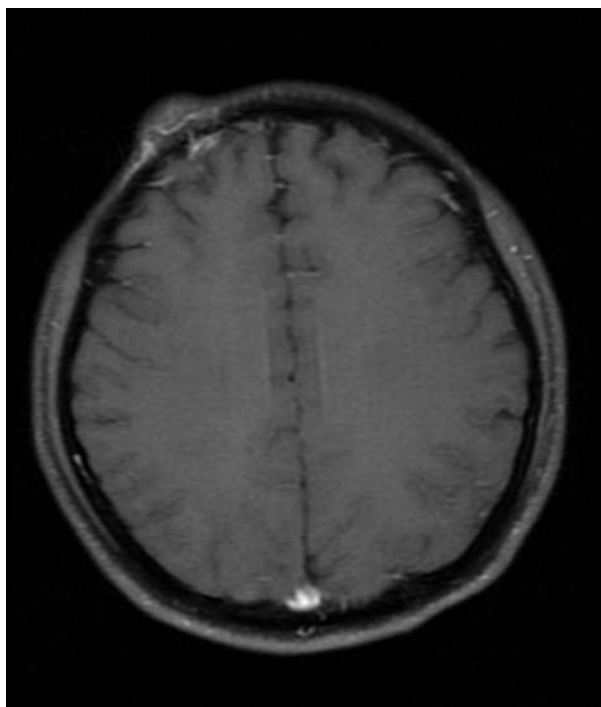


Figure 3. MR venography showing a diploic vein with a dilated vessel within the mass and sinus sagittal sinus apparently enhanced. The mass was not clearly enhanced.

which there is direct communication with the intracranial venous sinus via many diploic veins of various sizes (Nishio, Sakauchi, Murata, Nishikawa, & Nishimura, 1989). This condition can occur at any age, but most patients are < 30 years of age, with a male-to-female ratio of approximately 2:1 (Azusawa, Ozaki, Shindoh, & Sumi, 2000). The venous collection, without arterial feeding, receives blood from and drains into the intracranial venous sinus and most commonly involves the frontal region, followed by the parietal and occipital regions (Ota, Waga, Handa, Nishimura, & Mitani, 1975). The etiologies of sinus pericranii include congenital, spontaneous, and traumatic causes. The main difference between congenital and acquired sinus pericranii is the presence of an endothelial lining (Stromeyer, 1993). In our patient, the sinus pericranii was situated in the right frontal region, and occurred spontaneously at 27 years of age.

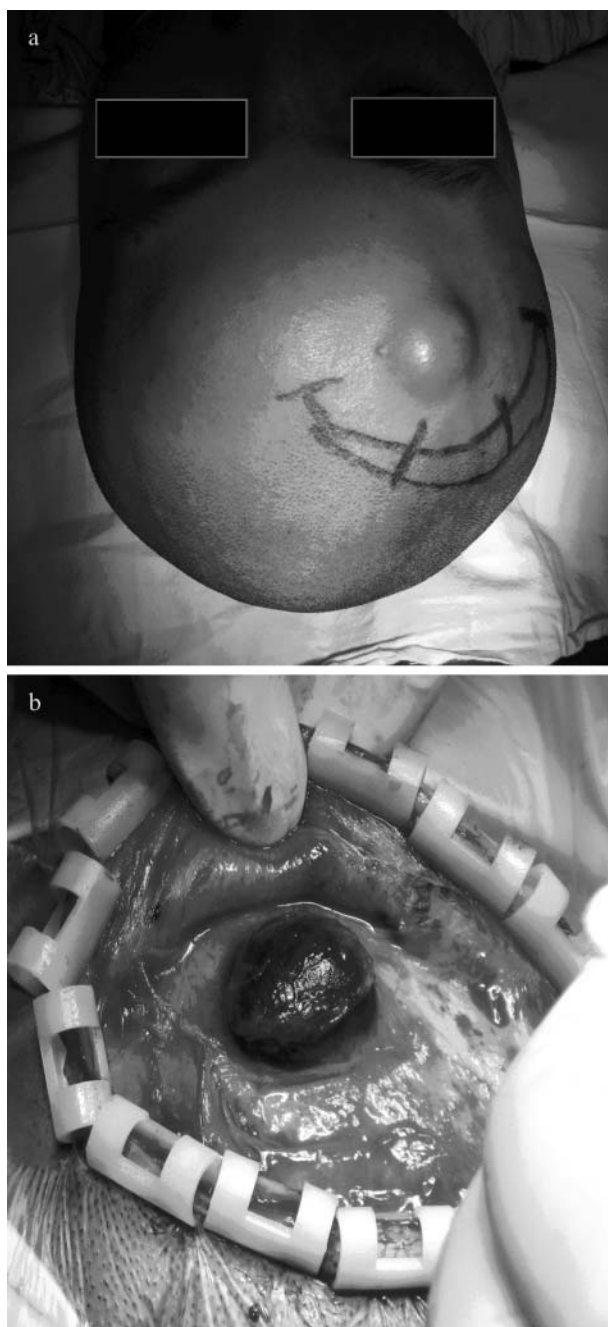


Figure 4. Operative photographs showing a firm mass in the right frontal region (a) and a purplish mass without superficial draining vein intimately adhering to the skull (b). Multiple small diploic holes and a crater-like depression in the skull surface were present (c). (*Continued*)

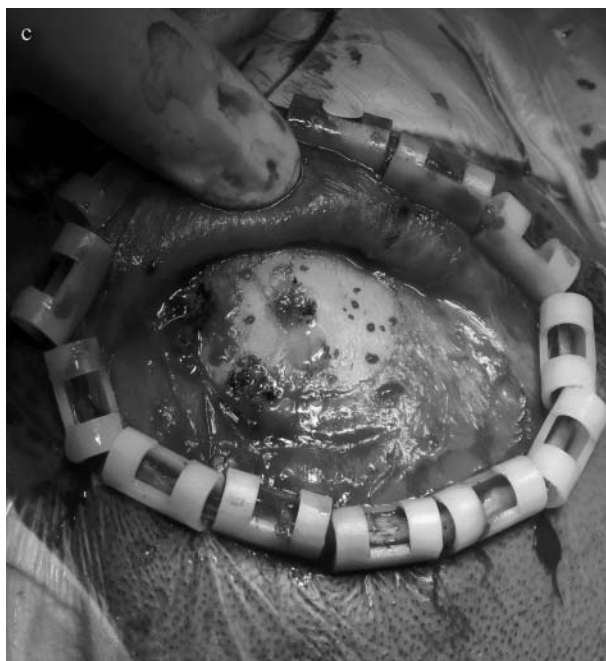

Figure 4. (Continued)

Most often, sinus pericranii is asymptomatic and presents as a soft, fluctuant, nonpulsatile, and compressible mass lesion. Return of venous blood on pressure and change in size with position (disappearing in the standing position and enlarging in the recumbent position) are important clinical features in the diagnosis (Kaido, Kim, & Ueda, 2006). With all these special clinical presentations, sinus pericranii can be easily distinguished from other subcutaneous masses of the scalp, including cavernous hemangiomas, arteriovenous malformations, sebaceous and dermoid cysts, abscesses, and meningoceles. Our patient presented with a sudden increase in prominence and nonreducibility of a mass and had new onset of localized pain and fullness. According to clinical experience, mass lesions with rapidly changing characters and the onset of atypical pain may suggest an underlying neoplasm or infection. This sudden alteration in the character of the lesion was confusing and a series of radiologic examinations were obtained.

Many imaging modalities have been utilized in the diagnosis of sinus pericranii (Higuchi, Fujimoto, Ikeda, & Kato, 1997; Sadler, Tarr, Jungreis,

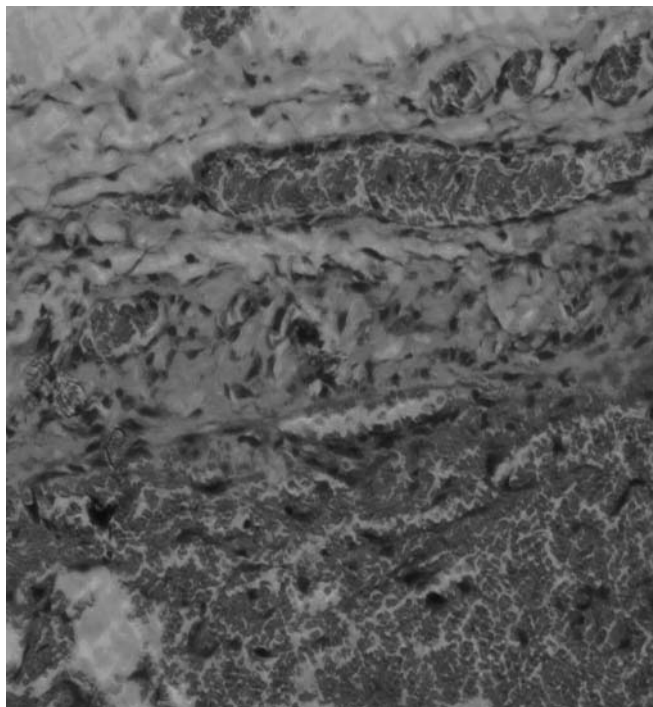


Figure 5. Photomicrographs of the lesion specimen showing the cystic wall lined by single layer of endothelial cells and most sinusoid vessels filled with thrombi. (Hemotoxylin and eosin staining; original magnification $\times 100$.)

& Sekhar, 1990). The CT scan will demonstrate a raised soft tissue mass intimately overlying the skull and the osseous abnormality which varies from complete absence of the bone to multiple small irregular crevices, or even to fine honeycombing apparent only microscopically (Wen, Chang, Wang, Kuo, & Tu, 2005). Because the abnormal communication between the intracranial and extracranial systems via the diploe of the skull is the diagnostic criteria of sinus pericranii, findings such as bone depression or diploic holes are helpful to the diagnosis. It has been reported that digital subtraction cerebral angiography (DSA) best demonstrates the abnormal communication and supplies the most complete information about the mass lesion (Azusawa et al., 2000; Kaido et al., 2006; Sadler et al., 1990). Our patient, however, showed no evidence of a connection between the lesion and intracranii venous sinus on angiography. Although percutaneous angiography has a great advantage in depicting the

diploic vein (Anegawa, Hayashi, Torigoe, Nakagawa, & Ogasawara, 1997), it was not used in this patient considering the possibility of thrombosis. The MRI can display a characteristic soft mass extending through the calvaria. In our patient, a diploic vein was also shown on MRI. From these findings, the diagnosis of sinus pericranii was made. Owing to the MR signal intensity related to the blood flow velocity, evolution of hemoglobin, late venous recanalization and breakdown of red blood cells (Favrole, Guichard, Crassard, Bousser, & Chabriat, 2004), MRI is difficult in distinguishing a thrombus from venous blood according to signal intensity only. CT or MRI can show certain characteristic findings of sinus pericranii; however, MRV is useful in visualizing the entire lesion (Azusawa et al., 2000; Bollar, Allut, Prieto, Gelabert, & Becerra, 1992). In the patient presented herein, the MRV depicted the typical features of sinus pericranii and suggested a thrombosis. One transosseous vein with a dilated vessel within the mass was apparently enhanced and the mass was not distinctly enhanced; besides no other vascular abnormalities were appreciated. We cannot explain the phenomenon that DSA did not show the venous communication clearly. Due to the several days which elapsed between the other imaging examination and DSA, we speculate the main venous communication was also thrombosed when the DSA examination was performed. Menon, Muzumdar, Shah, & Goel (2009) demonstrated that CT venography is also helpful in depicting intraluminal thrombi. Thrombosis indicates a course of repeated microscopic bleeding and stasis of the venous blood. The large venous flow coming through the vascular channel and the rapid flow change between the intracranii and extracranii components may cause venous stasis and obstruction of the communicating fistula (Witrak, Davis, & Hoffman, 1986).

Sinus pericranii are usually asymptomatic. However, they may be surgically treated for cosmetic reasons and to prevent spontaneous rupture or massive haemorrhage and air embolism after trauma (Rozen, Joseph, & Lo, 2008). In our patient, the sinus was completely removed with the diploic blood channels of the skull obliterated by bone wax and fibrin sealant. In the near future, treatment with intravascular embolization will be possible.

CONCLUSION

Sinus pericranii is one of the differential diagnoses which should be considered when a physician encounters a patient with a soft, subcutaneous scalp mass. With the emergence of thrombosis, the diagnosis becomes complicated and should draw support from multiple imaging modalities. In addition, the case

history is also very significant in the diagnosis and the definitive diagnosis is made by surgical removal and pathologic confirmation.

REFERENCES

- Amano, T., Inamura, T., Morioka, T., Nagata, S., Nakamizo, A., Inoha, S., et al (2002). A case of traumatic sinus pericranii. *No Shinkei Geka*, *30*, 217–221.
- Anegawa, S., Hayashi, T., Torigoe, R., Nakagawa, S., & Ogasawara, T. (1997). Sinus pericranii with severe symptom due to transient disorder of venous return: Case report. *Neurologia Medico-Chirurgica*, *31*, 287–289.
- Azusawa, H., Ozaki, Y., Shindoh, N., & Sumi, Y. (2000). Usefulness of MR venography in diagnosing sinus pericranii: Case report. *Radiation Medicine*, *18*, 249–252.
- Bollar, A., Allut, A. G., Prieto, A., Gelabert, M., & Becerra, E. (1992). Sinus pericranii: Radiological and etiopathological considerations. *Journal of Neurosurgery*, *77*, 469–472.
- Favrole, P., Guichard, J. P., Crassard, I., Bousser, M. G., & Chabriat, H. (2004). Diffusion-Weighted imaging of intravascular clots in cerebral venous thrombosis. *Stroke*, *35*, 99–103.
- Higuchi, M., Fujimoto, Y., Ikeda, H., & Kato, A. (1997). Sinus pericranii: Neuroradiologic findings and clinical management. *Pediatric Neurosurgery*, *27*, 325–328.
- Jung, S., Lee, J. K., Kim, S. H., Kang, S. S., & Lee, J. H. (2000). Parietal sinus pericranii: Case report and technical note. *Surgical Neurology*, *54*, 270–273.
- Kaido, T., Kim, Y. K., & Ueda, K. (2006). Diagnostic and therapeutic considerations for sinus pericranii. *Journal of Clinical Neuroscience*, *13*, 788–792.
- Menon, R. K., Muzumdar, D., Shah, A., & Goel, A. (2009). Blood-fluid level in cortical venous thrombosis—a rare diagnosis entity. *Surgical Neurology*, *71*, 111–114.
- Nishio, A., Sakauchi, M., Murata, K., Nishikawa, M., & Nishimura, S. (1989). Laterally situated sinus pericranii: Case report. *Surgical Neurology*, *32*, 382–386.
- Ota, T., Waga, S., Handa, H., Nishimura, S., & Mitani, T. (1975). Sinus pericranii. *Journal of Neurosurgery*, *42*, 704–712.
- Rozen, W. M., Joseph, S., & Lo, P. A. (2008). Spontaneous involution of two sinus pericranii—a unique case and review of the literature. *Journal of Clinical Neuroscience*, *15*, 833–835.
- Sadler, L. R., Tarr, R. W., Jungreis, C. A., & Sekhar, L. (1990). Sinus pericranii: CT and MR findings. *Journal of Computer Assisted Tomography*, *14*, 124–127.
- Sheu, M., Fauteux, G., Chang, H., Taylor, W., Stopa, E., & Robinson-Bostom, L. (2002). Sinus pericranii: Dermatologic considerations and literature review. *Journal of the American Academy of Dermatology*, *46*, 934–941.
- Stromeyer, L. (1993). About sinus pericranii (translation of original 1850 text). *Surgical Neurology*, *40*, 3–4.

- Wen, C. S., Chang, Y. L., Wang, H. S., Kuo, M. F., & Tu, Y. K. (2005). Sinus pericranii: From gross and neuroimaging findings to different pathophysiological change. *Child's Nervous System, 21*, 482–488.
- Witrak, B. J., Davis, P. C., & Hoffman, J. C. (1986). A case report: Sinus pericranii. *Pediatric Radiology, 16*, 55–56.

Copyright of International Journal of Neuroscience is the property of Taylor & Francis Ltd and its content may not be copied or emailed to multiple sites or posted to a listserv without the copyright holder's express written permission. However, users may print, download, or email articles for individual use.