

Case Reports

Giant Cystic Lesion in Neurofibromatosis

Rony Cohen, MD*, Liora Kornreich, MD[†],
and Avinoam Shuper, MD*

In the case of an asymptomatic 10-year-old girl with neurofibromatosis type 1, a concomitant cystic brain lesion was demonstrated on cranial magnetic resonance imaging. The nature of these cysts is unknown: they may represent cellular degeneration of the lesions imaged as unidentified bright objects, cystic cortical dysplasia, or giant Virchow-Robin spaces. The novel finding in this child of coexisting unusual cystic lesion and neurofibromatosis could be coincidental; however, recent report of an asymptomatic cystic lesion in two patients with neurofibromatosis suggests otherwise. © 2009 by Elsevier Inc. All rights reserved.

Cohen R, Kornreich L, Shuper A. Giant cystic lesion in neurofibromatosis. *Pediatr Neurol* 2009;41:445-447.

Introduction

Imaging of the brain in neurofibromatosis can reveal a wide range of abnormalities, from unidentified bright objects (i.e., lesions seen as high-intensity signal on T₂-weighted magnetic resonance imaging [MRI]) to high-grade tumors. Many of these lesions do not require any treatment, which raises the question of whether performing MRI in neurofibromatosis without clear-cut clinical grounds for doing so is justified. Reported here is the case of an asymptomatic child with neurofibromatosis type 1 whose MRI demonstrated the presence of a very unusual cystic brain lesion.

Case Report

A 10-year-old girl was monitored for neurofibromatosis type 1. She had been diagnosed clinically on the basis of many café-au-lait spots and axillary freckling. Findings from her neurologic examination were

normal, and her head circumference was 54 cm (75th percentile). She had two healthy siblings, and there was no family history for neurofibromatosis type 1 or other major disease. Her birth history and neonatal milestones were normal. Her motor development was normal, but her speech development was delayed. She was eventually diagnosed as having normal intelligence with learning disabilities. There was no history of epilepsy, and her electroencephalogram was normal.

At age 9.5 years, she had cranial MRI, which revealed multiple cysts in the right frontal area, isointense to cerebrospinal fluid on all sequences (Fig 1), with a maximal diameter of 2 to 13 mm. The cysts appeared cortically and subcortically, causing a mass effect on the adjacent cortex, but there was no surrounding edema or enhancement after contrast injection (Fig 2). A few lesions that were hyperintense on T₂-weighted images, typical for unidentified bright objects of neurofibromatosis type 1, were also seen in the basal ganglia (Fig 3). A second MRI scan performed 16 months later showed no change.

Discussion

Magnetic resonance imaging was performed on a child with neurofibromatosis type 1 as a part of the protocol of evaluation of these children. The brain lesion found was entirely unexpected. She had no neurologic symptoms or convulsions, and her cognition was normal. What these cysts represent is something of a mystery: the nature of these lesions is unknown, and such findings have not been reported previously in cases of neurofibromatosis.

Cystic brain lesions have been reported in tuberous sclerosis, another neurocutaneous disease, in which the cysts were assumed to represent cellular degeneration of cortical tuber. Rott et al. [1] described three patients with large cyst-like brain lesions in the subcortical area and assumed that the lesions represented cellular degeneration of cortical tuber. Jurkiewicz et al. [2] reviewed MRI scans of 73 patients with tuberous sclerosis complex and found that 17 had cyst-like cortical lesions.

The appearance of the cysts on MRI in the present case differs from that for patients with tuberous sclerosis complex. Because the cysts in tuberous sclerosis complex are located inside cortical tubers, there is always a peripheral hyperintense signal on T₂-weighted images and on fluid attenuated inversion recovery sequences [2]. The cystic spaces in the present case could not be related to the unidentified bright objects of neurofibromatosis, because it would be highly unusual for the latter to undergo cystic degeneration and because the location of our patient's cystic spaces was not one in which unidentified bright objects are generally found.

From the *Department of Pediatric Neurology and Epilepsy Center and the †Department of Pediatric Radiology, Schneider Children's Medical Center, Petach-Tikva, Israel.

Communications should be addressed to:
Dr. Cohen; Department of Pediatric Neurology and Epilepsy Center,
Schneider Children's Medical Center; 14 Kaplan Street;
Petach-Tikva 49202, Israel.
E-mail: cohenzr@bezeqint.net
Received February 18, 2009; accepted June 30, 2009.

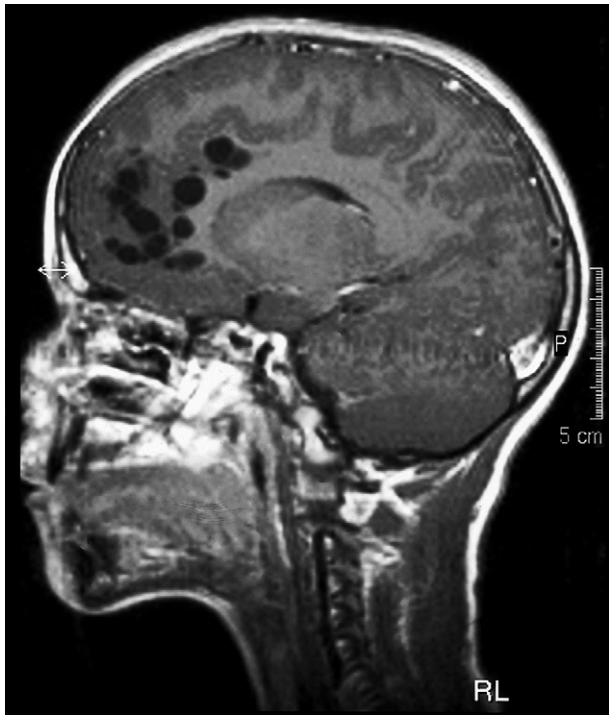


Figure 1. Sagittal T_1 -weighted magnetic resonance image after contrast injection (TR/TE = 596/15 ms). No enhancement is present.

Might these cysts represent some kind of cortical malformation? Abnormal cortical developments are less common in patients with neurofibromatosis than in those with other neurocutaneous syndromes, but there are several case

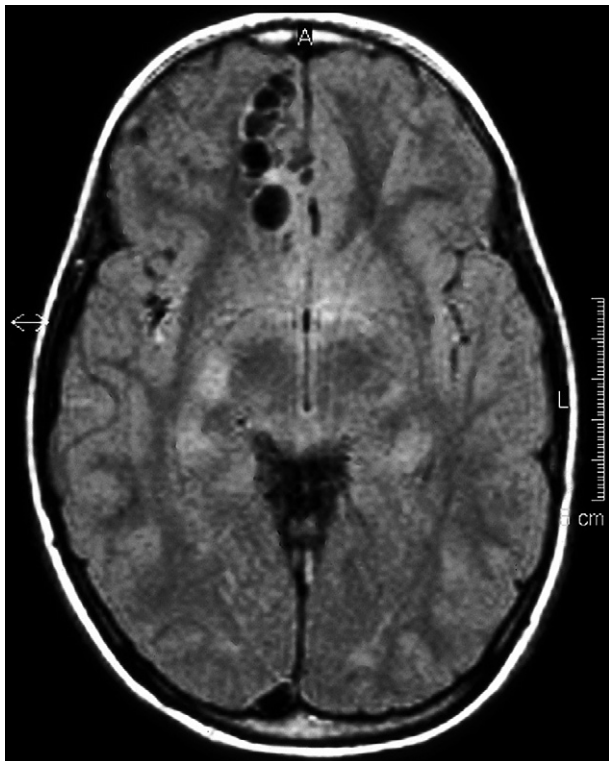


Figure 2. Axial fluid-attenuated inversion recovery magnetic resonance image (TR/TE/TI = 6000/140/2000 ms). The cysts are isointense with cerebrospinal fluid.

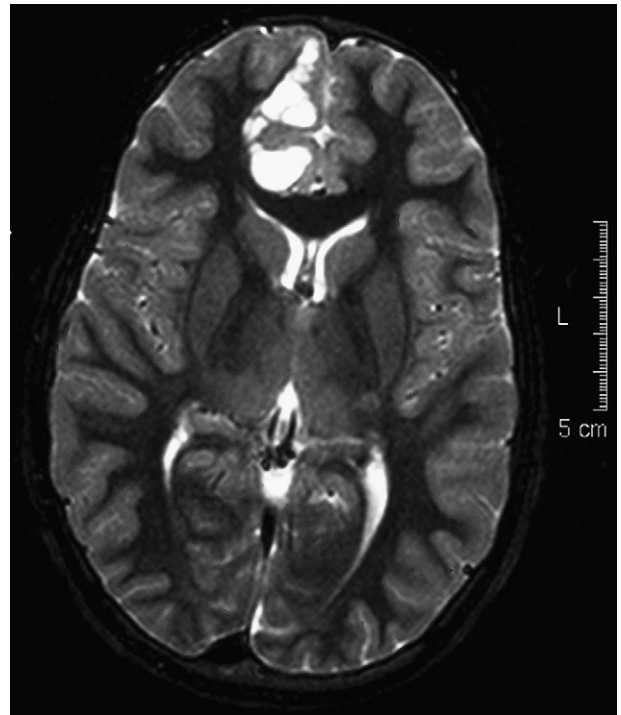


Figure 3. Axial T_2 -weighted magnetic resonance image (TR/TE = 4427/100 ms). Multiple cortical and subcortical cysts are seen. Note pressure on and distortion of the adjacent cortex, without any surrounding edema.

reports that suggest a possible association of cortical malformation and neurofibromatosis type 1 [3,4].

Neurofibromin, the protein product of the neurofibromatosis type 1 type gene, is known to play an important role in the process of cortical development. Neurofibromin was found to be a regulator of neuroglial progenitor function [5], and it is required for normal glial and neuronal development [6]. It was recently demonstrated that mice that lack neurofibromin in the majority of their cortical neurons and in their astrocytes fail to form a normal cortex [7]. Nonetheless, despite such a convincing explanation of the association between neurofibromatosis type 1 and brain development, it would still be considered unusual for a patient with neurofibromatosis type 1 who also has such cranial lesions to be asymptomatic and to be without mental retardation, seizures, or any other neurologic manifestations.

A third possibility is that these lesions represent giant Virchow-Robin spaces, which contain CSF and are extensions of subarachnoid spaces that accompany small vessels as they penetrate the brain [8]. On MRI, the dilations of Virchow-Robin spaces are characteristically round and ovoid, with the same signal intensity as cerebrospinal fluid, and follow the paths of the perforating vessels. The dilations of Virchow-Robin spaces are considered abnormal when they exceed 2 mm in diameter [9]. An extreme widening of Virchow-Robin spaces is rare, and there are only a few reports describing this occurrence (and only in adults, who display varying clinical symptoms) [10-13].

The clinical significance of dilated Virchow-Robin spaces and the etiology in childhood are unclear: it can be idiopathic or associated with a pathologic condition, such as

mucopolysaccharidosis [14]. Artigas et al. [15] described two children with progressive macrocephaly, normal development, and dilated Virchow-Robin spaces. Rollins et al. [16] reported that 37 out of 1250 children who had cranial brain MRI were found to have dilated Virchow-Robin spaces. Those authors were able to correlate dilated Virchow-Robin spaces with headache, developmental delay, and psychiatric problems. In that same study, of 66 patients with neurocutaneous disorders, 2 had dilated Virchow-Robin spaces, and both were neurofibromatosis patients, but the prevalence of enlarged Virchow-Robin spaces in this subgroup of patients was not significant. Moreover, the maximal diameter of the cystic spaces was 7 mm and most of them were about 3 mm in diameter, therefore they probably represented a different entity from that of our patient whose MRI demonstrated giant spaces.

Other possible explanations for multiple-cyst lesions include meningioangiomas, a benign hamartomatous lesion found in the cerebral cortex that can also be associated with neurofibromatosis type 1 [17]. This explanation is highly unlikely to be applicable in the present case, because meningioangiomas usually presents clinically as partial seizures that are difficult to control.

Lymphangiomyomatosis, a rare disease that can result from proliferation of smooth muscle cells, can present with cystic lesions in the lungs and may occur in conjunction with a neurocutaneous disease, such as tuberous sclerosis complex [18]. Cystic lesions within the white matter can also appear in specific leukoencephalopathies [19].

Neurofibromatosis type 1 is not an uncommon disorder, and affected individuals frequently have brain imaging. Despite the wide range of abnormalities that can be found in brain imaging studies, the possibility cannot be excluded that in the present case the coexistence of neurofibromatosis type 1 and cysts in an asymptomatic patient is coincidental.

Cho et al. [20] reported two patients with neurofibromatosis type 1 and asymptomatic central nervous system cyst malformation in the brain and in the spine. It is tempting to consider those lesions as representing another brain malformation in neurofibromatosis type 1, but further information would be required to confirm or rule out this possibility.

References

[1] Rott H-D, Lemcke B, Zenker M, Huk W, Horst J, Mayer K. Cyst-like cerebral lesions in tuberous sclerosis. *Am J Med Genet* 2002;111:435-9.

[2] Jurkiewicz E, Jozwiak S, Bekiesinska-Figatowska M, Pakula-Kosciesza Walecki J. Cyst-like cortical tubers in patients with tuberous sclerosis complex: MR imaging with the FLAIR sequence. *Pediatr Radiol* 2006;36:498-501.

[3] Rosman NP, Pearce J. The brain in multiple neurofibromatosis (von Recklinghausen's disease): a suggested neuropathological basis for the associated mental defect. *Brain* 1967;14:829-38.

[4] Cusmai R, Curatolo P, Mangano S, Cheminal R, Echenne B. Hemimegalencephaly and neurofibromatosis. *Neuropediatrics* 1990;21:179-82.

[5] Balestri P, Vivarelli R, Santori L, et al. Malformation of cortical development in neurofibromatosis type 1. *Neurology* 2003;61:1799-801.

[6] Hegedus B, Dasgupta B, Shin JE, et al. Neurofibromatosis-1 regulates neuronal and glial cell differentiation from neuroglial progenitors in vivo by both cAMP- and Ras-dependent mechanisms. *Cell Stem Cell* 2007;1:443-57.

[7] Lush ME, Li Y, Kwon CH, Chen J, Parada LF. Neurofibromin is required for barrel formation in the mouse somatosensory cortex. *J Neurosci* 2008;28:1580-7.

[8] Adachi M, Hosoya T, Haku T, Yamaguchi K. Dilated Virchow-Robin spaces: MRI pathological study. *Neuroradiology* 1998;40:27-31.

[9] Groeschel S, Chong WK, Surtees R, Hanefeld F. Virchow-Robin spaces on magnetic resonance images: normative data, their dilatation, and a review of the literature. *Neuroradiology* 2006;48:745-54.

[10] Ogawa T, Okudera T, Fukasawa H, et al. Unusual widening of Virchow-Robin spaces: MR appearance. *AJNR Am J Neuroradiol* 1995;16:1238-42.

[11] Shiratori K, Mrowka M, Toussaint A, Spalke G, Bien S. Extreme, unilateral widening of Virchow-Robin spaces: case report. *Neuroradiology* 2002;44:990-2.

[12] Mathias J, Koessler L, Brissart H, et al. Giant cystic widening of Virchow-Robin spaces: an anatomofunctional study. *AJNR Am J Neuroradiol* 2007;28:1523-5.

[13] Heier LA, Bauer CJ, Schwartz L, Zimmerman RD, Morgello S, Deck MD. Large Virchow-Robin spaces: MR-clinical correlation. *AJNR Am J Neuroradiol* 1989;10:929-36.

[14] Kwee RM, Kwee TC. Virchow-Robin spaces at MR Imaging. *Radiographics* 2007;27:1071-86.

[15] Artigas J, Poo P, Rovira A, Cardo E. Macrocephaly and dilated Virchow-Robin spaces in childhood. *Pediatr Radiol* 1999;29:188-90.

[16] Rollins NK, Deline C, Morriss MC. Prevalence and clinical significance of dilated Virchow-Robin spaces in childhood. *Radiology* 1993;189:53-7.

[17] Park MS, Suh DC, Choi WS, Lee SY, Kang GH. Multifocal meningioangiomas: a report of two cases. *AJNR Am Neuroradiol* 1999;20:677-80.

[18] Hohman DW, Nogrehkar D, Ratnayake S. Lymphangiomyomatosis: a review. *Eur J Intern Med* 2008;19:319-24.

[19] Grosso S, Cerase A, De Stefano N, et al. Non-progressive leukoencephalopathy with bilateral anterior temporal cyst: a case report and review of the literature. *Brain Dev* 2005;27:73-7.

[20] Cho SB, Kim HS, Yang MS, Cho KW. Type 1 neurofibromatosis associated with asymptomatic cystic malformations of central nervous system (CNS). *Int J Dermatol* 2009;48:330-2.