

# Multifocal “tapete” papillary fibroelastoma

K B Law,<sup>1</sup> K R B Phillips,<sup>1</sup> R J Cusimano,<sup>2,3</sup> J Butany<sup>1,2</sup>

<sup>1</sup>Department of Pathology, Toronto General Hospital/University Health Network, Toronto, Ontario, Canada; <sup>2</sup>Faculty of Medicine, University of Toronto, Toronto, Ontario, Canada; <sup>3</sup>Division of Cardiac Surgery, Peter Munk Cardiac Centre, Toronto General Hospital, Toronto, Ontario, Canada

Correspondence to: Professor J Butany, Department of Pathology, Toronto General Hospital, 11th floor, 200 Elizabeth Street, Toronto, ON M5G 2C4, Canada; [jagdish.butany@uhn.on.ca](mailto:jagdish.butany@uhn.on.ca)

Accepted 22 July 2009

## ABSTRACT

Papillary fibroelastomas (PFEs) are benign cardiac tumours that typically arise on diseased aortic or mitral valves. Usually solitary, PFEs are characterised by numerous frond-like branches attached to the valve surface by a single stalk, elastic tissue present within the central core, and the appearance of a sea anemone when immersed in water. PFEs have a predilection for men with a mean age of 56 years. A very rare case of a 25-year-old man with multiple lesions on the aortic and mitral valves and a large confluent “carpet-like” lesion in the left ventricular cavity is presented. Admitted with a significant left middle cerebral artery stroke and hemiplegia, investigations showed a left ventricular outflow tract lesion, with surgical excision displaying a multifocal “carpet-like” PFE. Histopathological examination showed various lesions presenting with a short stem, several fronds arising from each stem like a “tree trunk”, and elastic tissue within the central core. This case is presented, along with a review of 833 reported cases of PFEs published after the year 2001. It is believed that this is the first reported instance of surgically resected and morphologically confirmed multiple PFEs seen and removed at one operation.

Primary cardiac tumours are rare, with an incidence of 0.001–0.030%,<sup>1</sup> with papillary fibroelastomas (PFEs) being the most common primary cardiac tumour.<sup>2</sup> Seventy-five per cent of primary cardiac tumours are benign, and PFEs are the second most common type of benign tumour of the heart, following myxomas.<sup>1</sup> PFEs typically arise from diseased aortic or mitral valve endocardium on the flow surface.<sup>1–3</sup> The tumour occurs predominantly on the left side of the heart,<sup>2–4</sup> and the majority are solitary lesions. PFEs are often believed to be associated with trauma and the wear-and-tear of valves.<sup>5</sup> In our case, there were multiple lesions on the aortic and mitral valves and a confluent “carpet-like” lesion on the left ventricular myocardium. Due to its “carpet-like” appearance, the name “tapete”, which is Latin for carpet, has been chosen to delineate the PFE.

## CASE REPORT

A 25-year-old man was admitted after suffering a major stroke consistent with left middle cerebral artery (MCA) occlusion by embolism, leaving him hemiplegic and aphasic. Investigations revealed evidence of three previous cerebrovascular accidents (CVAs).

A two-dimensional transoesophageal echocardiogram (2D-TEE), performed to determine the aetiology of the stroke, showed a 9.0 mm × 3.0 mm mass in the left ventricular outflow tract (LVOT) not evident on the transthoracic echocardiogram (TTE). When pulmonary emboli were discovered on a cardiac CT scan, anticoagulation

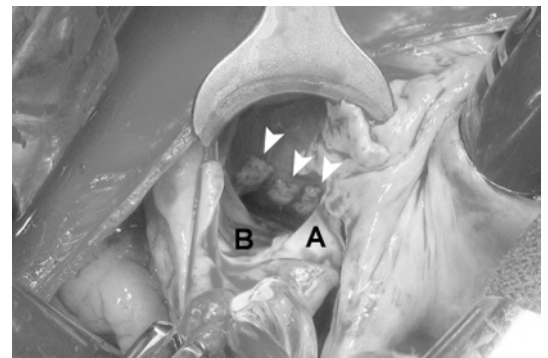
was commenced despite negative thrombophilia work-up. He had minor thalassaemia, but no sickle cell disease or trait. He tested negative for AP/anticardiolipin antibodies. A repeat TEE was performed one month later and showed no change in the size of the lesion. At this point, the diagnosis of a primary cardiac tumour, possibly a myxoma, was suggested and surgical excision was planned.

## Surgical procedure

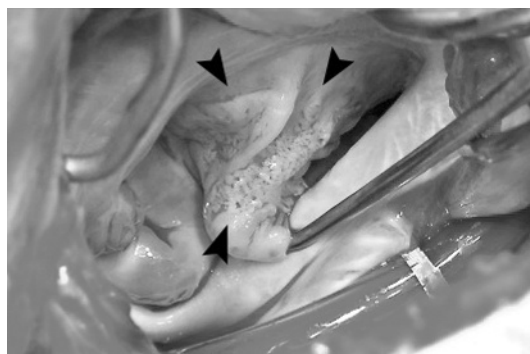
Given the LVOT location seen at preoperative TEE, the initial surgical approach was through the aortic root. Multiple lesions were found in the left ventricle, mainly evident on the LVOT septum. These lesions appeared to “carpet” the inside of the left ventricle with varied thickness, including the chordae tendinae, papillary muscle heads and the free left ventricular endocardium (fig 1). The aortic valve leaflets as well as the atrial surface of the mitral valve leaflet (fig 2) were also involved. Endocardial fibrosis was present on the endocardium. All visible endocardial lesions were excised. To remove the lesions on the chordae tendinae and papillary muscle heads, mitral valve replacement with a St Jude bileaflet mechanical valve was necessary. No lesions were noted in either the left atrium or aorta. A small linear thrombus (despite anticoagulation) appeared to cover one part of the left ventricular septal fibroelastoma (fig 3A). He made an uneventful recovery and was discharged home on lifelong warfarin therapy. Five months later he has continued to improve, having recovered some speech and ambulation. There have been no further clinical events and he is free of cardiac limitation.

## PATHOLOGY

The surgically excised specimens were photographed and examined grossly. The valvular lesions



**Figure 1** Intraoperative photograph showing three septal, subaortic lesions with PFE also present on the endocardium. A, aorta; B, aortic valve; arrows, papillary fibroelastomas on interventricular septum of the left ventricular outflow tract.



**Figure 2** Multiple, “confluent”, soft lesions (arrows) carpeting the anterior mitral leaflet on the atrial aspect.

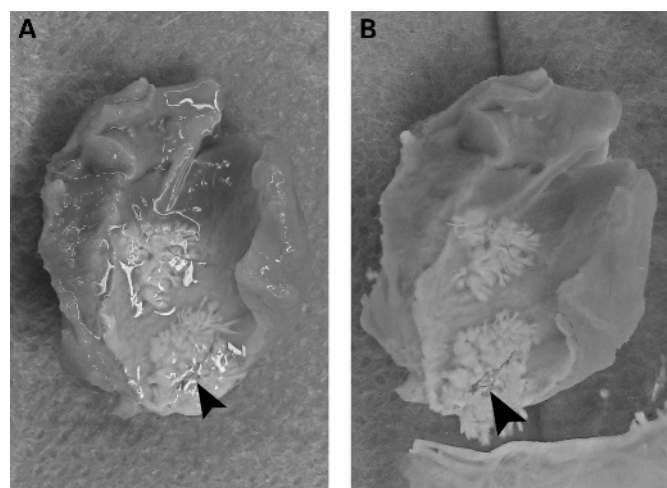
were small, but present on the rough zone of the valves as well as on the entire flow surface of each valve (fig 2). There were four myectomies; each showed patchy, shiny, white lesions (fig 3A). Details of the lesions were best demonstrated by immersing the specimens in water (fig 3B), where the fronds or sea anemone-like branches were clearly seen.

### HISTOLOGY

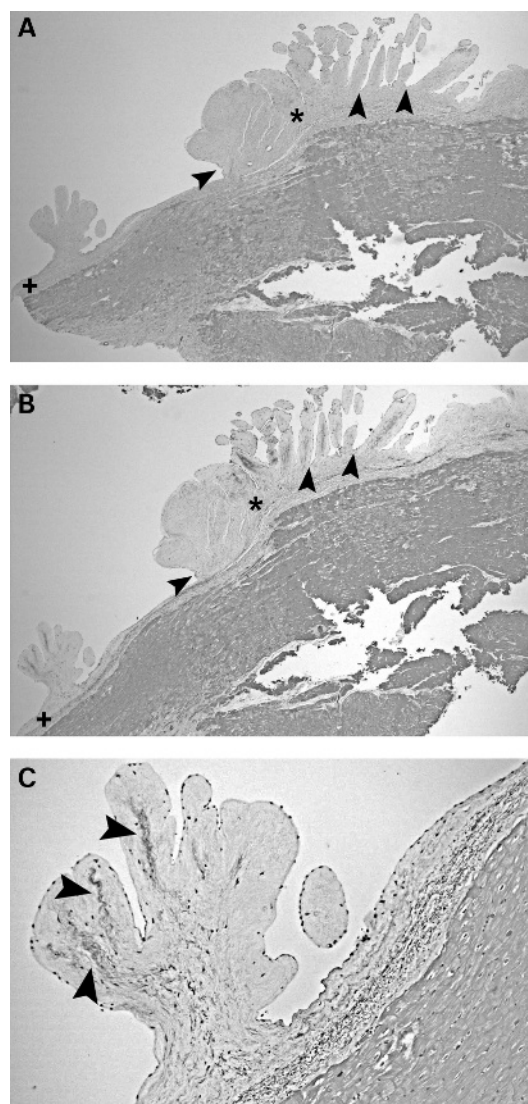
Histologically, the lesion was comprised of several narrow bases with frond-like branches attached to them (fig 4). These frond-like lesions were predominantly comprised of a mucopolysaccharide-rich matrix (fig 5) with some collagen and varying amounts of elastic tissue (fig 6). The appearance is that of a papillary fibroelastoma, which instead of being a single lesion is “carpet-like” and at multiple sites. We therefore have a multifocal PFE.

### DISCUSSION

PFEs are benign tumours that have an incidence of 0.001–0.030%.<sup>1</sup> Surgically excised valves are often not sectioned, therefore the actual incidence of PFEs, especially small lesions, may not be accurately recognised. Most cases that are identified are larger lesions discovered incidentally or by echocardiography.<sup>3</sup> There has been controversy concerning classification of



**Figure 3** (A, B) One myectomy specimen showing the small linear thrombus (arrow), despite anticoagulation, noticed by the surgeon within one area of the papillary fibroelastoma on the septal cardiac muscle. (B) Lesions on the cardiac muscle immersed in water showing the typical appearance of the papillary fibroelastoma.



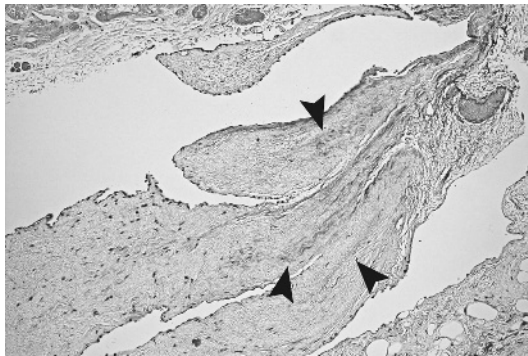
**Figure 4** (A–C) The endocardium (+) shows two lesions; one large (\*) and the other smaller. Both are similar in structure with a short stem (arrows) and several fronds arising from each stem (or “tree trunk”) (stain: (A) H&E, original magnification  $\times 2.5$ ; (B) Movat pentachrome, original magnification  $\times 2.5$ ). (C) The small lesion is shown with a largely myxoid core, with minimal collagen, and elastic tissue (black areas) present (arrows) (stain: Movat pentachrome, original magnification  $\times 10.0$ ).

PFEs as tumours. Some studies have suggested the possibility that they are congenital malformations, or the result of an inflammatory reaction. However today, PFEs are accepted to be true neoplasms.<sup>8</sup> PFEs are found predominantly in men, with a mean age at detection from the review of literature of 56 years (table 1), compared to the published mean age at detection of 60 years.<sup>7</sup> Our case involved a 25-year-old man, an age of incidence which is extremely rare for this type of lesion. In our case, fragments of the tumour, or possibly a thrombus which formed on it, may have embolised and led to the cerebrovascular accidents.

### Review of the literature

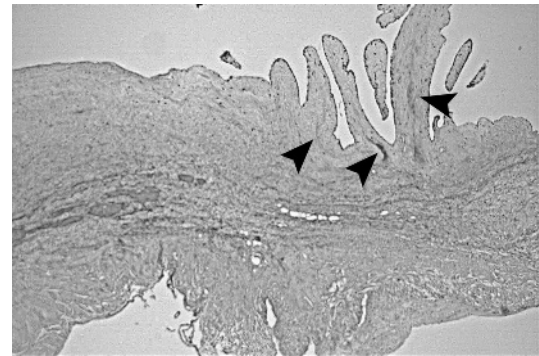
A review of the English language literature was performed using PubMed (US National Library of Medicine) to identify previously published cases of PFEs between 1997 and 2008.

## Review



**Figure 5** Section of a mitral valve showing multiple frond-like structures on the flow surface (arrows). Each has a mucopolysaccharide stroma and the large one has the beginnings of elastic tissue in its core. Very little collagen is noted (stain: Movat pentachrome, original magnification  $\times 5.0$ ).

The following search terms were used: primary cardiac tumours, papillary fibroelastoma, multiple papillary fibroelastomas, cardiac valve tumours, Lambl's excrescences, and myxoma (table 1). The literature reviewed ranged between 1997 and 2008. Of the 833 cases reviewed, 58% were male and 42% female with a mean age at detection of 56 years. Tumour size ranged from 2 to 70 mm, although at our institution we have yet to see a PFE with a size close to 70 mm. The two most common locations of PFEs were the aortic valve with a 44–52% occurrence, and the mitral valve with a 35–40% occurrence. Clinical presentations varied, but TIA, dyspnoea, chest pain and symptoms that could be likened to syncope were reported in the majority of cases. Ninety-eight per cent of the reviewed cases had been studied by TEE and TTE, 1% by TEE alone, and 1% by either TTE alone or other imaging modalities such as CT scan or MRI. In our case, a CT scan of the chest did not show any mass



**Figure 6** A large tumour arising from the endocardium showing a fibrovascular core (asterisk) and an elastin rich core in each frond (arrow) (stain: Movat pentachrome, original magnification  $\times 10.0$ ).

lesions in the heart (including the valves and endocardium). Excision was the most common form of management in 79% of reviewed cases, excision and valve repair were performed in 11% of cases, and excision and valve replacement were performed in 10% of cases.

### PFE appearance

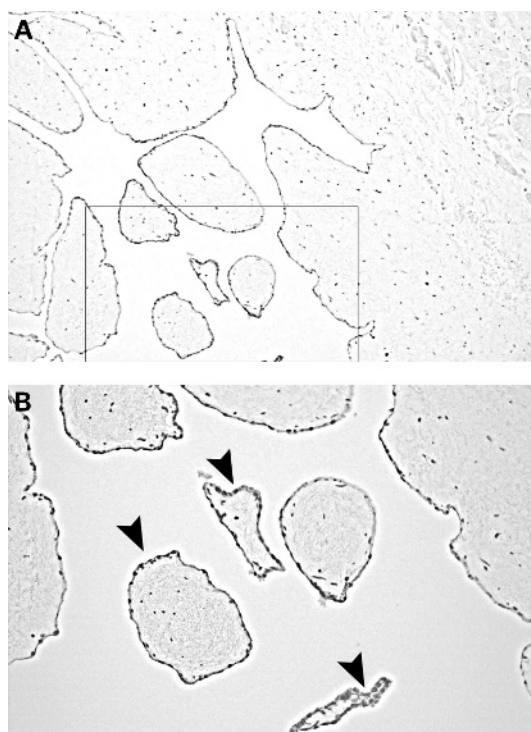
PFEs usually appear as highly mobile spherical masses with a maximum diameter of 10 mm.<sup>3</sup> The lesions are generally solitary with an opalescent white appearance and numerous frond-like branches attached to the valve surface by a single stalk.<sup>4</sup> They have been reported as having the appearance of a sea anemone when immersed in water, with multiple papillary fronds easily seen arising from the central stalk<sup>1 5</sup> (fig 3). These fronds are covered by endothelial cells (fig 7) and have a loose mucopolysaccharide-rich tissue layer on a connective tissue core.<sup>2</sup> Elastic fibres are also present within the central core.<sup>4 6</sup>

**Table 1** Previously reported cases of papillary fibroelastoma

Reference	Cases	Sex	Mean age	Size (mm)	Location	Clinical presentation	Tests	Management
*Gowda <i>et al</i> (2003) <sup>13</sup>	725	56% M 45% F	70	2.0–70.0	44% AV 35% MV	32% TIA/stroke 13% Angina	TEE, TTE	81% Excision 10% Excision, VRT
Ngaage <i>et al</i> (2005) <sup>14</sup>	88	71% M 29% F	62	–	52% AV 18% LVOT	52% Dyspnoea 32% Thromboembolism	TEE, TTE	83% Excision 9% Excision, repair
Boodhwani <i>et al</i> (2007) <sup>15</sup>	10	70% M 30% F	54	2.0–27.0	50% AV 40% MV	30% TIA 20% Stroke	TEE	40% MVR 30% AVRT
Butany <i>et al</i> (1997–2008) <sup>2 16 17</sup>	3	M M F	51	9.0–15.0	AV IVS IAS	Vertigo, hypertension, history of tight chest Chest trauma, heart failure symptoms, dyspnoea Respiratory and renal failure	TTE, TEE TTE Chest x ray, TTE	Excision, repair Orthotopic heart transplantation Excision, repair
Saw <i>et al</i> (2001) <sup>18</sup>	3	M F	45	6.0–7.0	MV MV IVS	Abdominal pain, weakness Fronto-parietal infarct, dysphasia VSD	MRI, Echo TTE Echo	Excision, repair Excision, repair Excision, repair
Hino <i>et al</i> (2007) <sup>19</sup>	2	M F	57	7.0–9.0	LVOT LV: papillary muscles	Routine check-up Dyspnoea	Echo Echo	Excision AVRT, MVRT, tricuspid annuloplasty
Darvishian <i>et al</i> (2001) <sup>20</sup>	2	M F	50	10.0–15.0	MV MV	Ataxia, nausea, vomiting, vertigo Dysphasia, vertigo, unsteady gait	CT scan, TTE CT scan, echo	Open-heart mitral valvuloplasty Open-heart mitral valvuloplasty

\*Gowda *et al*<sup>13</sup> performed a systematic search of the literature using Medline; they extracted data from case reports and case series to provide a comprehensive overview of the subject.

AV, aortic valve; AVRT, aortic valve replacement; CT, computed tomography; Echo, echocardiogram; IAS, interatrial septum; IVS, interventricular septum; LV, left ventricle; LVOT, left ventricular outflow tract; MRI, medical resonance imaging; MV, mitral valve; MVR, mitral valve repair; MVRT, mitral valve replacement; TEE, transoesophageal echocardiogram; TIA, transient ischaemic attack; TTE, transthoracic echocardiogram; VRT, valve replacement; VSD, ventricular septal defect.



**Figure 7** (A) Sections of the tumour show papillary fronds (stain: CD31, original magnification  $\times 5.0$ ). (B) Higher magnification boxed area from (A). All fronds are covered with a single layer of endothelial cells (stain: CD31, original magnification  $\times 20.0$ ).

### Differential diagnosis

PFEs and Lambl's excrescences are histologically very similar, although PFEs are larger and more gelatinous than Lambl's excrescences which are usually thread-like in structure<sup>7</sup> (table 2). PFEs tend to be located on various parts of the cusps, whereas Lambl's excrescences are generally seen on the midline of the

closing valves margins. Furthermore, PFEs have a central stalk, a layer of elastic tissue and are not filiform like Lambl's excrescences. PFEs and myxomas are also histologically somewhat similar, although PFEs lack identifiable vessels within the papillae and polygonal cells within the papillae and on the surface of the tumour (table 2). PFEs also have an outer localisation of myxoid matrix and laminated elastic fibres. It is essential to see the elastic tissue to differentiate a PFE from a Lambl's excrescences or myxoma.<sup>7</sup> This appearance is essentially the one seen in our case, which allowed for confirmation of PFE.

### Origin of PFE

The origin of PFE is still under debate, however they are often associated with iatrogenic procedures including radiation therapy or prior cardiac surgery involving native valve repair.<sup>9</sup> At our institution, we have yet to see a case of a PFE on a previously operated native heart valve. Risk factors associated with the development of PFEs remain unclear, however age, thoracic irradiation, cardiac valve disease, congenital heart defect repair and open-heart surgery have been proposed. There is often a prior known episode of rheumatic heart disease.<sup>4</sup> Our patient had none of the previously mentioned risk factors or possible explanations for his tumour.

Recently, there have been reports of PFEs being associated with several embolic states, including cerebrovascular events, myocardial infarction, and pulmonary embolism.<sup>10</sup> Fowles *et al*<sup>11</sup> found that 34% of patients with a PFE detected at echocardiography presented with TIA/CVA symptoms and a further 2% presented with symptoms of a pulmonary embolism.<sup>11</sup> Emboli often arise from papillary fronds of the tumour or from thrombi that form "in" or around the tumour.<sup>11</sup> Broken and embolised fronds can be responsible for angina, myocardial infarction, TIAs, stroke, or cardiac death.<sup>12</sup> Our patient had three previous CVAs, a MCA occlusion, and known pulmonary emboli. The strokes and emboli have both been posited to have had an association with the PFE lesion.

**Table 2** Differential diagnosis for papillary fibroelastoma

Cardiac tumour	Gross findings	Histological findings	Ultrastructural findings	Common location (cardiac)
Papillary fibroelastoma	<ul style="list-style-type: none"> <li>Spherical</li> <li>Typically solitary</li> <li>Opalescent</li> <li>White</li> <li>Gelatinous</li> <li>Numerous frond-like branches attached by single stalk</li> <li>Appearance of sea anemone when immersed in water</li> </ul>	<ul style="list-style-type: none"> <li>Papillary fronds: narrow, elongated, branched</li> <li>Matrix: mucopolysaccharides, elastic fibres, rare spindle cells</li> <li>Covered by layer of endothelial cells</li> </ul>	<ul style="list-style-type: none"> <li>Connective tissue: mature collagen, irregular longitudinal-oriented elastic fibres</li> <li>Matrix: fibroblasts, mesenchymal cells</li> <li>Surface endothelial cells: hyperplastic, numerous organelles and pinocytotic vesicles</li> </ul>	<ul style="list-style-type: none"> <li>AV</li> <li>MV</li> <li>TV</li> </ul>
Lambl's excrescences	<ul style="list-style-type: none"> <li>Smaller than PFE</li> <li>Thread-like</li> <li>Seen on midline of closing valve margins</li> <li>Filiform</li> <li>No central stalk</li> </ul>	<ul style="list-style-type: none"> <li>Finger-like projection extending from valve surface</li> <li>No branching</li> <li>No elastic fibres</li> </ul>	<ul style="list-style-type: none"> <li>Connective tissue: abundant collagen fibrils<sup>21</sup></li> <li>Circular zone devoid of identifiable connective tissue present at centre<sup>21</sup></li> </ul>	<ul style="list-style-type: none"> <li>AV</li> <li>MV</li> <li>TV</li> </ul>
Myxoma	<ul style="list-style-type: none"> <li>Attached to interatrial septum by either broad base of narrow pedicle</li> <li>Vary from gelatinous with frond-like excrescences to a smooth, firm mass</li> <li>Organised thrombi on surface</li> <li>May contain gritty calcified areas</li> </ul>	<ul style="list-style-type: none"> <li>Oval nucleus with open chromatin pattern and inconspicuous nucleoli</li> <li>Abundant eosinophilic cytoplasm</li> <li>Indistinct cell borders</li> <li>Ring surrounding blood vessel, often infiltrated by mononuclear inflammatory cells</li> <li>No elastic fibres</li> </ul>	<ul style="list-style-type: none"> <li>Mesenchymal cells with intermediate filaments and cytoplasmic organelles</li> <li>Vessels within papillae</li> <li>Polygonal "myxoma" cells within papillae and on surface of tumour</li> <li>Diffuse localisation of myxoid matrix</li> </ul>	<ul style="list-style-type: none"> <li>LA (attached to fossa ovalis)</li> <li>RA</li> </ul>

Modified from Burke *et al*.<sup>7</sup>

AV, aortic valve; LA, left atrium; MV, mitral valve; RA, right atrium; TV, tricuspid valve.

## Review

## Take-home messages

- ▶ Papillary fibroelastomas (PFEs) are the second most common type of benign tumour of the heart.
- ▶ Typically arising from diseased aortic or mitral valves on the left side of the heart, PFEs have a predilection for men around 56 years of age.
- ▶ Risk factors include age, thoracic irradiation, cardiac valve disease, congenital heart defect repair and previous open-heart surgery.
- ▶ Emboli often arise from papillary fronds of the tumour or from thrombi and can break, resulting in angina, myocardial infarction, transient ischaemic attacks, stroke, or cardiac death.

An interesting phenomenon is what we call an “aborted” PFE, where a structure with the histology of a PFE’s fronds is “trapped” inside a fibrotic area, generally in the central part of an aortic valve cusp. We believe that thrombus forms around the small PFE, encasing it, “aborting” it, and prohibiting further growth. These lesions appear to be “young”, not excessively collagenised, and with no inflammation or evidence of prior trauma.

The aetiology of the “carpet-like” appearance of the PFE lesion is not well understood. It is thought by some to be injury related, similar to current thinking concerning lesions arising on chordae tendinae or on papillary muscles. Endocardial fibrosis could look grossly like a PFE, but would certainly not be papillary or occur on the flow and non-flow surfaces of valves. Being a neoplasm, it could have grown until it involved the myocardium, and then become multifocal with further lesions on the aortic and mitral valves. Perhaps like any neoplasm the aetiology is and will remain unknown.

## CONCLUSION

In summary, we present the case of a 25-year-old man with multiple lesions on the aortic and mitral valves and a confluent “carpet-like” lesion in the left side of his heart clinically suspicious of a thrombus or myxoma. Surgery revealed masses on the aortic and mitral valves necessitating aortic and mitral valve replacement, and a multifocal “carpet-like” lesion covering many parts of the left ventricular endocardium. We believe that this case is the first reported instance of surgically resected and morphologically confirmed multiple PFE ever seen and removed at one operation.

**Competing interests:** None.

**Patient consent:** Obtained.

**Provenance and peer review:** Not commissioned; not externally peer reviewed.

## REFERENCES

1. Butany J, Nair V, Naseemuddin A, *et al*. Cardiac tumours: diagnosis and management. *Lancet Oncol* 2005;**6**:219–28.
2. Butany J, Nair V, Ahluwalia MS, *et al*. Papillary fibroelastoma of the interatrial septum. *J Card Surg* 2004;**19**:349–53.
3. Yamauchi S, Ogasawara H, Suzuki S, *et al*. A case report of a papillary fibroelastomas arising from the left ventricular outflow septum just beneath the aortic valve. *J Nippon Med Sch* 2008;**75**:239–41.
4. Ahuja JR, Amankar GP, Deshpanda J. Papillary fibroelastomas of the heart. *Indian J Pathol Microbiol* 2008;**51**:569–60.
5. Maraj S, Pressmale GS, Figueredo VM. Review: primary cardiac tumours. *Int J Cardiol* 2009;**133**:152–6.
6. Kuwashiro T, Toyoda K, Otsubo R, *et al*. Cardiac papillary fibroelastomas as a cause of embolic stroke: ultrasound and histopathological characteristics. *Intern Med* 2009;**48**:77–80.
7. Burke A, Virmani R. Tumours of the heart and great vessels. In: Rosai J, ed. *Atlas of tumour pathology*. Washington, DC: Armed Forces Institute of Pathology, 1996:47–52.
8. Boone SA, Campagna M, Walley VM. Lambi’s excrescences and papillary fibroelastomas: are they different? *Can J Cardiol* 1992;**8**:372–6.
9. Kurup AN, Tazelaar HD, Edwards WD, *et al*. Iatrogenic cardiac papillary fibroelastomas: a study of 12 cases (1990 to 2000). *Hum Pathol* 2002;**33**:1165–9.
10. Howard RA, Aldea GS, Shapira OM, *et al*. Papillary fibroelastomas: increasing recognition of a surgical disease. *Ann Thorac Surg* 1999;**68**:1881–5.
11. Fowles RF, Miller DC, Egbert BM, *et al*. Systemic embolization from a mitral valve papillary endocardial fibroma detected by two-dimensional echocardiography. *Am Heart J* 1981;**102**:128–30.
12. Georgiou GP, Erez E, Vidne BA, *et al*. Case report: tricuspid valve papillary fibroelastomas: an unusual cause of intermittent dyspnea. *Eur J Cardiothorac Surg* 2003;**23**:429–31.
13. Gowda RM, Khan IA, Nair CK, *et al*. Cardiac papillary fibroelastomas: a comprehensive analysis of 725 cases. *Am Heart J* 2003;**146**:404–10.
14. Ngaage DL, Mullany CJ, Daly RC, *et al*. Surgical treatment of cardiac papillary fibroelastomas: a single center experience with eighty-eight patients. *Ann Thorac Surg* 2005;**80**:1712–8.
15. Boodhwani M, Veinot J, Hendry PJ. Surgical approach to cardiac papillary fibroelastomas. *Can J Cardiol* 2007;**23**:301–2.
16. Evans AJ, Butany J, Omran AS, *et al*. Incidental detection of an aortic valve papillary fibroelastomas by echocardiography in an asymptomatic patient presenting with hypertension. *Can J Cardiol* 1997;**13**:905–8.
17. Soor GS, Chakrabarti MO, Siddiqui RF, *et al*. Hypertrophic cardiomyopathy presenting as restrictive cardiomyopathy: a case complicated by biventricular apical aneurysms and papillary fibroelastoma. Published Online First: 26 May 2008. doi:10.1016/j.carpath.2008.03.007.
18. Saw W, Nicholls S, Trim G, *et al*. Papillary fibroelastoma, a rare but potentially treatable cause of embolic stroke: report of three cases. *Heart Lung Circ* 2001;**10**:105–7.
19. Hino H, Miyairi T, Kitamura T, *et al*. Papillary fibroelastoma of the left ventricle: report of two cases. *Asian Cardiovasc Thorac Ann* 2007;**15**:e72–4.
20. Darvishian F, Farmer P. Papillary fibroelastoma of the heart: report of two cases and review of the literature. *Ann Clin Lab Sci* 2001;**31**:291–6.
21. Hurle JM, Garcia-Martinez V, Sanchez-Quintana D. Morphologic characteristics and structure of surface excrescences (Lambi’s excrescences) in the normal aortic valve. *Am J Cardiol* 1986;**58**:1223–7.



## Multifocal "tapete" papillary fibroelastoma

K B Law, K R B Phillips, R J Cusimano and J Butany

*J Clin Pathol* 2009 62: 1066-1070  
doi: 10.1136/jcp.2009.070243

---

Updated information and services can be found at:  
<http://jcp.bmj.com/content/62/12/1066>

---

*These include:*

### References

This article cites 19 articles, 3 of which you can access for free at:  
<http://jcp.bmj.com/content/62/12/1066#BIBL>

### Email alerting service

Receive free email alerts when new articles cite this article. Sign up in the box at the top right corner of the online article.

---

### Notes

---

To request permissions go to:  
<http://group.bmj.com/group/rights-licensing/permissions>

To order reprints go to:  
<http://journals.bmj.com/cgi/reprintform>

To subscribe to BMJ go to:  
<http://group.bmj.com/subscribe/>