

Ischemic Perinatal Stroke Secondary to Chorioamnionitis: A Histopathological Case Presentation

Christine C. Dueck, MD, David Grynspan, MD,
David D. Eisenstat, MD, MA, FRCPC, Rebecca Caces, MD, and
Mubeen F. Rafay, MBBS, FCPS, MSc

Ischemic perinatal stroke is a serious potential complication of delivery. In utero infection may be responsible for an underestimated proportion of perinatal stroke. Limited literature identifies objective evidence of ischemic perinatal stroke as a consequence of uterine infection. The authors report a neonate with ischemic stroke and documented findings of severe chorioamnionitis with umbilical vein thrombosis. A term neonate, after uneventful pregnancy and delivery, presented on the third day of life with seizures. Investigations for metabolic, electrolyte, infectious, and hypercoagulability derangements were normal. Extensive acute infarction in the left middle cerebral artery territory

was diagnosed by magnetic resonance imaging (MRI). Placental histopathology confirmed the presence of chorioamnionitis. On follow-up assessments, mild residual neurologic deficits have persisted. Chorioamnionitis has been correlated with ischemic perinatal stroke. In addition to the recognized inflammatory cascade of in utero infection, umbilical vein thrombosis with subsequent "paradoxical" embolization may represent one mechanism responsible for this association.

Keywords: stroke; cerebrovascular disorders; brain ischemia; cerebral infarction; placental pathology; perinatology

Ischemic perinatal stroke typically occurs beyond 20 weeks' gestational age and within 28 days of life. The estimated incidence of ischemic perinatal stroke ranges from 1 in 2300 to 5000 live births.^{1,2} Acute ischemic perinatal stroke presents with the clinical findings typical of neurologic damage such as seizures, alteration in consciousness, and focal neurologic deficits, and evidence of acute ischemic infarction on neuroimaging. However, the effects of perinatal stroke may manifest later in childhood, with evidence of old infarction on neuroimaging.³

Received November 14, 2008. Received revised February 8, 2009. Accepted for publication February 9, 2009.

From the Departments of Pediatrics and Child Health (CCD, DDE, RC, MFR) and Pathology (DG), Section of Hematology and Oncology (DDE), Section of Neonatology (RC), and Section of Neurology (MFR), University of Manitoba, Health Sciences Centre, Winnipeg, Manitoba, Canada.

The authors have no conflicts of interest to disclose with regard to this article. The research in pediatric stroke of MFR is supported by a grant from Manitoba Institute of Child Health.

Address correspondence to: Mubeen Rafay, Section of Neurology, Department of Pediatrics, University of Manitoba, AE307-840 Sherbrook Street, Winnipeg, Manitoba, Canada R3A 1S1; e-mail: MRafay@exchange.hsc.mb.ca.

Dueck CC, Grynspan D, Eisenstat DD, et al. Ischemic perinatal stroke secondary to chorioamnionitis: a histopathological case presentation. *J Child Neurol*. 2009;24:1557-1560.

Multiple etiologies or pathogenesis underlie ischemic stroke in neonates. Cardiogenic and intra-arterial thromboemboli and infections are commonly known etiologic factors for perinatal stroke.³ In about 30% of cases, no cause is ever identified.³ As a focus of low blood flow, the placenta is often implicated in the pathogenesis of ischemic perinatal stroke, given its predilection for stasis and thrombus formation.³ Thrombi associated with a variety of pathological placental lesions have been described with adverse neurologic birth outcomes. These lesions include vascular necrosis, hypoperfusion, chronic villitis, and, most commonly, chorioamnionitis, rates of which are as high as 10% to 15% of all live births.⁴ Retrospective analyses of infants suffering perinatal stroke document these changes only in preterm infants. Limited literature supports direct correlation of placental infections with ischemic perinatal stroke.⁵

Case Report

Shortly after birth, with delivery by vacuum extraction, a female infant born at 41 weeks' gestation to a 27-year-old gravida 2 nulliparous woman with a history of spontaneous abortion developed moderate tachypnea. Her examination at the time was significant only for a large, left-hand side cephalohematoma and mild peripheral

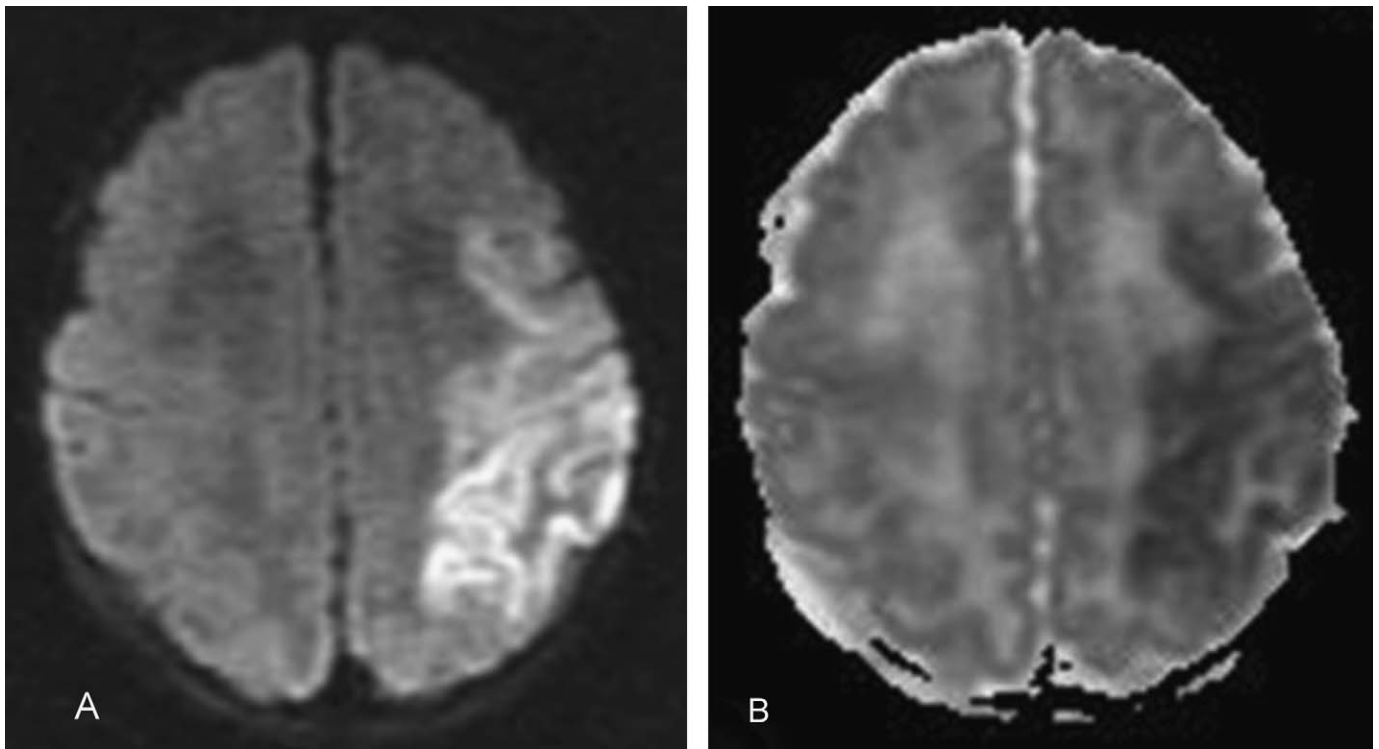


Figure 1. Magnetic resonance imaging (MRI) of the brain in the 3-day-old newborn with acute left middle cerebral artery territory stroke. Diffusion-weighted image (A) and corresponding apparent diffusion coefficient map (B) demonstrating restricted diffusion and decreased apparent diffusion coefficient values involving the left anterior parietal, posterior frontal lobes, the insular cortex, and the left ventrolateral thalamus, consistent with acute ischemic infarction involving the left middle cerebral artery territory.

hypotonia. A routine septic evaluation, including peripheral blood culture, chest radiograph, and complete blood count, was performed. The complete blood count and the chest radiograph were normal. Intravenous ampicillin and gentamicin were administered and subsequently discontinued after blood culture results were negative at 48 hours.

The patient was discharged to her mother and remained in the hospital. On the third day of life, she developed focal, right-hand side, tonic-clonic seizures with subsequent involvement of the contralateral side. She required loading with phenobarbital on which she was later maintained at a dose of 5 mg/kg per day. At that time, neurologic examination was significant only for right-hand side hyporeflexia, which resolved within the next 12 hours.

Lumbar puncture revealed cerebrospinal fluid protein 2.34 g/L, glucose 3.4 mmol/L, and total cells 17×10^6 /L. Repeat complete blood count was normal, as were values for glucose, urea, creatinine, bilirubin, electrolytes, calcium, and magnesium. A full urine and serum metabolic workup was normal.

Magnetic resonance imaging (MRI) performed within 24 hours of presentation revealed diffusion restriction, on diffusion-weighted sequences, involving the left anterior parietal, posterior frontal lobes, the insular cortex, and

left ventrolateral thalamus, suggestive of an acute ischemic infarction in the territory of the left middle cerebral artery (Figure 1). Electroencephalogram demonstrated bilateral central and temporal spikes, predominantly affecting the left hemisphere. Echocardiogram revealed the presence of a patent foramen ovale, with otherwise normal heart structure. The possibility of vena cava thrombosis, related to umbilical vessel catheterization, was eliminated with Doppler flow ultrasonography.

Detailed investigations for hypercoagulability (thrombin time, prothrombin time, prothrombin, antiphospholipid immunoglobulin G and immunoglobulin M antibodies, homocysteine, international normalized ratio, activated partial thromboplastin time, Clauss fibrinogen, antithrombin III assay, plasminogen, proteins C and S, free protein S-crossed immunoelectrophoresis, activated protein C resistance, lupus inhibitor, reptilase time, prothrombin gene mutations, and mutation analysis for factor V Leiden and 5,10-methylenetetrahydrofolate reductase) revealed no abnormalities.

The placenta was sent for histopathological examination, which revealed chorioamnionitis, while the examination of the umbilical cord revealed funisitis with vasculitis (Figure 2). Evidence of layered deposition of fibrin and

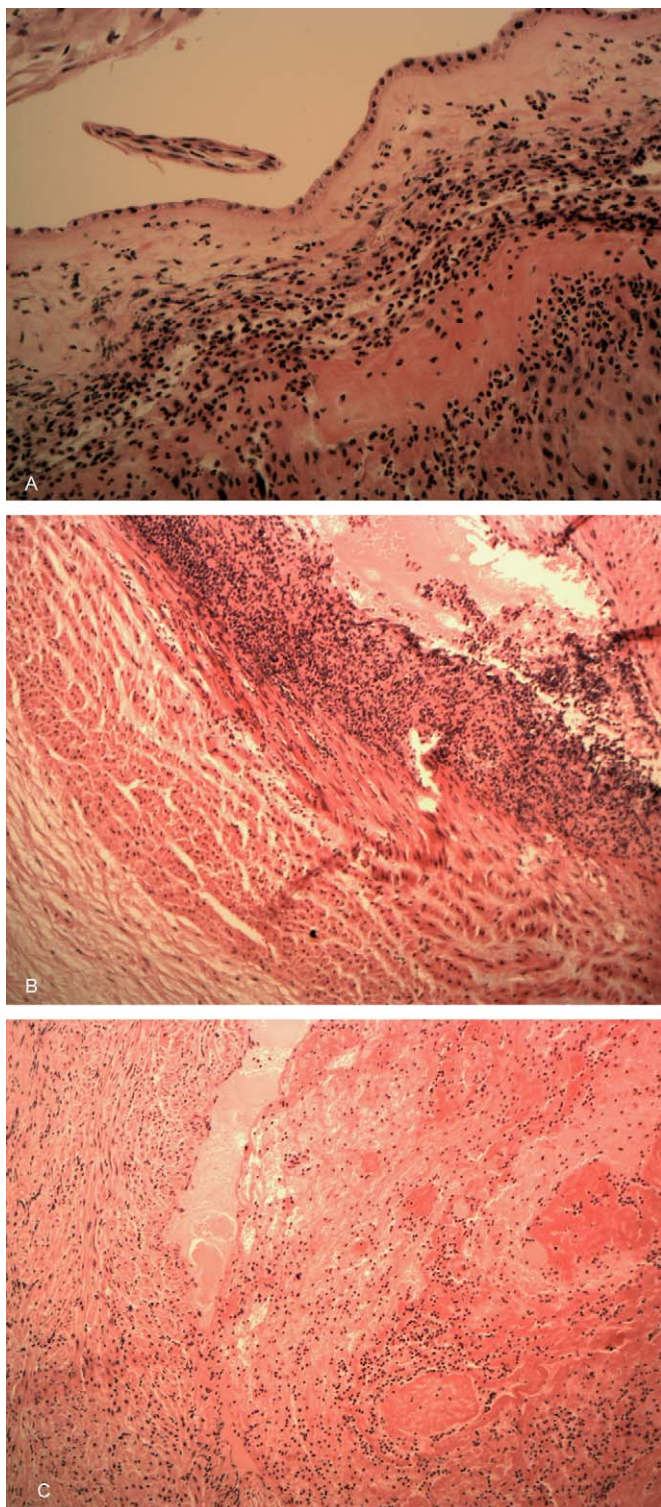


Figure 2. Histopathological sections of placenta in a 3-day-old newborn with acute stroke. A, Histological sections of the fetal membranes show neutrophilic infiltrate within the amnion and chorion. B, Sections of the placental vessels show severe endovasculitis and deposition of inflammatory material and fibrin within the umbilical vein. C, The inflammatory material shows layering of fibrin and red blood cells (lines of Zahn) confirming thrombosis of the umbilical vein.

inflammatory material (lines of Zahn) within the umbilical vein confirmed thrombosis within the vein. There was no sign of villitis and no abnormality of maternal or fetal vasculature.

On the eighth day of life, the infant was discharged from the hospital. At 9 months of age, there were mild residual deficits on neurologic follow-up, consisting of left-hand preference, increased tone in the right arm, and persistent fisting of the right hand, suggesting right arm monoparesis. Her leg movements were symmetric. She has had no further seizures and the phenobarbital was discontinued.

Discussion

This term infant with ischemic perinatal stroke presented during the immediate newborn period with lateralizing signs, including right-hand side seizures and right-hand side hyporeflexia. It should be noted that, unlike older children or adults, infants with ischemic stroke rarely demonstrate lateralizing signs, and focal deficits are present in fewer than 25% of cases.⁶ Typically infants with ischemic perinatal stroke manifest nonspecific signs of hypotonia, apneas, and, most commonly, lethargy and seizures, usually focal convulsions within the first day of life.^{3,5} Infants with delayed presentations remain apparently normal until several months of age, when motor impairment appears as new-onset seizures, pathological hand preference, or arrested progression of developmental milestones.

In neonates, some predisposition to vascular thrombosis lies in the unique features of neonatal physiology, namely prolonged clotting times and persistent fetal fibrinogen. Other factors conventionally identified in perinatal stroke include cardiac or hematological disease, infection, maternal disorders, placental disease, vasculopathy, trauma, asphyxia, and dehydration. Vacuum-assisted delivery has also been described as a risk factor, although cerebral infarction rarely follows a vacuum assist.³ Our child had no contributing features of a genetic thrombophilia; while not well understood in ischemic perinatal stroke, thrombophilias are known to favor placental thrombosis in areas of low pressure, where uterine spiral arteries perfuse the fetal villous vessels.³

Although chorioamnionitis is well described for its neurologic sequelae including cerebral palsy, in utero infection continues to be difficult to correlate directly with ischemic perinatal stroke. A recently published case report in a newborn with acute ischemic perinatal stroke demonstrates this association but the etiological mechanism was complicated by the presence of another underlying mechanism for his stroke.⁵ Similar to the infant presented here, their 1-day-old patient suffered an acute left middle cerebral artery territory stroke and had evidence of acute

chorioamnionitis with umbilical cord phlebitis and chorionic plate vasculitis on placental histopathology. However, he also had an abnormal echocardiogram with thick tricuspid leaflets and valvular thrombus, suggesting cardiac thromboembolism as another likely mechanism for his stroke.

In the absence of other risk factors, undiagnosed chorioamnionitis with clot embolization represents the most likely agent responsible for stroke in our case. Two potential mechanisms reasonably underlie this novel etiology of ischemic perinatal stroke. Infarction may reflect the procoagulable cytokine milieu of the infectious state. Alternatively, there may have been direct thromboembolism from placenta to the fetal brain. This is supported by evidence of organizing umbilical cord thrombosis, indicated by signs of umbilical vein funisitis and endovasculitis. Although no frank thrombus was found on histopathological examination, it should be noted that not all sections of cord are generally studied, which furnishes the possibility of clot in the remaining cord.

As many as 42% of placentas from unremarkable pregnancies demonstrate pathology, commonly including chorioamnionitis.⁴ Other studies examining placentas in perinatal stroke have reported infection but only in preterm neonates and without direct relationship to placental pathology.^{2,7} Given its low perfusion, the placenta is inherently suited to thrombus formation. Such favorability is enhanced in the presence of chorioamnionitis, which in itself creates a prothrombotic climate. The profound inflammatory response generated in the fetal membranes, umbilical cord, and, ultimately, in the fetus itself, is a purely local reaction that may extend to the umbilical cord, causing funisitis or vasculitis of the umbilical cord.⁴

The overall prognosis of infants experiencing ischemic perinatal stroke is variable. Many children do well, as many as one third of infants have normal long-term development,³ the success of which can be attributed to the plasticity of the infantile brain. Mortality after ischemic perinatal stroke ranges from 3% to 10%.⁸ The risk of recurrent stroke is low (1.8%) in most neonates in the absence of risk factors.⁹

The accepted management of ischemic perinatal stroke is limited.^{10,11} Progress on developing clinical guidelines for primary and secondary prevention of perinatal and pediatric arterial ischemic stroke faces substantial obstacles posed by ethical concerns and by a general lack of data. Consequently, a scant body of information exists to detail management of arterial ischemic stroke in

children, particularly in young infants.¹¹ Assessment of maternal risk factors, in particular placental examination, will provide valuable insights into the etiology of arterial ischemic stroke. Until more is known, avoidance of postnatal insults and aggressive seizure management are critical to prevent further ischemic brain injury.

References

1. Raju TN, Nelson KB, Ferriero D, Lynch JK, and the NICHD-NINDS Perinatal Stroke Workshop Participants. Ischemic perinatal stroke: summary of a workshop sponsored by the National Institute of Child Health and Human Development and the National Institute of Neurological Disorders and Stroke. *Pediatrics*. 2007;120(3):609-616.
2. Lee J, Croen LA, Backstrand KH, et al. Maternal and infant characteristics associated with perinatal arterial stroke in the infant. *JAMA*. 2005;293(6):723-729.
3. Nelson KB. Perinatal ischemic stroke. *Stroke*. 2007;38(2 suppl):742-745.
4. Redline RW, O'Riordan MA. Placental lesions associated with cerebral palsy and neurologic impairment following term birth. *Arch Pathol Lab Med*. 2000;124(12):1785-1791.
5. Redline RW, Sagar P, King ME, Krishnamoorthy KS, Grabowski EF, Roberts DJ. Case records of the Massachusetts General Hospital. Case 12-2008. A newborn infant with intermittent apnea and seizures. *N Engl J Med*. 2008;358(16):1713-1723.
6. Mercuri E, Cowan F. Cerebral infarction in the newborn infant: review of the literature and personal experience. *Eur J Paediatr Neurol*. 1999;3(6):255-263.
7. Benders MJ, Groenendaal F, Uiterwaal CS, et al. Maternal and infant characteristics associated with perinatal arterial stroke in the preterm infant. *Stroke*. 2007;38(6):1759-1765.
8. Murphy SL. Deaths: final data for 1998. *Natl Vital Stat Rep*. 2000;48(11):1-105.
9. Kurnik K, Kosch A, Strater R, Schobess R, Heller C, Nowak-Gottl U, and the Childhood Stroke Study Group. Recurrent thromboembolism in infants and children suffering from symptomatic neonatal arterial stroke: a prospective follow-up study. *Stroke*. 2003;34(12):2887-2892.
10. Monagle P, Chalmers E, Chan A, et al, and the American College of Chest Physicians. Antithrombotic therapy in neonates and children: American College of Chest Physicians Evidence-Based Clinical Practice Guidelines (8th Edition). *Chest* 2008;133(6 suppl):887S-968S.
11. DeVeber G, Kirkham F. Guidelines for the treatment and prevention of stroke in children. *Lancet Neurol*. 2008;7(11):983-985.

For reprints and permissions queries, please visit SAGE's Web site at <http://www.sagepub.com/journalsPermissions.nav>