

Solitary, Isolated Metastasis from Ewing's Sarcoma to the Brain: Case Report

Alessandro Olivi, M.D., Ross C. Donehower, M.D., Risa B. Mann, M.D., and
Henry Brem, M.D.

Departments of Neurological Surgery, Ophthalmology, Oncology, and Pathology, Johns Hopkins University School of
Medicine, Baltimore, Maryland

Olivi A, Donehower RC, Mann RB, Brem H. Solitary, isolated metastasis from Ewing's sarcoma to the brain: case report. *Surg Neurol* 1991;35:239-43.

We report a case of a 30-year-old woman who developed an intraparenchymal cerebral metastasis from a Ewing's sarcoma of the chest wall diagnosed and treated 3 years earlier and in apparent remission at the time of the neurological presentation (seizures). The case was complicated by a spontaneous preoperative intratumoral hemorrhage that occurred the morning of the scheduled surgical resection and caused a left dense hemiparesis. The tumor and the hematoma were removed. The patient improved after surgical intervention and a postoperative course of cranial irradiation followed by systemic chemotherapy was given. Nineteen months after treatment the patient remains disease-free from the clinical and radiological standpoint.

KEY WORDS: Ewing's sarcoma; Central nervous system metastases

Ewing's sarcoma is a rare neoplasm accounting for less than 10% of all primary malignant bone tumors. It is more frequently seen in children and young adults, with an incidence peak in the second decade of life. This tumor is known to disseminate widely, predominantly via the hematogenous route, and metastatic disease is often clinically manifest at the time of the initial diagnosis. Pulmonary and skeletal systems are the two most common sites of secondary spread [4,5].

Central nervous system (CNS) involvement has been reported [1-3,7,9], but usually as the result of a direct compression from an adjacent affected bone and epidural space. True metastasis to the nervous tissue is extremely rare and, almost invariably, is associated with detectable disseminated disease to other organs [4,6,9].

We present a case of a solitary, isolated, frontoparietal intracerebral metastasis from a Ewing's sarcoma of the rib, complicated by a spontaneous intraneoplastic hemorrhage.

Case Report

A 30-year-old white woman was admitted to the Johns Hopkins Hospital on January 11, 1989, after she suffered a single grand mal seizure.

In 1985 she was diagnosed as having Ewing's sarcoma of the posterior left sixth rib after presenting with chest wall pain. A chest computed tomography (CT) scan demonstrated a large 10 × 12-cm mass originating in the posterior left ribs and eroding into the thoracic vertebrae at T-4-T-6. Computed tomography-myelography revealed extension of the tumor into the epidural space at that level but no compression of the spinal cord. On radionuclide bone scan abnormal uptake was observed only in the ribs of the left side and vertebrae. Abdominal CT scan, head CT scan, and bilateral bone marrow aspirates and biopsy specimens were negative. The patient had a wide excision of the chest wall mass with clean margins on the inferior, superior, and lateral borders of the tumor. The extensive vertebral involvement precluded total removal of the tumor on the medial side.

The tumor was composed of a monotonous proliferation of small cells with scant cytoplasm (Figure 1 A). The nuclei were round to oval and, when present, nucleoli were small and inconspicuous (Figure 1 B). The cytoplasm contained abundant periodic acid-Schiff-positive, diastase-sensitive (glycogen) granules (Figure 1 C).

Immunoperoxidase studies demonstrated that the neoplastic cells were negative for neuron-specific enolase and common leukocyte antigen. Electron microscopy showed that the neoplastic cells contained abundant cytoplasmic glycogen with primitive cell junctions. There were no neurosecretory granules or evidence of muscle differentiation. These findings are consistent with the diagnosis of Ewing's sarcoma.

Address reprint requests to: Henry Brem, M.D., Department of Neurosurgery—Meyer 7-113, Johns Hopkins Hospital, 600 North Wolfe Street, Baltimore, Maryland 21205.

Received June 19, 1990; accepted August 27, 1990.

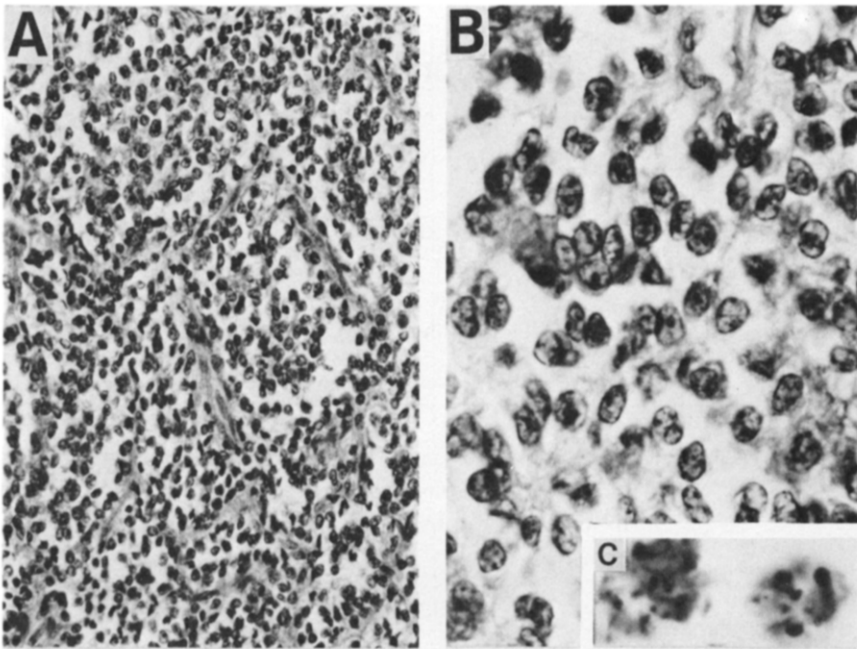


Figure 1. (A) Low-power photomicrograph of Ewing's sarcoma involving rib (hematoxylin and eosin stain $\times 200$). (B) High-power view showing monotonous small cell proliferation (hematoxylin and eosin stain $\times 700$). (C) Abundant glycogen within cytoplasm of neoplastic cells (periodic acid-Schiff stain $\times 700$).

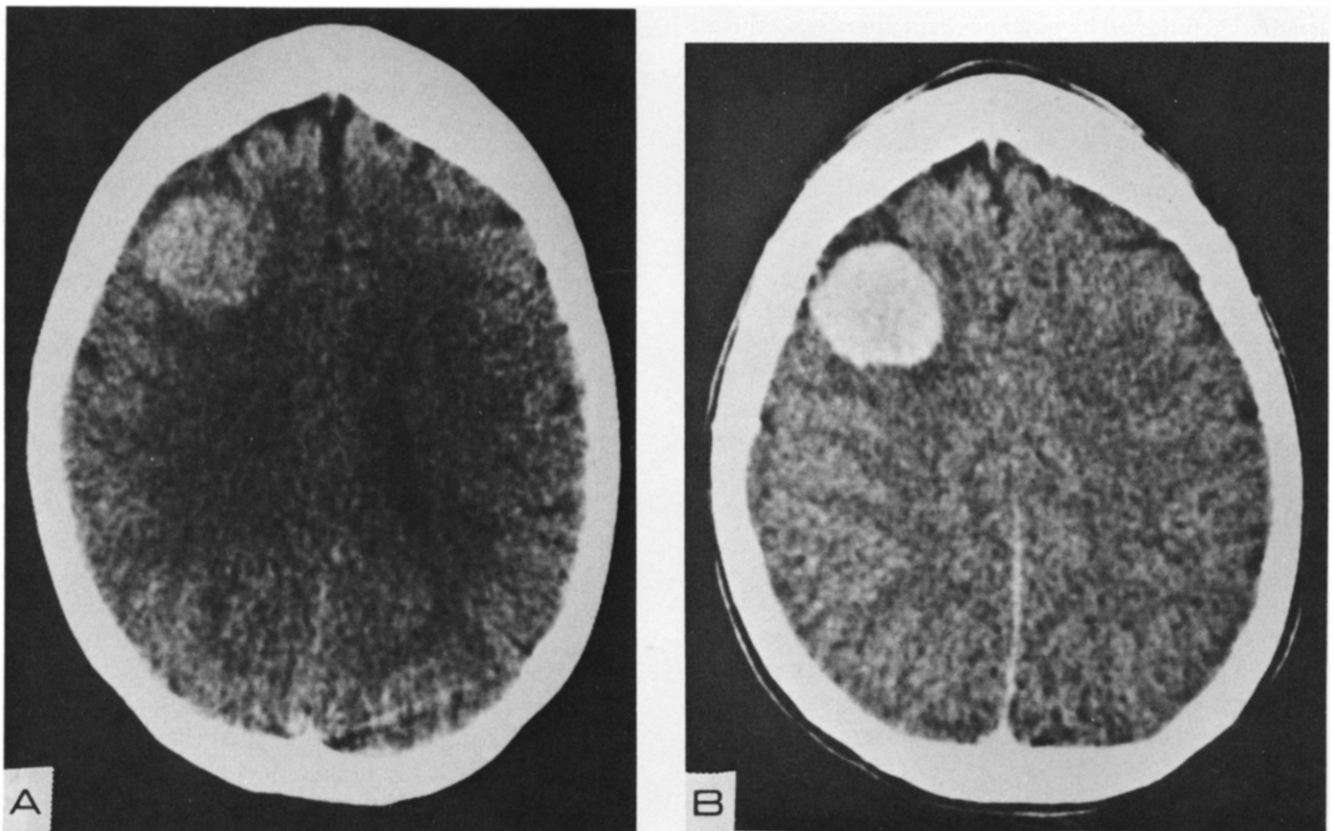


Figure 2. (A) Plain axial CT scan shows a slightly hyperdense mass in the right frontal lobe. (B) After injection of contrast medium, a discrete uniformly enhancing lesion is evident.

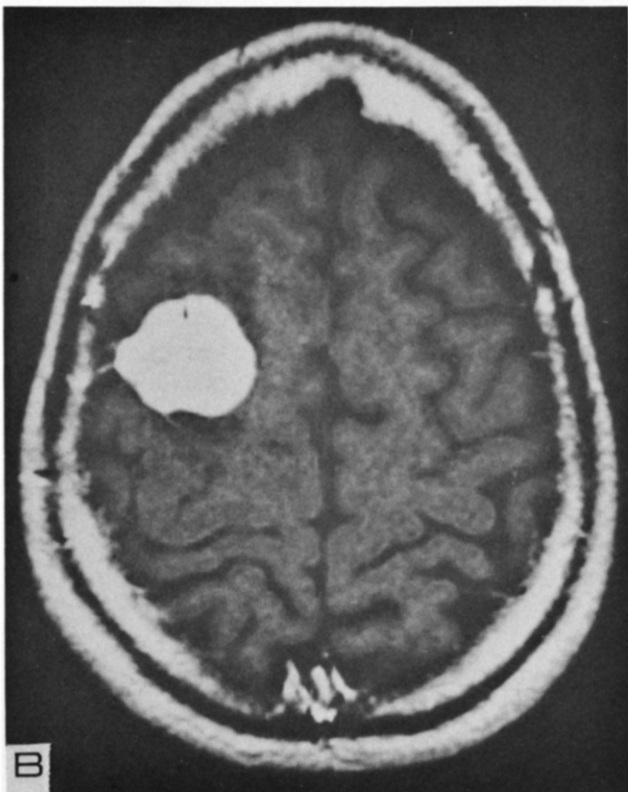
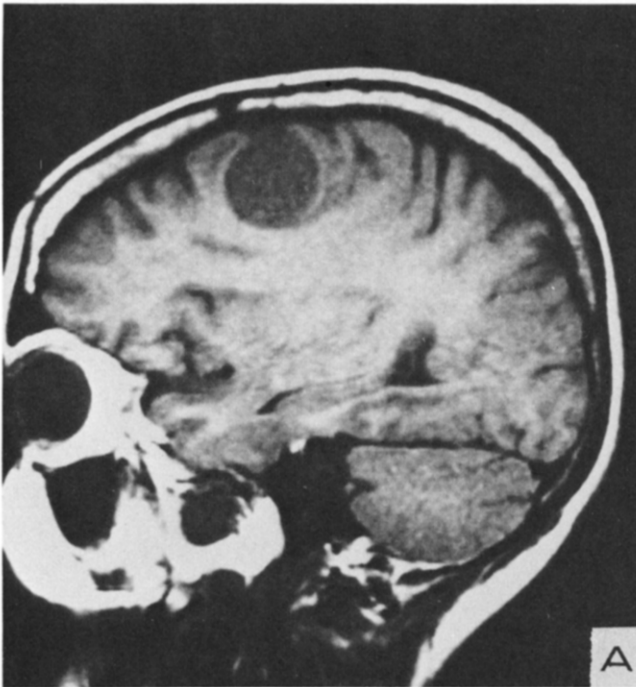


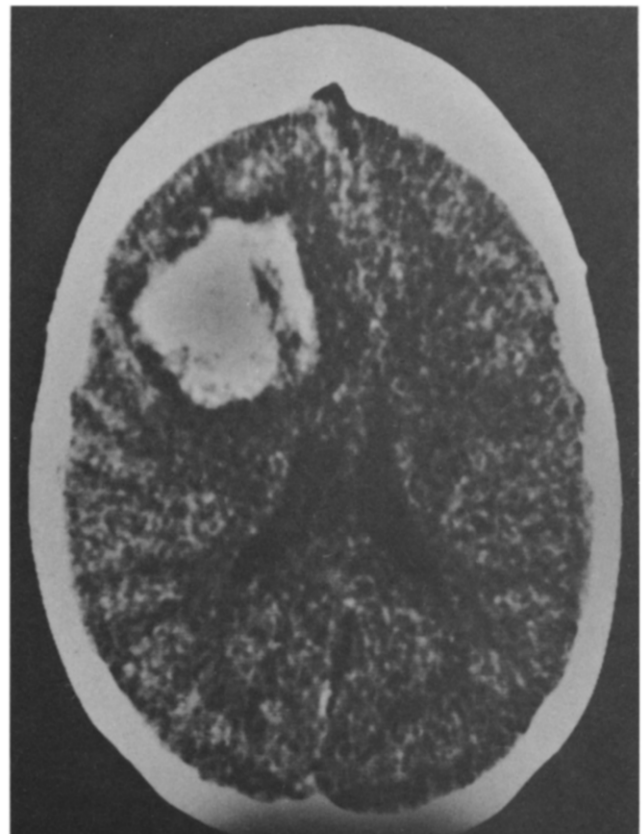
Figure 3. (A) Sagittal magnetic resonance image (T1-weighted image) through the lesion showing a well-demarcated hypointense mass just behind the coronal suture. (B) Axial magnetic resonance image performed after intravenous injection of gadolinium showing a sharply enhancing lesion.

Surgery was followed by five cycles of chemotherapy (cyclophosphamide 150 mg/m²/day p.o. × 7 days, doxorubicin 35 mg/m² on day 8) and radiotherapy to the left paratracheal region (4410 cGy) and the left posterior hemithorax (4470 cGy). Treatment was complicated by recurrent pancytopenias associated with chemotherapy, radiation pneumonitis, and *Pneumocystis carinii* pneumonia. Following completion of radiation therapy, the patient received 6 months of maintenance chemotherapy with cyclophosphamide, doxorubicin, and vincristine. She had been followed without any treatment since January 1987 and was believed to be free of recurrent disease on clinical and radiographic criteria.

At the time of her seizure in January 1989, she was neurologically intact. A CT scan of the head showed the presence of a discrete lesion in the right posterior frontal area, 3.5 cm in size, enhancing after the injection of intravenous contrast medium (Figure 2 A and B). A magnetic resonance image showed a spherical lesion posterior to the coronal suture, sharply enhancing after the injection of gadolinium (Figure 3 A and B).

No evidence of disease outside the CNS was detected based on a complete restaging of her disease.

Figure 4. Non-contrast-enhanced axial CT scan obtained the morning of the scheduled operation after an episode of seizure and deterioration of the mental status, showing a fresh intratumoral hemorrhage with increased mass effect.



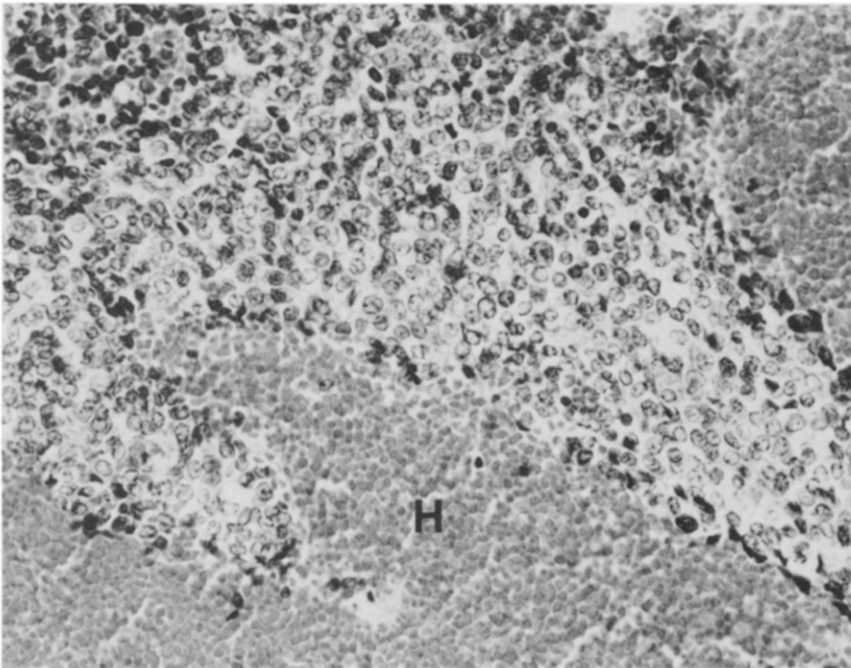


Figure 5. Photomicrograph of metastatic Ewing's sarcoma in brain with extensive hemorrhage (H) (hematoxylin and eosin stain $\times 200$).

The morning of the scheduled elective craniotomy for resection of the right frontal solitary mass the patient had a focal left-sided seizure followed by progressive left hemiparesis. A repeat CT scan was obtained and showed a large acute intratumoral hemorrhage with increased mass effect (Figure 4). The patient was taken to the operating room, where a right frontoparietal craniotomy was performed and the tumor, with the recent hemorrhage, was excised. While the borders of the neoplastic tissue were well defined and discrete, the hemorrhage was extending, through different planes, into the surrounding white matter. Gross total removal of a yellow fibrous tumor mixed with clot was obtained.

Microscopically, the tumor was similar to the patient's previous bone primary but contained abundant fresh blood (Figure 5). The neoplastic cells were negative for common leukocyte antigen, neuron-specific enolase, and glial fibrillary acid protein.

The postoperative course was uneventful and the patient recovered well from the general standpoint. The left-sided hemiparesis improved considerably during the following months to the point that she is able to walk independently and can take full care of herself. Following the surgical excision of the lesion, the patient underwent a course of radiation treatment to the brain (5500 rads) and an additional course of chemotherapy consisting of etoposide (100 mg/m^2 daily $\times 5$ days) and difosfamide (1.5 g/m^2 daily $\times 5$ days). Nineteen months after diagnosis the patient remains clinically and neuro-

logically stable with no radiological evidence of recurrent tumor.

Discussion

Early reports on involvement of the CNS in Ewing's sarcoma suggested a fairly high incidence of neurological symptoms in patients with this disease [2,3]. Marsa and Johnson [2] reported two cases of Ewing's sarcoma in which the patients developed signs of a leptomenigeal and cerebral recurrence after aggressive adjuvant chemotherapy. The authors concluded that prophylactic treatment with whole brain radiation and intrathecal chemotherapy should be given to patients with Ewing's sarcoma at the time of the initial diagnosis.

In another report before CT scanning was available, Mehta and Hendrickson [3] concurred with the necessity for CNS prophylaxis on the basis of the observation that 15 of the 27 patients of their series (55%) with Ewing's sarcoma developed one or more neurological symptoms. Unfortunately, in only a minority of patients was there histological proof of such involvement. In five patients autopsy confirmed some dural involvement, and in only one was there evidence of a true intraparenchymal parietal lobe metastasis.

Kies and Kennedy [1] reported on a series of 134 patients with Ewing's sarcoma and showed an incidence of 16% of suspected or proven CNS metastasis. Autopsy was obtained in 44 of 134 patients. Thirteen were found

to have CNS involvement, most frequently (9 of 13) as a result of a direct extension from skull and vertebral lesions. One patient had a primary dural involvement and only three discrete parenchymal brain metastases. On this basis, they questioned the need for routine CNS prophylaxis.

Trigg et al [9], in the largest and most recent report on this subject, reviewed the records of 455 patients with Ewing's sarcoma and concluded that CNS prophylaxis was not necessary. In their series only 10 patients (2.2%) developed intraparenchymal or meningeal CNS involvement without adjacent bone or epidural lesions. Moreover, four of these 10 patients were part of a larger group of patients who had undergone prophylactic treatment with CNS irradiation and intrathecal chemotherapy at the time of the initial diagnosis. Interestingly, their only patient with an intraparenchymal isolated metastasis suffered a spontaneous intratumoral hemorrhage.

Sonntag and Stein [7] reported the feasibility of operating successfully for a solitary intracerebral metastasis of Ewing's sarcoma. Recently, Simpson et al [6] reported on the surgical treatment of another case of a solitary Ewing's sarcoma metastasis to the left parietal lobe. That patient developed evidence of pulmonary recurrence 2 months after the craniotomy.

Two unusual aspects of our case are the spontaneous intracerebral hemorrhage that led to a successful emergency surgical resection and the absence, 19 months after the craniotomy, of evidence of local recurrence or disseminated disease.

Central nervous system involvement with Ewing's sarcoma remains a rare phenomenon so that prophylactic treatment may not be warranted. However, the possibility of metastatic disease to the brain should be consid-

ered in the follow-up of long-term survivors from Ewing's sarcoma, particularly in view of the prominent vascularity of this tumor and its tendency, as in our case, to hemorrhage.

We acknowledge the support of the National Institutes of Health Grant No. NS01058 (H.B.), the Mellon Foundation Grant to Johns Hopkins University for Faculty Support (H.B.), and the Dana Foundation (A.O.).

References

1. Kies MS, Kennedy PS. Central nervous system involvement in Ewing's sarcoma. *Ann Intern Med* 1978;89:226-7.
2. Marsa GW, Johnson RE. Altered pattern of metastasis following treatment of Ewing's sarcoma with radiotherapy and adjuvant chemotherapy. *Cancer* 1971;27:1051-4.
3. Mehta Y, Hendrickson FR. CNS involvement in Ewing's sarcoma. *Cancer* 1974;33:859-62.
4. Pilepich MV, Vietti TJ, Nesbit ME, Tefft M, Kissane J, Burgert EO, Pritchard D. Radiotherapy and combination chemotherapy in advanced Ewing's sarcoma—intergroup study. *Cancer* 1981;7:1930-6.
5. Pizzo PA, Cassady JR, Misser JS, Filler RM. Solid tumors in childhood. In: De Vita VT, Hellman S, Rosenberg SA, eds. *Cancer: principles and practice of oncology*. Philadelphia: JB Lippincott Co, 1985:1564-71.
6. Simpson RK Jr, Bruner JM, Leavens ME. Metastatic Ewing's sarcoma to the brain: case report and review of treatment. *Surg Neurol* 1989;31:234-8.
7. Sonntag VKH, Stein BM. Intracerebral Ewing's sarcoma: case report. *Neurosurgery* 1978;2:55-7.
8. Steinbok P, Flodmark O, Norman MG, Chan KW, Fryer CJH. Primary Ewing's sarcoma of the base of the skull. *Neurosurgery* 1986;19:104-7.
9. Trigg ME, Glaubiger D, Nesbit ME. The frequency of isolated CNS involvement in Ewing's sarcoma. *Cancer* 1982;49:2404-9.