

A psychiatric presentation of abulia – three cases of left frontal lobe ischaemia and atrophy

H Förstl MD *Central Institute of Mental Health, Mannheim, FRG* B Sahakian PhD *Section of Old Age Psychiatry, Institute of Psychiatry, De Crespigny Park, London SE5 8AF*

Keywords: stroke; major depression; laterality

Extensive cerebrovascular disease may cause global psychiatric disturbances affecting mood, cognition and personality¹. Comparatively minor infarcts can produce more subtle and specific neuropsychological deficits, which initiate behavioural disturbances^{2,3}.

The cases of three women are described, who were admitted with a diagnosis of major depression⁴. However, their histories, clinical features and radiological findings exhibited striking similarities, which may indicate a specific psychiatric presentation of left frontal lobe pathology quite distinct from other frontal lobe disturbances like mutism, perseveration, or disinhibition¹. It is suggested that this specific syndrome represents a psychiatric presentation of abulia, literally 'lack of will', which deserves particular diagnostic and therapeutic attention to obviate potentially fatal consequences.

Case reports

Case 1

In August 1987 a 57-year-old right-handed woman experienced an ischaemic stroke with right-sided hemiparesis. The cranial computed tomogram (CT) disclosed small infarcts of the left callosomarginal and left medial striate arteries. A short period of depressive mood was noticed. After 3 months of intensive rehabilitation, however, she appeared much improved: she was able to walk with a stick and to take up most of her usual activities. She retained a mild paresis of her right hand and a moderate paresis of her right leg.

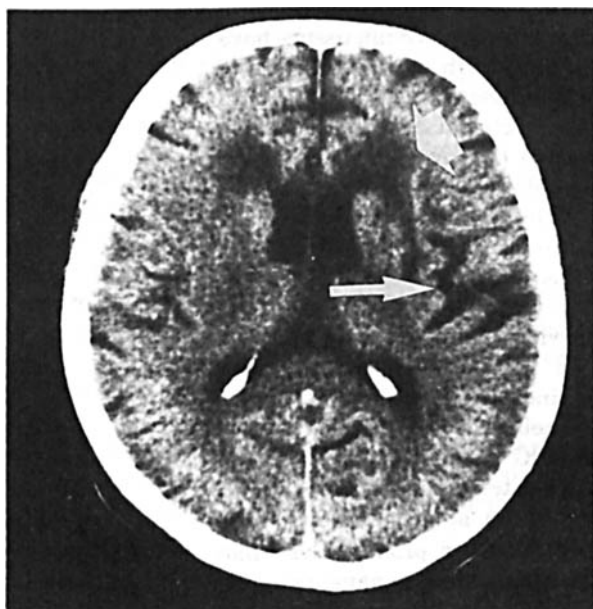

Figure 1. Cranial CT of patient 1: left frontal periventricular infarction (broad arrow), and left fronto-temporal cortical atrophy (slim arrow)

Table 1. Test scores of patients 1 and 2

	Patient 1	Patient 2
'Mini Mental-State' score ¹² (maximum=30)	29 (n)	29 (n)
CAMCOG score ¹³ (maximum=107)	100 (n)	102 (n)
Aphasia battery ¹⁵ (maximum=530)	498 (n)	515 (n)
Token test ¹⁵ (maximum=50)	48 (n)	50 (n)
Word fluency	< 12 (ab)	< 12 (ab)
Wisconsin card sorting test (128 cards) ¹⁷		
categories achieved	2 (ab)	3 (ab)
perseverative errors	52 (ab)	47 (ab)

(n) normal; (ab) abnormal

In November 1988 she was admitted to a psychiatric ward with suspected major depression. She had been apathetic for 2 months, had lost her appetite and weight. She felt unable to work and spent most of her time in bed. She recovered quickly and volunteered to take part in any available activities. After one month of successful antidepressant treatment she returned home.

Following her complete recovery, she relapsed into lethargy in January 1989 and was readmitted to hospital in February. She could not be motivated to get out of her bed at all. She seemed desperate about her inability to overcome her lack of initiative. This time she recovered slowly after several weeks.

Her clinical and CT findings were unchanged (Figure 1). A single photon emission tomography (SPET) showed left frontal hypoperfusion. The electroencephalogram (EEG) showed focal left anterior slowing. Her neuropsychological test scores are summarized in Table 1.

Case 2

A 71-year-old right-handed woman had been admitted to different medical hospitals four times during the last 12 months. She had a 6-year history of hypertension. She recalled a brief episode of transient mild right-sided hemiparesis in 1987.

During the first days in the medical department she was described as depressed with a motor retardation, and a loss of appetite and interest. She always recovered completely without any recognized sign of organic mental disorder. Shortly after her discharges she regularly fell back into apathy and left her bed for only a few minutes a day to drink a sip of water.

At the time of admission to our ward she was mute and rigid. After 3 days she took part in various physical and occupational therapies. Every sign of suspected parkinsonism subsided. One week later she appeared lively and sociable. The tetracyclic antidepressants we used could hardly account for this fast improvement. She seemed to look for an explanation, but was unable to understand what had been

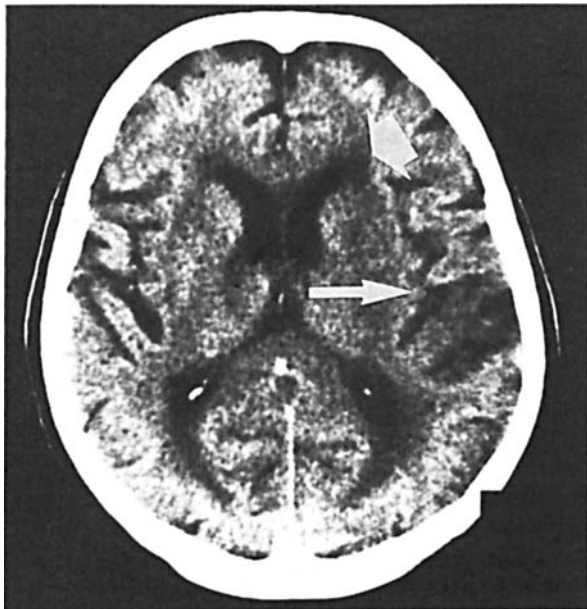

Figure 2. Cranial CT of patient 2: left frontal periventricular hypodensity (broad arrow), and left fronto-temporal cortical atrophy (slim arrow)

going on with her during the previous months. She felt worried and sceptical about her future.

Her cranial CT showed a mild left-sided cortical atrophy, two small hypodense areas, one in the left frontal cortex, the second at the rim of the left anterior horn (Figure 2). Her SPET revealed left frontal hypoperfusion. The EEG showed a slow alpha-activity. The ECG yielded signs of left ventricular hypertrophy. Normal flow signals were detected by extracranial Doppler sonography. Blood tests were normal. Her neuropsychological test performance is summarized in Table 1.

Case 3

A woman of 72 years had been admitted to hospital 3 times during the last year. Initially a loss of appetite and weight led to a thorough gastroenterological examination including duodenoscopy, however, no somatic disease was detected. She received antidepressant treatment for suspected major masked depression and returned home. Soon thereafter she was readmitted after attempted suicide with an overdose of tricyclic antidepressants. Again she

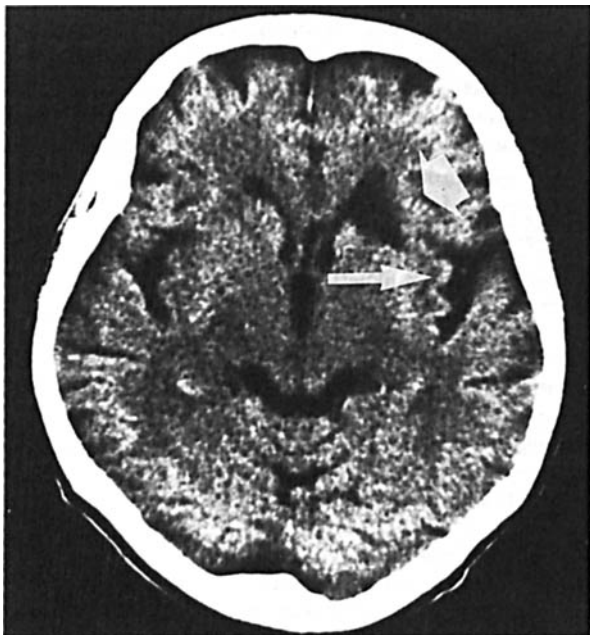


Figure 3. Cranial CT of patient 3: left frontal white matter infarction (broad arrow), left fronto-temporal cortical atrophy (slim arrow), and cerebellar cortical atrophy

recovered quickly and urgently wished to return home. Two days before her planned discharge she tried to jump out of a second floor window. She was transferred to a psychiatric hospital. The symptoms of depression resolved. The next admission to hospital was necessary because of dehydration. She had refused to drink for several days. Each time she returned home she wanted to improve and go back to work, but inevitably she fell back into lethargy after a couple of days. She did not leave her bed, resisted eating or drinking, and was obviously severely upset about her condition.

She was admitted to our psychiatric department after a weight loss of 30 kg within 3 months. Her history did not yield any evidence of ischaemic stroke or any other relevant organic impairment. The neurological examination was normal. Standard laboratory tests, chest X-ray, Doppler sonography of the extracranial arteries, electrocardiogram and EEG were normal. Cranial CT revealed a small left sided infarct of the anterior internal capsule and the head of the caudate, and mild left fronto-temporal cortical atrophy (Figure 3).

She appeared highly motivated in carrying out the occupational therapy activities. She gained weight and said she felt very well. After 3 weeks during a visit to her family for the weekend, she went to bed and would not get up again. She was brought back to our department by ambulance. She appeared equally discouraged and agitated. Antidepressants, neuroleptics and tranquilizers did not exert any beneficial effects during the following weeks. Her condition worsened severely. She was desperate and uncooperative. It was difficult to get her out of bed, and impossible to perform any neuropsychological assessment. Finally her husband insisted on taking her home where she spends most of her time in bed.

Discussion

In summary these three patients had three or more hospital admissions during a 12-month period. They presented with severe psychomotor retardation, weight-loss, exhaustion and self-reproach. Their histories and symptoms suggested a diagnosis of major depression⁴. The symptoms of major depression can be closely mimicked by post-stroke depression as a secondary affective disorder, which may provide insights into the relevant brain areas or mechanisms of affective disorders in general^{2,3,5}.

Cranial CTs (Figures 1-3) revealed left periventricular hypodensities and a widening of the left Sylvian fissure in all patients. Periventricular hypodensities are frequently found in elderly individuals with or without clinical impairment^{6,7}. A localized cerebral atrophy and widening of the left Sylvian fissure have been reported in patients with slowly progressive aphasia⁸. In two of our cases (in case 3 no SPET could be performed) the functional significance of these findings was confirmed by the severely decreased left frontal perfusion resembling observations in localized cerebral atrophy⁹ or in unilateral deep cerebral infarction^{10,11}. The clinical importance of these findings could be verified by the corresponding clinical disturbances.

The clinical interviews did not suggest any dementing illness in the patients and this was supported by the test findings for cases 1 and 2 which are given in Table 1. Their scores on the Mini Mental-State test¹² and CAMCOG¹³ were normal. The Token test as an indicator of left temporoparietal function¹⁴ and further subtests of an aphasia battery were normal¹⁵. The patients, however, produced less than 12 words per minute when asked to name as many animals as possible or as many words starting with a certain letter. In non-demented patients this decrease of word fluency can be interpreted as a sign of frontal lobe dysfunction, which may relate to

circumscribed lesions in the immediate vicinity of the lateral ventricle¹⁶. This suspicion is further underlined by the patients' inability to shift sorting criteria in the Wisconsin Card Sorting test, one of the most sensitive tests of frontal lobe function¹⁷.

The severity of motor paresis or neuropsychological deficits like aphasia does not necessarily correlate with the severity of the affective disturbance^{2,3}. The localization of the lesion appears to be more relevant with respect to the emotional consequences than the size of the ischaemic area. A probably complex relationship of left frontal lesions to depressive disturbances has been reported in several independent studies^{2,10,18,19}.

Major depressive disorders can be accompanied by mild perfusional and metabolic disturbances of the left frontal lobe^{20,21}. Conversely, several intriguing hypotheses were offered to explain the laterality of emotions after ischaemic strokes. Left hemisphere stroke induces a stronger decrease of cortical serotonin-receptors than right hemisphere stroke. Therefore a failure of serotonin-regulation after left-sided stroke was considered as a potential cause for post-stroke depression²².

In the cases presented here the underlying deficits elicited strikingly similar reactive disturbances. Domestic difficulties were uniformly admitted by the patients and their families. Immediately after discharge the patients experienced a painful lack of initiative and energy in the presence of the more permissive and less structured familiar setting. This disappointment after a seemingly perfect recovery proved increasingly distressing to the patients and their families. The patients reacted with guilt and self-reproach, while their families' attitudes changed from those of support and challenge, to pity and anger. The fact that these disturbances resolved quickly in the structured hospital environment indicates the relevance of these reactive behavioural disturbances. Each admission added to the patients' fear of a repeated relapse.

In view of this potentially threatening development, it has to be concluded that patients with this disturbance deserve particular and timely therapeutic attention, which should not end with their discharge. In addition to the treatment with antidepressants they need continued professional treatment provided by day centres because sufficiently structured therapy can not be provided by their own families. Family counselling may also be beneficial in helping the families adjust to the changes in behaviour of a family member.

Despite the complexity of the clinical features and underlying pathology our patients showed compelling similarities. This syndrome of abulia indicates the importance of recognition of both psychiatric and neurological features, since social and interpersonal factors interact with brain damage to produce a particular mental state and this has important implications for management.

Acknowledgments: We thank B Deibel, K Kretzschmar and U Schreiter-Gasser. The preparation of the paper was supported by a grant of the Deutsche Forschungsgemeinschaft (DFG) to HF.

References

1 Blumer D, Benson DF. Personality changes with frontal and temporal lobe lesions. In: Benson DF, Blumer D, eds. *Psychiatric aspects of neurologic disease*. New York: Grune and Stratton, 1976

- 2 Starkstein SE, Robinson RG. Affective disorders and cerebral vascular disease. *Br J Psychiatry* 1989;154:170-82
- 3 Starkstein SE, Robinson RG, Berthier ML, Parikh RM, Price TR. Differential mood changes following basal ganglia vs thalamic lesions. *Arch Neurol* 1988;45:725-30
- 4 American Psychiatric Association. *Diagnostic and Statistical Manual of Mental Disorders, 3rd edn, revised (DSM-III-R)*. Washington DC: American Psychiatric Association, 1987
- 5 Lipsey JR, Spencer WC, Rabins PV, Robinson RG. Phenomenological comparison of poststroke depression and functional depression. *Am J Psychiatry* 1986;143:527-9
- 6 Kohlmeyer K. White matter low attenuation (WMLA) in computed tomography of patients with neuropsychiatric diseases in the presenile and senile period of life: diagnostic significance and pathogenesis. *Fortschr Neurol Psychiatr* 1988;56:277-85
- 7 Zatz LM, Jernigan TL, Ahumada AJ. White matter changes in computed tomography related to aging. *J Comput Assist Tomogr* 1982;6:19-23
- 8 Mesulam MM. Slowly progressive aphasia without generalised dementia. *Ann Neurol* 1982;11:592-8
- 9 Goulding PJ, Northen B, Snowden JS, Macdermott N, Neary D. Progressive aphasia with right-sided extrapyramidal signs: another manifestation of localised cerebral atrophy. *J Neurol Neurosurg Psychiatry* 1989;52:128-30
- 10 Baron JC, d'Antona R, Pantano P, et al. Effects of thalamic stroke on energy metabolism of the cerebral cortex: a positron tomography study in man. *Brain* 1986;109:1243-59
- 11 Metter JE, Riege WH, Hanson WR, Phelps ME, Kuhl DE. Evidence for a caudate role in aphasia from FDG positron computed tomography. *Aphasiology* 1988;2:33-4
- 12 Folstein MF, Folstein SE, McHugh PR. "Mini-Mental State": A practical approach for grading the cognitive state of patients for the clinician. *J Psychiatr Res* 1975;12:189-98
- 13 Roth M, Tym E, Mountjoy CQ, et al. CAMDEX: A standardized instrument for the diagnosis of mental disorder in the elderly with special reference to the early detection of dementia. *Br J Psychiatry* 1986;149:698-709
- 14 Karbe H, Herholz K, Szelies B, et al. Regional metabolic correlates of Token test results in cortical and subcortical left hemisphere infarction. *Neurology* 1989;39:1083-8
- 15 Huber W, Poeck K, Weniger D, Willmes K. *Der Aachener Aphasie-Test*. Goettingen: Hogrefe, 1983
- 16 Naeser MA, Palumbo CL, Helm-Estabrooks N, Stiassny-Eder D, Albert ML. Severe non-fluency in aphasia: role of the medial subcallosal fasciculus and other white matter pathways in recovery of spontaneous speech. *Brain* 1989;112:1-38
- 17 Milner B. Effects of different brain lesions on card sorting. *Arch Neurol* 1963;9:90-100
- 18 Eastwood MR, Rifat SL, Nobbs H, Ruderman J. Mood disorder following cerebrovascular accident. *Br J Psychiatry* 1989;154:195-200
- 19 Sinyor D, Jacques P, Kaloupek DG, Becker R, Goldenberg M, Coopersmith H. Poststroke depression and lesion location: an attempted replication. *Brain* 1986;109:537-46
- 20 Mathew RJ, Meyer JS, Francis DJ, Semchuk KM, Mortel K, Claghorn JI. Cerebral blood flow in depression. *Am J Psychiatry* 1980;137:1449-50
- 21 Baxter LR, Schwartz JM, Phelps ME, et al. Reduction of prefrontal cortex glucose metabolism common to three types of depression. *Arch Gen Psychiatry* 1989;46:243-50
- 22 Mayberg HS, Robinson RG, Wong DF, et al. PET imaging of cortical 5-HT₂-serotonin receptors after stroke: lateralized changes and relationship to depression. *Am J Psychiatry* 1988;145:937-43

(Accepted 31 May 1990. Correspondence to Dr H Förstl, Section of Old Age Psychiatry, Institute of Psychiatry, The Maudsley Hospital, De Crespigny Park, London SE5 8AF)