

We report a case of synchronous positive and negative myoclonus following pontine hemorrhage. Constant synchronous jerking of the eyes, tongue, face, mandible, larynx, pharynx, and diaphragms persisted during sleep. Jerking of limb muscles occurred during volitional activities, but not at rest. Inability to sustain glottic adduction during phonation contributed to severe dysarthria. Electromyography (EMG) revealed positive myoclonus of the branchial musculature with synchronous negative myoclonus in a generalized distribution. Treatment with trazodone reduced the ocular myoclonus but worsened the dysphagia. We suggest that a single neural rhythm generator may produce both positive and negative myoclonus.

Key words: myoclonus • dysarthria • cerebral hemorrhage • pathophysiology • electromyography • videofluoroscopy

MUSCLE & NERVE 13:124-132 1991

## SYNCHRONOUS POSITIVE AND NEGATIVE MYOCLONUS DUE TO PONTINE HEMORRHAGE

JEFFREY B. PALMER, MD, DONNA C. TIPPETT, MA, and JAMES S. WOLF, MD

**M**yoclonus is defined as "sudden, brief, shock-like involuntary movements caused by muscular contractions (positive myoclonus) or inhibitions (negative myoclonus) arising from the central nervous system."<sup>6</sup> The movements may be single or multiple, rhythmic or arrhythmic, and may occur focally, segmentally, or in a generalized distribution. Palatal myoclonus is a syndrome characterized by rhythmic jerking of the soft palate due to involuntary muscular contractions (positive myoclonus). There may be synchronous contraction of other muscles, particularly those of the pharynx, larynx,

eyes, face, and diaphragm. Palatal myoclonus persists during sleep and has a rate of 60–200/min.<sup>10,19</sup> In this article, we report a case of palatal and extremity myoclonus with unusual features caused by pontine hemorrhage. Electromyography (EMG) showed synchronous positive and negative myoclonus, their timing and distribution, and the effects of volitional activities on these phenomena. Videofluoroscopy revealed the mechanism of the dysarthria. Treatment with trazodone led to an improvement in ocular myoclonus but a worsening of dysphagia.

The physiology of negative myoclonus is poorly understood. Classifying involuntary movements due to muscular relaxation as myoclonus is controversial. The occurrence of this phenomenon in association with palatal myoclonus supports its classification as myoclonus. We will discuss implications for the pathophysiology of myoclonus.

### CASE REPORT

A 23-year-old black woman lost consciousness suddenly on 9/9/85 while attending her mother's funeral. Examination in the emergency room revealed bilateral decerebrate posturing with no purposeful responses. Ocular bobbing occurred spontaneously, but there were no lateral extraocular movements in response to caloric stimulation. Corneal and gag reflexes were absent, and there was facial diplegia. All 4 limbs were rigid, and clonus was noted at both knees and ankles. Plantar

From the Division of Rehabilitation Medicine and Department of Otolaryngology—Head and Neck Surgery, The Johns Hopkins University (Dr. Palmer), Department of Speech—Language Pathology, The Good Samaritan Hospital (Ms. Tippett), and private practice of Neurology (Dr. Wolf), Baltimore, Maryland.

Acknowledgments: We thank Keith Kuhlemeier, PhD for assisting with statistical analysis, Barbara Cox-Spahn for preparing the illustrations, and members of the Johns Hopkins University—Good Samaritan Hospital Rehabilitation Medicine Program for helping us evaluate and treat the patient. Mark Hallett, MD suggested using trazodone. Supported in part by awards from the NINCDS (NS01211) and the Johns Hopkins University School of Medicine (Clinician—Scientist Career Development Award).

Presented in part at the annual joint meeting of the American Academy of Physica Medicine and Rehabilitation and American Congress of Rehabilitation Medicine, Seattle, 1988, and the annual meeting of the American Association of Electrodiagnostic Medicine, Washington, DC, 1989.

Address reprint requests to Jeffrey B. Palmer, MD, Good Samaritan Professional Building, 5601 Loch Raven Boulevard, Room 303, Baltimore, MD 21239.

Accepted for publication January 15, 1990.

CCC 0148–639X/91/020124–09 \$04.00  
© 1991 John Wiley & Sons, Inc.

responses were extensor bilaterally. Mechanical ventilation was initiated via an endotracheal tube.

Cranial computed tomography revealed a hemorrhage in the pons (Fig. 1). Angiography revealed normal vertebral and basilar arteries. Cocaine was detected on toxicology screen. EEG revealed nonreactive alpha with excessive slow-wave activity bilaterally. Wave V was absent on auditory brainstem responses. The N18 and P22 somatosensory evoked potentials were absent after stimulation of either median nerve, however the N9 and P13 responses were normal.

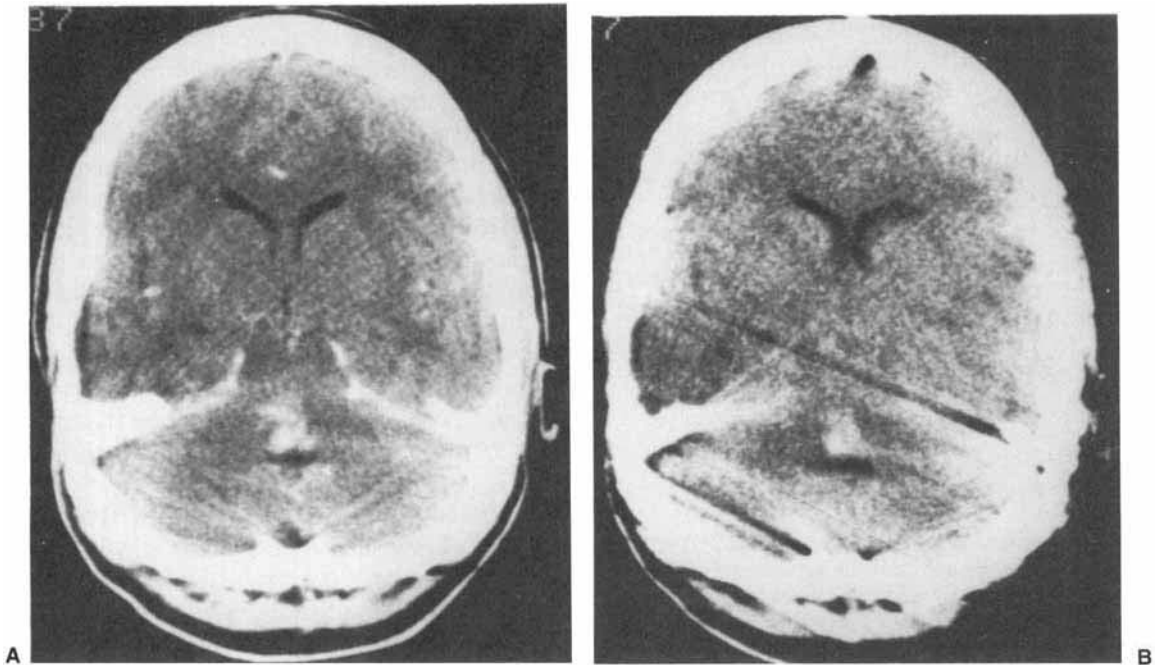
There was slow improvement. Volitional vertical extraocular movements were reported on day 11 of hospitalization. During the third week, tracheostomy and feeding cervical esophagostomy were performed, and mechanical ventilation was discontinued. Volitional contraction of lower extremity muscles were reported on day 22.

The patient was transferred to the Rehabilitation Medicine service on 12/12/85, several days after the tracheostomy was decannulated. She was dysarthric, quadriparetic, and grossly uncoordinated, with rhythmic involuntary jerking of the head, neck, face, palate, and eyes. Trismus was noted. EMG showed continuous involuntary motor unit (MU) activity of the right masseter. When the patient tried to open her mouth, MU activity increased in both masseters. She remained unable

to propel her wheelchair or perform basic self-care activities when discharged to home on 3/25/86. The movement disorder was refractory to Valproic acid, Carbamazepine, and Desipramine. Feeding gastrostomy was performed on 4/11/86, and the esophagostomy was closed.

The patient was readmitted on 3/21/88 for comprehensive reevaluation. Her many neurologic problems included quadriparesis, dysphagia, dysarthria, and neurogenic bowel and bladder. Ability to open the mouth and to swallow had improved. The patient could safely eat a wide variety of solid and liquid foods, limited only by her difficulties with mastication. The gastrostomy was used solely to supplement fluid intake.

Mental status was normal. Ocular examination revealed neuropathic keratitis of the right eye, which necessitated tarsorrhaphy. Both eyes exhibited rapid, repetitive, involuntary, vertical and horizontal movements. Upward and downward gaze were preserved, but horizontal gaze was reduced. Visual acuity, visual fields, and fundoscopic examination were unremarkable. Synchronous with the downward eye movements were rapid, repetitive, involuntary jerking of the palate, tongue, larynx, mandible, left face, and head. These motions persisted during sleep. There was right facial palsy with quadriparesis involving the left side more than the right.

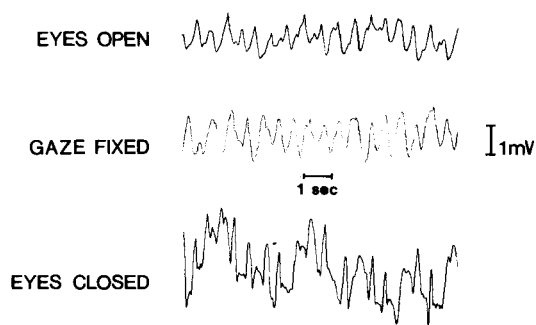


**FIGURE 1.** CT scans with (A) and without (B) intravenous contrast enhancement show a hemorrhage in the pons.

All 4 extremities and the trunk were severely uncoordinated. Involuntary repetitive jerking occurred in the limbs during volitional activity, but not at rest. These involuntary limb movements were often synchronous with the repetitive jerking of head and neck structures. Muscle palpation revealed that the jerking of the limbs was due to involuntary *relaxation* of skeletal muscles during attempts to sustain contraction. Deep tendon reflexes were hyperactive in the left upper and both lower extremities. Plantar responses were flexor (down-going). A "crossed hemi-hypesthesia" was present, involving the left side of the body and right side of the face. The patient had poor sitting balance, and was unable to perform transfers or basic self-care activities. She was unable to stabilize the shoulder girdle to perform upper extremity activities.

Language and cognitive abilities were intact. Verbal output was semantically and syntactically correct. The patient responded appropriately during conversation and in response to specific instructions. Speech evaluation revealed a severe mixed dysarthria. Most striking were phonation breaks (inappropriate pauses in phonation) synchronized with the involuntary jerking. Vocal loudness and pitch fluctuated, resonance was hypernasal, and articulation was imprecise.

Electro-oculography revealed continuous vertical and horizontal ocular jerking which increased upon closing the eyes (Fig. 2). EKG revealed sinus tachycardia of 120 beats/min with no variation of R-R intervals, consistent with dysautonomia. EEG was normal. EEG-EMG correlations were studied by "back averaging" of EEG activity preceding



**FIGURE 2.** Ocular myoclonus. Electro-oculogram (EOG) showing vertical motion of the left eye under three different conditions: eyes open, gazing into the distance (top); gaze fixed in the primary position on an object 6 feet away (middle); and eyes closed (bottom). Ocular myoclonus persisted under various conditions; the amplitude of vertical motion increased when the eyes were closed.

EMG bursts; *no* time-locked EEG discharges were present. After performing EMG and videofluoroscopic studies (to be described), a trial of clonazepam was started in 5/88. The dose was increased gradually to a maximum of 1.25 mg/day in divided doses. Ocular and limb myoclonus improved slightly, but severe lethargy and dysphagia developed. Despite eliminating thin liquids from the diet, aspiration pneumonia occurred, and the drug was discontinued. The patient returned home on 6/19/88 after an uneventful recovery, and was readmitted to the hospital 7 months later for a trial of trazodone. On a dose of 100 mg every 8 hours, there was a reduction in ocular myoclonus, and the patient reported a subjective improvement in functional vision. The dysphagia was exacerbated, but the patient elected to continue trazodone because of the improvement in functional vision. No respiratory sequelae have occurred during one year of treatment.

## METHODS

**Electromyography.** EMG was performed on 4/8/88, 4/12/88, and 5/6/88 during sustained muscle contraction and at rest to define the distribution of myoclonus, differentiate positive from negative myoclonus, and assess the timing of myoclonus in various muscles.

Surface electrode pairs were applied to the masseter, biceps brachii, triceps brachii, extensor carpi radialis, and quadriceps femoris muscles on the left, to the sternocleidomastoid muscle (SCM) on the right, and to the orbicularis oculi (OOculi) and tibialis anterior muscles on both sides. An additional pair of surface electrodes was applied to the suprahyoid muscles in the midline, recording from the anterior digastric and mylohyoid muscles of both sides via a single pair of electrodes. Needle electrodes were inserted into the tongue and left orbicularis oris (OOris) muscles. A maximum of 4 muscles were studied simultaneously; the suprahyoid muscles were included in every recording. Following 4 channel differential amplification with bandpass of 20 Hz to 10 kHz, signals were recorded on a strip chart at a paper speed of 5 cm/sec. One recording session included simultaneous EKG.

All recordings were made while the patient sat in her wheelchair. The patient was instructed either to relax and gaze into the distance or to perform volitional activities. These included holding the eyes closed, the mouth opened or closed, the elbow flexed or extended, the wrist extended, the knee extended, or the ankle dorsiflexed.

The timing of myoclonus was analyzed by measuring a subset of the EMG strip chart recordings with a ruler. A muscle was excluded if the measurement points were unclear. The right OOculi muscle was excluded from all measurements because of the recent tarsorrhaphy. Cycles of myoclonus were defined as beginning at the onset of each EMG burst (positive myoclonus) in the suprahyoid muscles, and ending at the onset of the next cycle. Duration measurements were made for EMG bursts (positive myoclonus) and EMG pauses (negative myoclonus). The sequence of onset of myoclonus among the muscles was analyzed by measuring the latency (delay until the onset of the burst or pause for that muscle) following the onset of EMG bursts in the suprahyoid muscles. For EMG pauses, we also measured the "end latency" (delay from onset of suprahyoid EMG burst onset until *end* of the EMG pause). This was necessary since EMG pause onsets were poorly defined in lower extremity muscles. When more than one pause occurred in a muscle during a single cycle, only the first pause was measured.

Arithmetic means were calculated for duration and latency measurements. Differences among muscles were analyzed with one-way ANOVA. The HSD procedure<sup>3</sup> was used to assess differences between individual pairs of means. The critical value for rejecting the null hypothesis was 1%.

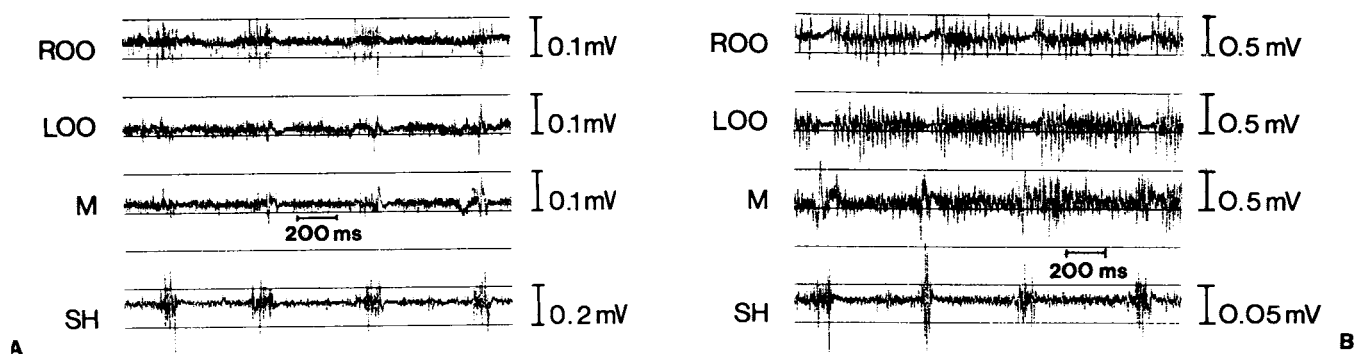
**Videofluorography.** The mechanism of the dysarthria was studied with videofluorography. The patient was seated comfortably in a wheelchair. The oral cavity, larynx, and pharynx were imaged in the lateral view. The larynx and diaphragms were imaged in the postero-anterior (PA) view. Record-

ings were analyzed by viewing a video monitor during normal speed and slow motion replay.

## RESULTS

**Electromyography.** When the patient was at rest, there were repetitive, synchronous bursts of MU activity in the suprahyoid, masseter, OOculi, OOris, tongue, and SCM muscles. The pattern was typical of positive myoclonus (Fig. 3A). Cycle durations varied, but occurred in a unimodal distribution with a mean of 510.8 msec (Table 1), corresponding to a mean frequency of 1.96 Hz. Cycle duration was not significantly affected by the performance of volitional activity. Durations of the individual EMG bursts varied among cycles and among muscles, but the mean burst duration did not vary significantly among muscles (Table 2). The sequence and latency of onset of EMG bursts (time following burst onset in the suprahyoid muscles) also varied among cycles. However, the mean burst latency did not vary significantly among muscles (Table 2). The EMG bursts were not synchronous with the EKG.

The limb muscles were electrically silent when the patient was at rest (Fig. 4A). Continuous (tonic) MU activity was present during sustained volitional muscle contraction. However, this MU activity was interrupted frequently by recurrent pauses, consistent with negative myoclonus (Fig. 4B). These pauses were often synchronous with the EMG bursts (positive myoclonus) that continued without interruption in other muscles. Negative myoclonus was also present in the OOculi muscles during sustained eye closure (Fig. 3B), and in the masseter during mouth closing (jaw adduction). However, negative myoclonus was not



**FIGURE 3. (A)** EMG of branchial muscles showed synchronous, repetitive bursts of activity in the right and left orbicularis oculi (ROO and LOO), masseter (M), and suprahyoid muscles (SH), consistent with positive myoclonus. The patient was relaxed and gazing into the distance. **(B)** The patient was then told to hold her eyes closed. There was tonic myoelectric activity interrupted by repetitive, pauses in ROO and LOO, consistent with negative myoclonus. Positive myoclonus persisted in M and SH. EMG bursts in M and SH were synchronous with EMG pauses in ROO and LOO.

**Table 1.** Cycle duration.

Condition	No. of measurements	Cycle duration (mean $\pm$ SD, msec)	Range (msec)
Relaxed	20	491.0 $\pm$ 98.3	280.0–640.0
Active	52	518.5 $\pm$ 80.4	320.0–660.0
Combined	72	510.8 $\pm$ 85.9	280.0–660.0

Note: The difference in mean cycle duration between relaxed and active conditions was not statistically significant by a two-tailed t-test ( $t = 1.11$ ,  $P = 0.27$ ).

detected in the suprahyoid muscles during jaw abduction. By definition, negative myoclonus occurred only during active muscle contraction, since it was an inhibitory phenomenon.

In limb muscles, there was often more than one inhibition phase during each cycle of myoclonus. Typically, two inhibition phases per cycle were present in the upper extremities. The pattern of MU activity was highly complex in the lower extremities during sustained contraction. The quantity of MU activity waxed and waned in an irregular rhythm, and there were periods of total inhibition of activity (Fig. 5). These EMG pauses were synchronized incompletely with EMG bursts in the branchial muscles.

The patient also exhibited “spreading” of efferent activity. Performance of a task with one muscle group regularly caused tonic MU activity in other muscle groups quite distant from the first. Negative myoclonus was seen often in both muscle groups. This occurred even in antagonistic muscles, where synchronous contraction (co-activation) happened frequently (Fig. 4B).

Unlike the mean burst duration, the mean duration of EMG pauses varied significantly among muscles. It was shorter in the left OOculi than in limb muscles (Table 3). The mean onset latency of

**Table 2.** Duration and latency of EMG bursts (mean  $\pm$  SD, msec).

Muscle	Duration (N)	Onset latency (N)
Suprahyoid	106.00 $\pm$ 20.41 (25)	—
Masseter	86.67 $\pm$ 20.14 (24)	9.52 $\pm$ 18.57 (21)
Orbicularis Oculi	89.17 $\pm$ 27.01 (24)	13.00 $\pm$ 16.25 (20)
Sternocleidomastoid	90.00 $\pm$ 25.82 (28)	18.89 $\pm$ 29.48 (18)

Note: The differences in burst duration among the muscles were not significant by one way ANOVA ( $F = 3.46$ ,  $P = 0.019$ ). Neither were the differences in burst latency ( $F = 0.9$ ,  $P = 0.412$ ).

**Table 3.** Duration and latency of EMG pauses (mean  $\pm$  SD, msec).

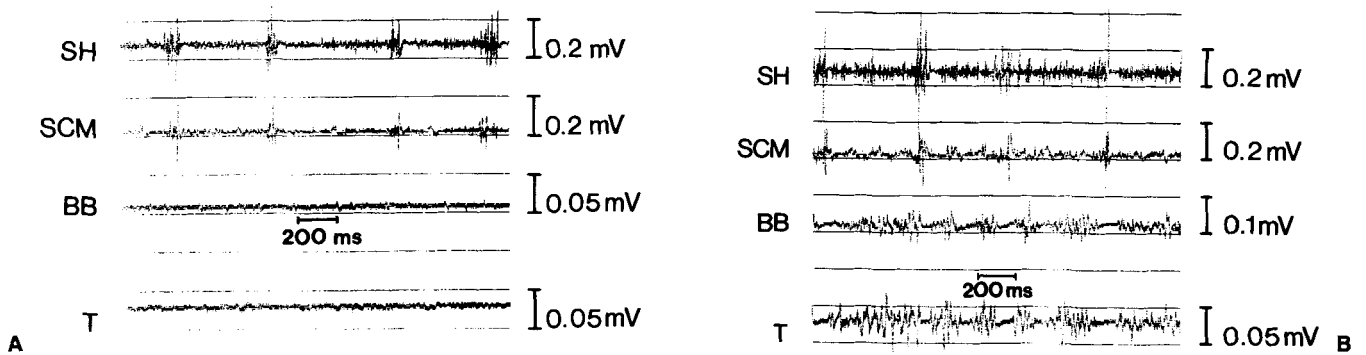
Muscle	Duration (N)	Onset latency
Orbicularis Oculi	52.73 $\pm$ 23.54 (22)	35.24 $\pm$ 25.22 (21)
Biceps	91.91 $\pm$ 22.33 (47)	60.61 $\pm$ 24.23 (33)
Extensor Carpi Radialis	78.46 $\pm$ 23.95 (26)	46.96 $\pm$ 18.69 (23)
Triceps	80.00 $\pm$ 20.58 (18)	60.00 $\pm$ 22.19 (14)

Note: The differences in pause duration and pause latency among the four muscles were significant by one way ANOVA ( $F = 14.92$ ,  $P < 0.001$  and  $F = 6.21$ ,  $P = 0.001$ , respectively). Pause duration was significantly shorter in orbicularis oculi than the other 3 muscles (HSD test,  $P < 0.01$ ). However, only the orbicularis oculi and biceps varied significantly in latency (HSD test,  $P < 0.01$ ).

EMG pauses varied significantly among muscles, being shorter in the OOculi than the biceps (Table 3). The mean end latency of EMG pauses also varied significantly among muscles (Table 4). In general, they were shortest in the Ooculi and upper extremity muscles, longer in the quadriceps, and longest in the tibialis anterior. The variability of end latency measurements was greater in lower extremity muscles than in upper extremity or OOculi muscles.

**Videofluorography.** Imaging in the lateral view revealed repetitive, synchronous jerking of the mandible, tongue, palate, pharynx, and larynx when the patient was at rest (Fig. 6). During speaking, the jerking continued, but was superimposed on the motions of speech. This jerking indicated myoclonus of structures derived embryologically from the branchial arches.

Diaphragmatic imaging revealed synchronous, symmetrical motion of the two diaphragms. The diaphragms jerked caudad repetitively while the patient was at rest between breaths, at the functional residual lung capacity. During breath holding after deep inspiration (approximating the vital capacity), the diaphragms jerked *rostrad* repetitively. During inspiration and expiration, the diaphragms moved in a saccadic fashion. These findings clearly represented myoclonus of the diaphragm. The diaphragms are muscles of inspiration which pull caudad when they contract, so the jerking caudad at end-expiration was probably positive myoclonus. The diaphragms may have been tonically active during breath holding (with the lungs inflated). In that case, negative myoclonus could have caused rostral jerking of the diaphragms.



**FIGURE 4.** (A) EMG showed electrical silence in the biceps brachii (BB) and triceps (T) and positive myoclonus in the suprahyoid (SH) and sternocleidomastoid (SCM) muscles. The patient was relaxed and gazing into the distance. (B) The patient was then asked to hold her elbow flexed and wrist extended. There was tonic activity interrupted by repetitive, pauses of contraction in the limb muscles, consistent with negative myoclonus. Positive myoclonus persisted in the head and neck. EMG bursts in SH and SCM were synchronous with the EMG pauses in BB and T.

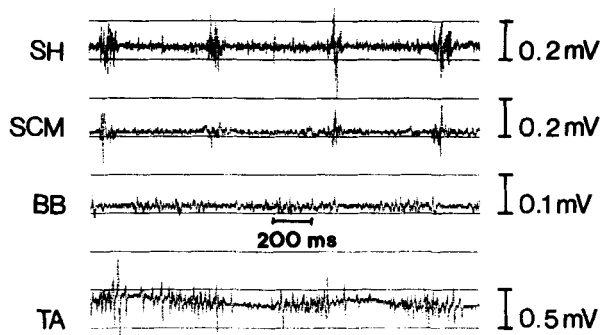
Imaging of the larynx in the PA view permitted assessment of vocal fold motion. When the patient was at rest, the larynx exhibited repetitive jerking which included laryngeal elevation and synchronous, symmetrical, partial adduction of the vocal folds. During phonation, the vocal folds adducted completely. However, phonation was interrupted frequently by repetitive, symmetrical, partial *abduction* of the vocal folds that was synchronous with the recurring elevation of the larynx (Fig. 7). Phonation was interrupted during each occurrence of the abduction, accounting for the unusual dysarthria. The repetitive vocal fold adduction at rest probably represents positive myoclonus of the intrinsic laryngeal musculature. The recurrent abduction probably represents neg-

ative myoclonus. We have not performed EMG studies of the diaphragm nor the intrinsic laryngeal musculature.

#### DISCUSSION

Palatal myoclonus due to pontine pathology, and its association with abnormal limb movements, have been described previously.<sup>1,8,9,10,12,17,19</sup> To our knowledge, the co-existence of positive and negative myoclonus in this syndrome has not been recognized. Tahmouh<sup>17</sup> described patients with palatal myoclonus due to cerebellar or brainstem lesions. Myoclonus was noted in facial, suprahyoid, palatal, and laryngeal muscles at rest, and in limb muscles during volitional activities. Suprahyoid EMG revealed positive myoclonus, while limb muscles showed no activity at rest. However, during volitional activity, there was rhythmic myoelectric activity in the limb muscles as well as the suprahyoid muscles. Muscle contractions in the 2 muscle groups occurred at the same frequency, suggesting they shared a common pathophysiologic mechanism. This notion was supported by Nagaoka and Narabayashi, who studied the soleus H-reflex in patients with palatal myoclonus. They showed rhythmic variation of H-reflex amplitude corresponding with that of the palatal myoclonus, suggesting that the mechanism generating the myoclonus had widespread effects.<sup>13</sup>

Our patient's myoclonus reflected rhythmic spontaneous activity in the central nervous system. The persistence of myoclonus during sleep and insensitivity to volitional control indicated its physiologic autonomy. The synchronicity of the positive and negative myoclonus implied that they



**FIGURE 5.** Ankle dorsiflexed. EMG showed positive myoclonus in the suprahyoid (SH) and sternocleidomastoid (SCM) muscles and negative myoclonus in the biceps brachii (BB) and tibialis anterior (TA) muscles. The patient was holding her knee extended and ankle dorsiflexed. Synchronization of the myoclonus were less distinct in the lower extremities than elsewhere.

**Table 4.** End latency of EMG pauses (mean  $\pm$  SD, msec).

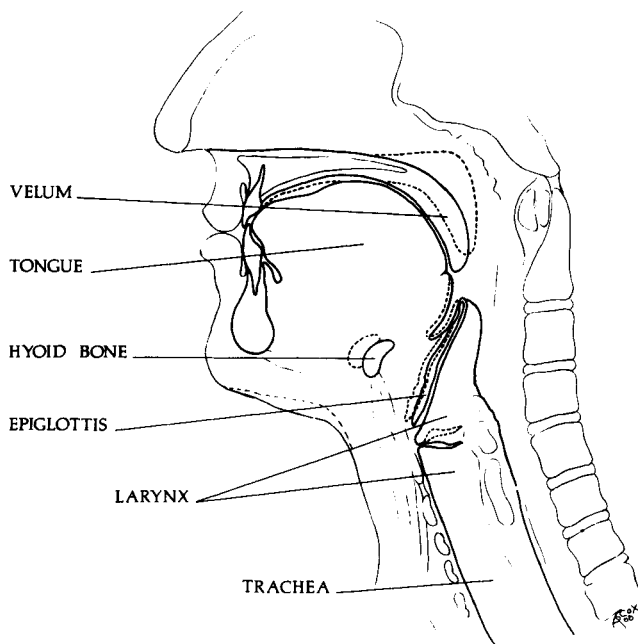
Muscle	N	Pause latency	Variance	Coefficient of variation (%)
Orbicularis Oculi	22	90.91 $\pm$ 16.01	256.32	17.61
Biceps	39	141.03 $\pm$ 27.12	735.49	19.23
Triceps	15	140.00 $\pm$ 20.00	400.00	14.29
Extensor Carpi Radialis	24	127.50 $\pm$ 28.17	793.55	22.09
Quadriceps Femoris	27	191.11 $\pm$ 81.02	6564.24	42.39
Tibialis Anterior	19	309.47 $\pm$ 90.77	8239.19	29.33

Note: The differences in pause end latency among the six muscles were significant by one way ANOVA ( $F = 44.68$ ,  $P = 0.0001$ ). Pause latency was longer in tibialis anterior than the other 5 muscles (HSD test,  $P < 0.01$ ). Pause latency was longer in quadriceps than in orbicularis oculi, biceps, and extensor carpi radialis (HSD test,  $P < 0.01$ ). The latency difference between the quadriceps and tibialis anterior was not statistically significant. The variance and coefficients of variation was highest in the lower extremities, indicating a greater degree of dispersion in the data.

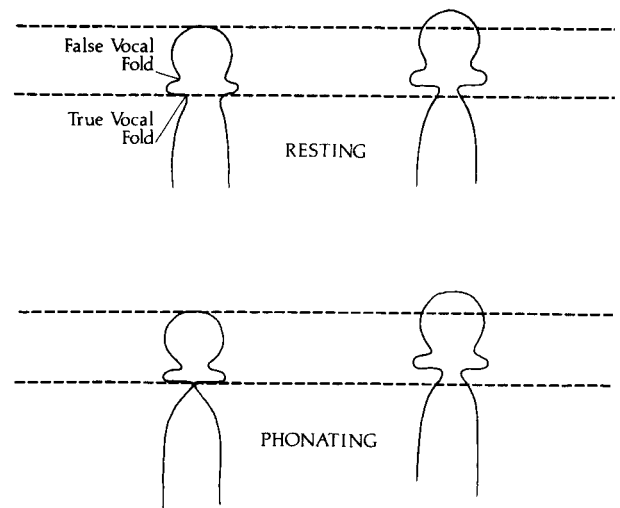
shared a single central rhythm generator. Neuro-pathological studies of palatal myoclonus have shown characteristic abnormalities.<sup>10,12</sup> There were lesions in the Guillian–Mollaret triangle with hypertrophy of the olivary nuclei. Acute vertical ocular myoclonus following pontine infarction or hemorrhage has been described previously.<sup>9</sup> That our patient's lesions was in the pons was supported by the CT scan. The pontine hemorrhage may have produced a localized rhythm generator by creating an irritative focus. Alternatively, activ-

ity of a distant physiologic rhythm generator could have been disinhibited by the pontine lesion. This generator was probably not in the cerebral cortex, since routine EEG was normal and back-averaging from EMG revealed no time-locked EEG spike. Hallett<sup>7</sup> examined the sequence of onset of positive myoclonus in branchial muscles to localize the rhythm generator in reticular reflex myoclonus. We are reluctant to do so since the differences in onset latency among the muscles was not statistically significant.

The notion of a physiologic rhythm generator



**FIGURE 6.** Drawing of head and neck structures to show the branchial myoclonus as seen by videofluoroscopy in the lateral view. The position of each structure between myoclonic jerks is shown by the solid lines. The dotted lines indicate the position of the structures at the peak of a myoclonic jerk.



**FIGURE 7.** Laryngeal myoclonus. Outline of the laryngeal airway between jerks (left) and at the peak of a myoclonic jerk (right), as seen by videofluoroscopy in the postero-anterior view. When the patient was resting, each jerk included elevation and partial adduction of the vocal folds (top). When the patient phonated (bottom left), the vocal folds were fully adducted, but each myoclonic jerk caused elevation and partial abduction of the vocal folds. This resulted in repetitive interruption of phonation.

is supported by animal studies showing that rhythmic mastication and swallowing under control of brainstem pattern generators may be elicited by electrical stimulation of the cerebral cortex, putamen, or corticobulbar fibers in the internal capsule or pons.<sup>4,15,16</sup> The frequency of neural output to masticatory muscles following subcortical or brainstem stimulation in rabbits ranged from 2.4 to 4.8 bursts/sec.<sup>4</sup> This is close to the myoclonus frequency of 1.5 to 3.6/sec in our patient.

A physiologic rhythm generator in the brainstem could have produced bursts of activity in both excitatory and inhibitory descending long fiber tracts. This would account for the synchronicity of positive and negative myoclonus. EMG pauses during negative myoclonus involved massive inhibition of myoelectric activity in skeletal muscle. There must have been widespread modulation of lower motor neuron activity by the rhythm generator. Negative myoclonus was observed only during volitional activities, but not at other times. The inhibitory neuronal activity probably occurred during every cycle of myoclonus, but its *expression* required volitional activation of skeletal muscle.

Although the negative myoclonus had a generalized distribution, its precise manifestations varied among anatomic areas, particularly in the number of EMG pauses per cycle of myoclonus and the degree of synchronicity with the positive branchial myoclonus. Synchronization was greatest at rostral and least at caudal levels. This may reflect a complex, oligo-synaptic pathway, and the complex interaction of excitatory and inhibitory activity.

In some respects, our patient's problem re-

sembled asterixis. Asterixis is a form of negative myoclonus characterized by pauses in myoelectric activity during attempts to sustain contraction. EMG pauses are synchronous in muscles of the same limb, but asynchronous in muscles of different limbs.<sup>20</sup> This differs from the synchronous myoclonus of our patient. Although commonly associated with metabolic encephalopathy, asterixis may result from focal brain lesions.<sup>2,5,18</sup> However, few studies have examined the timing of EMG pauses in asterixis due to structural pathology.

Myorhythmia is a slow alternating tremor that may result from structural brain lesions. Extremity myorhythmia occurs most commonly in brainstem vascular disease and cerebellar degenerations. It may be synchronous or asynchronous, is typically present at rest, and may be associated with palatal myoclonus ("palatal myorhythmia"). The tremor frequency is usually 2–3/sec.<sup>11</sup> Although some authors have suggested that myorhythmia is a form of myoclonus,<sup>14</sup> its precise relationship to positive and negative myoclonus is unclear.

Myoclonus had an enormous impact on our patient's functional capabilities. She was unable to fixate gaze or joint position, or maintain the upright posture, because she could not sustain contraction of muscle. There was also an unusual impairment of speech; repetitive involuntary vocal fold abduction caused recurrent interruption of phonation. This abnormality was appropriately termed "myoclonic dysarthria." Additional careful physiologic studies of myoclonus and related disorders may yield new insights into the control of movement.

## REFERENCES

1. Bouchayer M, Haguenaer JP, Oudot J, Gonay P: Myoclonics velo-pharyngo-laryngees: Enregistrement cinematographique et electromyographique. *J Franc Oto-Rhino-Laryngol* 1969;18:537–540.
2. Brill V, Sharpe JA, Ashby P: Midbrain asterixis. *Ann Neurol* 1979;6:362–364.
3. Daniel WW: *Biostatistics: A Foundation for Analysis in the Health Sciences*, 4th ed. New York, Wiley, 1987, pp 292–295.
4. Dellow PG, Lund JP: Evidence for central timing of rhythmic mastication. *J Physiol* 1971;215:1–13.
5. Dengos J-D, Verroust J, Boucharaine A, Serdaru M, Barbizet J: Asterixis in focal brain lesions. *Arch Neurol* 1979;36:705–707.
6. Fahn S, Marsden CD, Van Woert MH: Definition and classification of myoclonus, in Fahn S, Marsden CD, Van Woert, MH (eds): *Advances in Neurology, Myoclonus* (vol. 43). New York, Raven, 1986, pp 1–5.
7. Hallett M, Chadwick D, Adam J, Marsden CD: Reticular reflex myoclonus: a physiologic type of human post-hypoxic myoclonus. *J Neurol Neurosurg Psychiatry* 1977;40:253–264.
8. Jankovic J, Pardo R: Segmental myoclonus. *Arch Neurol* 1986;43:1025–1031.
9. Keane JR: Acute vertical ocular myoclonus. *Neurology* 1986;36:86–89.
10. Lapresle J: Palatal myoclonus, in Fahn S, Marsden CD, Van Woert, MH (eds): *Advances in Neurology, Myoclonus* (vol. 43). New York, Raven, 1986, pp 265–272.
11. Massuci EF, Kurtzke JF, Saini N: Myorhythmia: A widespread movement disorder. *Brain* 1984;107:53–79.
12. Nathanson M: Clinical observations and post-mortem findings in patients with myoclonus of the palate and related structures. *Trans Amer Neurol Assoc* 1954;79:72–74.
13. Nagaoka M, Narabayashi H: Palatal myoclonus-its remote influence. *J Neurol Neurosurg Psychiatr* 1984;47:921–926.
14. Silfverskiold BP: Rhythmic myoclonias including spinal myoclonus, in Fahn S, Marsden CD, Van Woert, MH (eds):



- Advances in Neurology, Myoclonus (vol. 43). New York, Raven, 1986, pp 275–284.
15. Sumi T: Some properties of cortically evoked swallowing and chewing in rabbits. *Brain Res* 1969;15:107–120.
  16. Sumi T: Role of the pontine reticular formation in the neural organization of deglutition. *Jap J Physiol* 1972; 22:295–314.
  17. Tahmouh AJ, Brooks JE, Keltner JL: Palatal myoclonus associated with abnormal ocular and extremity movements. *Arch Neurol* 1972;27:431–440.
  18. Tarsy D, Lieberman B, Chirico-Post J, Benson F: Unilateral asterixis associated with a mesencephalic syndrome. *Arch Neurol* 1977;34:446–447.
  19. Van Woert MH, Hwang EC: Myoclonus, in Vinken PJ, Bruyn GW (eds): *Handbook of Clinical Neurology, Neurologic Manifestations of Systemic Diseases, Part I* (vol. 38). Amsterdam: Elsevier/North Holland, 1979, pp 575–593.
  20. Young RR, Shahani BT. Asterixis: One type of negative myoclonus, in Fahn S, Marsden CD, Van Woert, MH (eds): *Advances in Neurology, Myoclonus* (vol. 43). New York, Raven, 1986, pp 137–156.