

Cisplatin-Associated Occlusion of the Internal Carotid Artery

Thorleif Etgen^{a,c} Georg Weidenhöfer^a Thomas Kubin^b

^a Department of Neurology,

^b Department of Hematology and Oncology, Klinikum Traunstein,

^c Department of Psychiatry and Psychotherapy, Technische Universität München, Germany

Key Words

Germ cell tumor · Cisplatin · Chemotherapy · Stroke

Summary

Background: Cisplatin is a highly effective antineoplastic agent used also in germ cell cancer. Thromboembolic complications like pulmonary embolism, myocardial infarction and stroke have occasionally been reported. **Case Report:** A 46-year-old man with seminoma and without any cerebrovascular risk factors developed an acute stroke with complete right-sided hemiparesis and global aphasia, during the second cycle of cisplatin-based chemotherapy. After exclusion of an intracerebral bleeding, a systemic thrombolysis was performed. Further diagnostics revealed an acute occlusion of the left carotid internal artery with infarction in the territory of the middle cerebral artery. The patient slowly recovered; however, a moderate aphasia and partial hemiparesis persisted whereas the tumor was in complete remission. Months later, the patient developed symptomatic epilepsy. **Conclusions:** Ischemic stroke associated with cisplatin-based chemotherapy is rare, but may be disabling or even fatal. With regard to the literature, several precautions are discussed to minimize the risk of these major side effects.

Schlüsselwörter

Keimzelltumor · Cisplatin · Chemotherapie · Schlaganfall

Zusammenfassung

Hintergrund: Cisplatin ist ein sehr effektives Chemotherapeutikum, das auch in der Behandlung von Keimzelltumoren verwendet wird. Thromboembolische Komplikationen wie z.B. Lungenembolie, Myokardinfarkt und Schlaganfall wurden in Einzelfällen berichtet. **Fallbericht:** Ein 46-jähriger Mann mit einem Seminom und ohne zerebrovaskuläre Risikofaktoren erlitt während des zweiten Zyklus einer Chemotherapie mit Cisplatin einen Schlaganfall mit kompletter rechtsseitiger Hemiparese und globaler Aphasie. Nach Ausschluss einer intrazerebralen Blutung wurde eine systemische Thrombolyse durchgeführt. Die weitere Diagnostik ergab einen akuten Verschluss der linken A. carotis interna mit einem Mediateilinfarkt links. Der Patient erholte sich langsam, wobei jedoch eine mittelschwere Aphasie und Hemiparese zurückblieben. Der Tumor zeigte eine komplette Remission. Monate später entwickelte der Patient eine symptomatische Epilepsie. **Schlussfolgerungen:** Ischämische Hirninfarkte im Zusammenhang mit einer Chemotherapie mit Cisplatin sind selten, können aber zu schweren Behinderungen oder sogar zum Tod führen. Unter Berücksichtigung der Literatur werden mehrere Maßnahmen diskutiert, um das Risiko solcher schwerwiegenden Nebenwirkungen zu minimieren.

Introduction

Cisplatin is a highly effective antineoplastic agent widely used also in germ cell cancer. Side effects of cisplatin-based chemotherapy consist of gastrointestinal symptoms, neuro-, oto- and nephrotoxicity and myelosuppression. Thromboembolic complications like pulmonary embolism, myocardial infarction and stroke have occasionally been reported [1]. We describe a young male patient with seminoma who suffered from an acute occlusion of the left carotid internal artery during cisplatin-based chemotherapy.

Case Report

A 46-year-old man was diagnosed with seminoma and a semi-castration was performed. Staging revealed several lymph nodes paraaortically and at the renal trunk. 8 days after the operation, the first cycle of chemotherapy was started. He received cisplatin (38 mg) and vepesid (185 mg) daily on the first 5 days. Additionally, bleomycin (30 mg) was given on

the 1st, 8th and 15th day. The second cycle was started 1 week after the end of the last therapy with bleomycin. Dexamethasone was given concomitantly. 2 days after the 5-day therapy with cisplatin and vepesid, the patient suddenly developed a right-sided weakness and could not speak. On admittance 70 min after the onset of the stroke, he showed a complete right-sided hemiparesis and global aphasia (National Institute of Health stroke scale (NIHSS) 17 points). 30 min after arrival at the hospital, a systemic thrombolysis was performed after an intracerebral hemorrhage had been excluded by cranial computed tomography. No early and rapid improvement of his hemiparesis and aphasia could be achieved by the thrombolysis. Neurosonography and magnetic resonance angiography (MRA) revealed an acute occlusion of the left internal carotid artery without any signs of macroangiopathy or vasospasm (fig. 1). Extensive diagnostic workup did not show any potential embolic sources: the electrocardiogram (ECG)-, monitoring ECG- and 24-h ECG-revealed sinus rhythm and the transthoracic and transesophageal echocardiography were normal. Laboratory investigations could exclude thrombophilia, vasculitis or any other potential sources. Only a slight hypercholesterolemia (216 mg/dl) was detected and treatment with simvastatin was initiated. Magnetic resonance imaging (MRI) confirmed an ischemia in the territory of the left middle cerebral artery (fig. 2); a dissection at the carotid level could be ruled out. The patient received heparin anticoagulation in order to avoid other emboli originating from the acute occlusion. After 1 week, he was transferred to an acute rehabilitation clinic. Neurosonography prior to discharge showed a persistent carotid occlusion. By intensive physiotherapy and speech therapy, he slowly recovered and was able to walk and understand most things; however, a moderate nonfluent aphasia and hemiparesis persisted. After 5 months, he was readmitted with a complex focal epileptic seizure and antiepileptic treatment with lamotrigine was started. Neurosonography revealed chronic occlusion of the left carotid artery. The tumor was in complete remission although chemotherapy had been stopped after the stroke.

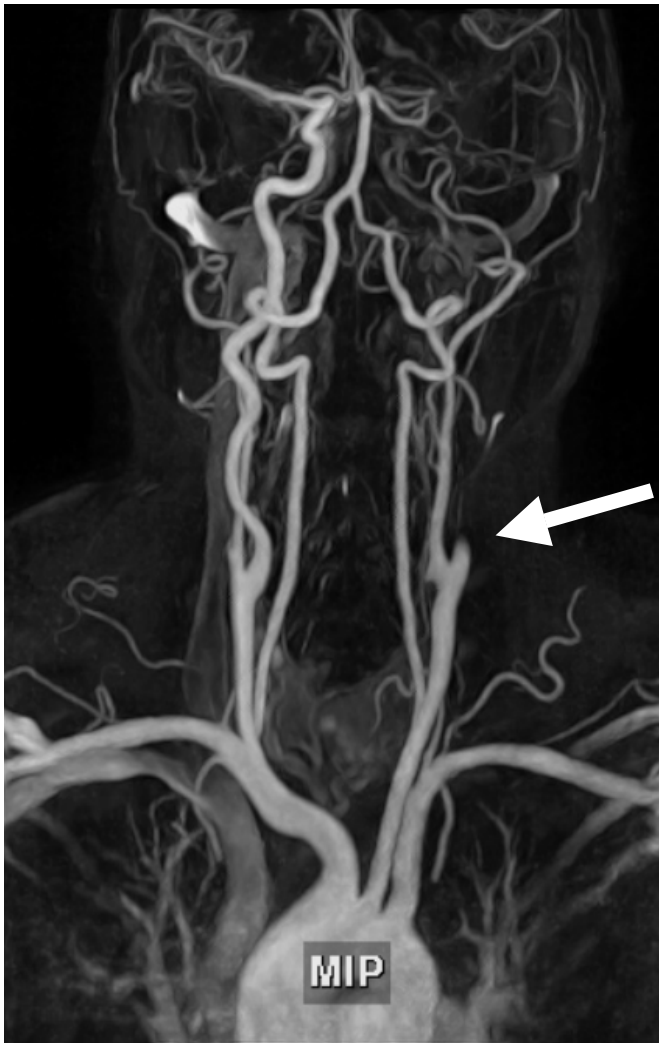


Fig. 1. MRA showing complete occlusion of the left internal carotid artery (arrow).

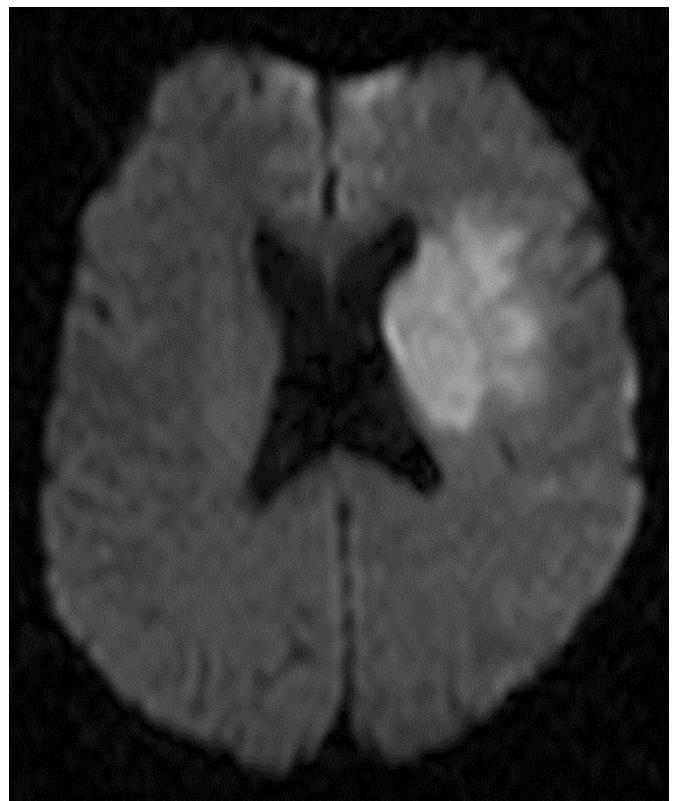

Fig. 2. MRI with ischemic stroke in the territory of the left middle cerebral artery.

Table 1. Overview of reported cisplatin-associated strokes in male patients with testicular tumors

Reference	Age, years	Tumor	Chemotherapy	Latency to cisplatin	Risk factors	Stroke etiology	Outcome
Doehn et al. [10]	31	seminoma	2 × Cis + Eto + Bleo	24 h	smoking	basilar artery thrombosis	dead
Icli et al. [7]	19	teratoma	4 × Cis + Eto + Bleo, 3 × Cis + Eto + Ifo, 2 × Cis + Eto	27 days	none	right cerebellar area (after coronary angiography)	remission?
Azak et al. [11]	17	nonseminomatous germ cell	4 × Cis + Eto + Bleo	48 h	none	multiple hemorrhagic infarcts	dead
Pretnar-Oblak et al. [6]	44	seminoma	2 × Cis + Eto + Bleo	24 h	none	occlusion of left internal carotid artery	disabled, epilepsy
Russmann et al. [8]	27	embryonal carcinoma	Cis + Eto + Bleo	48 h	smoking, cannabis	thrombus in left internal carotid artery	dead
Dietrich et al. [12]	38	germ cell	2 × Cis + Ifo + Eto	6–12 h	none	multiple ischemic and hemorrhagic infarcts in corpus callosum	incomplete recovery
Weijl et al. [3], patient 10	24	embryonal carcinoma	2 × Cis + Eto + Bleo	6 days	?	?	?
Weijl et al. [3], patient 15	34	embryonal carcinoma	1 × Cis + Eto + Bleo	5 days	?	?	?
Gerl et al. [4]	26	teratoma	3 × Cis + Eto + Bleo	27 h	none	occlusion of right middle cerebral artery	dead
Samuels et al. [9], patient 4	58	chorio-carcinoma	1 × Cis + Bleo + Vin	24 h	?	occlusive arteritis	dead

Cis = Cisplatin, Eto = etoposide, Bleo = bleomycin, Ifo = ifosfamide, Vin = vinblastine, ? = no details available.

Discussion

The risk of thromboembolic events is increased in patients with malignancies, but data on the risk of ischemic stroke after chemotherapy is limited. In a retrospective review of 10,963 patients, the incidence of post-chemotherapy ischemic stroke was 0.137%. Hemispheric stroke with middle cerebral artery territory involvement was the most common. Platinum-based chemotherapy was the most common latest regimen (56%). The great majority of strokes (75%) occurred within 10 days after the latest chemotherapy and 63% happened after the first cycle [1]. In one major study of 180 patients with germ cell tumor and cisplatin-based chemotherapy, no evidence of an increased risk of subsequent cardiovascular disease was found. However, this was only a retrospective analysis and the percent return was only around 60% [2]. However, a more recent cohort study of 179 patients with germ cell cancer receiving cisplatin-based chemotherapy found an increased risk of thromboembolic complications, in particular in those patients with liver metastases or high-dose corticosteroids (> 80 mg dexamethasone/cycle) [3]. An overview of the few cases of cisplatin-associated stroke among male patients with germ cell tumors is presented in table 1.

Several pathophysiological mechanisms are discussed: First, arteriosclerosis is the most unlikely mechanism, as most reported patients did not have any cerebrovascular risk fac-

tors (except for smoking in some cases), no arteriosclerotic changes were found in diagnostic workup and the majority of patients suffered from major embolic strokes. Second, an embolization from the tumor itself could be possible. However, a hematologic spread seems anatomically not plausible as many patients did not have lung metastases and a patent foramen ovale would also be required in each case. In addition, Gerl et al. reported no tumor cells in the surgically removed thrombus [4]. Third, a high proportion of testicular cancer patients treated with cisplatin may develop hypomagnesemia, which increases the sensitivity of arterial smooth muscle cells to contracting agents [5]. This may contribute to long-term vascular toxicity by supporting arterial spasms and endothelial cell damage. However, some cases could not verify the presence of hypomagnesemia at the time of stroke [6, 7], and ultrasound could exclude vasospasm in our and another case [8]. Fourth, a disturbance in prostacyclin-thromboxane homeostasis may promote thrombotic vascular occlusion. In addition, steroids used as anti-emetic agents contribute to chemotherapy-induced thrombotic vascular complications [3]. Fifth, a vascular toxicity of cisplatin is possible. The close temporal association of chemotherapy and stroke is evidence for this hypothesis. Most of the ischemic strokes developed within the first days after chemotherapy.

According to a recent review, the overall incidence of thromboembolic events associated with cisplatin-based chemo-

therapy in male germ cell cancer might be as high as 10% [3]. The majority of these complications (8.4%) were venous thromboembolic events with mostly pulmonary embolism; arterial events occurred less often (1.6%) [3]. Other reported sites of arterial thromboembolic events consisted of myocardial infarction and iliac arteries [3, 9]. These complications are of special clinical interest since they occur in young cancer patients with an excellent curative potential and may even be fatal. Every effort should therefore be undertaken to minimize the risk of such disabling or even fatal side effects of cisplatin-based chemotherapy. Prior to cisplatin-based chemotherapy, an informed consent of the patient about a possible cerebrovascular risk is mandatory. Although data will probably never be sufficient to establish an evidence-based guideline, con-

comitant use of acetylsalicylic acid and low-molecular-weight heparin during each cycle of cisplatin-based chemotherapy should be considered. Careful monitoring of magnesium and, in case of hypomagnesemia, a substitution are recommended. As demonstrated in our case, a systemic thrombolysis can safely be performed even in cancer patients without increased risk of bleeding and should therefore not be withheld.

Conflict of Interest

The authors declare that there has been no conflict of interest and that none of the authors has received any form of funding for his contribution to this manuscript.

References

- 1 Li SH, Chen WH, Tang Y, Rau KM, Chen YY, Huang TL, Liu JS, Huang CH: Incidence of ischemic stroke post-chemotherapy: A retrospective review of 10,963 patients. *Clin Neurol Neurosurg* 2006;108:150–156.
- 2 Nichols CR, Roth BJ, Williams SD, Gill I, Muggia FM, Stablein DM, Weiss RB, Einhorn LH: No evidence of acute cardiovascular complications of chemotherapy for testicular cancer: An analysis of the Testicular Cancer Intergroup Study. *J Clin Oncol* 1992;10:760–765.
- 3 Weijl NI, Rutten MF, Zwinderman AH, Keizer HJ, Nooy MA, Rosendaal FR, Cleton FJ, Osanto S: Thromboembolic events during chemotherapy for germ cell cancer: A cohort study and review of the literature. *J Clin Oncol* 2000;18:2169–2178.
- 4 Gerl A, Clemm C, Wilmanns W: Acute cerebrovascular event after cisplatin-based chemotherapy for testicular cancer. *Lancet* 1991;338:385–386.
- 5 Vogelzang NJ, Torkelson JL, Kennedy BJ: Hypomagnesemia, renal dysfunction, and Raynaud's phenomenon in patients treated with cisplatin, vinblastine, and bleomycin. *Cancer* 1985;56:2765–2770.
- 6 Pretnar-Oblak J, Zaletel M, Jagodic M, Zaletel M: Thrombosis of internal carotid artery after cisplatin-based chemotherapy. *Eur Neurol* 2007;57:109–110.
- 7 Icli F, Karaoguz H, Dincol D, Demirkazik A, Gunel N, Karaoguz R, Uner A: Severe vascular toxicity associated with cisplatin-based chemotherapy. *Cancer* 1993;72:587–593.
- 8 Russmann S, Winkler A, Lovblad KO, Stanga Z, Bassetti C: Lethal ischemic stroke after cisplatin-based chemotherapy for testicular carcinoma and cannabis inhalation. *Eur Neurol* 2002;48:178–180.
- 9 Samuels BL, Vogelzang NJ, Kennedy BJ: Severe vascular toxicity associated with vinblastine, bleomycin, and cisplatin chemotherapy. *Cancer Chemother Pharmacol* 1987;19:253–256.
- 10 Doehn C, Buttner H, Fornara P, Jocham D: Fatal basilar artery thrombosis after chemotherapy for testicular cancer. *Urol Int* 2000;65:43–45.
- 11 Azak A, Oksuzoglu B, Deren T, Onec BM, Zengin N: Cerebrovascular accident during cisplatin-based combination chemotherapy of testicular germ cell tumor: An unusual case report. *Anticancer Drugs* 2008;19:97–98.
- 12 Dietrich J, Marienhagen J, Schalke B, Bogdahn U, Schlachetzki F: Vascular neurotoxicity following chemotherapy with cisplatin, ifosfamide, and etoposide. *Ann Pharmacother* 2004;38:242–246.