

Cerebral venous sinus thrombosis in early pregnancy: An unusual presentation of primary antiphospholipid syndrome

Tharangrut Hanprasertpong¹, Jitti Hanprasertpong¹ and Kittipong Riabroi²

Departments of ¹Obstetrics and Gynecology and ²Radiology, Faculty of Medicine, Prince of Songkla University, Songkhla, Thailand

Abstract

Cerebral venous sinus thrombosis, an unusual presentation of antiphospholipid syndrome, is a rare condition in pregnancy, particularly in the first trimester. The authors of this case report present the case of a 20-year-old woman with sudden onset of headaches and hemiparesis in the first trimester of pregnancy. She underwent a computed tomography scan and magnetic resonance imaging. The image findings and the autoimmune serum test were consistent with a cerebral venous sinus thrombosis complicated by primary antiphospholipid syndrome. The patient's hemiparesis improved with subcutaneous low molecular weight heparin and oral aspirin. In the third trimester of pregnancy, she developed seizures that were controlled by antiepileptic drugs. She delivered a healthy baby at 37 weeks' gestation without immediate or late postpartum complications.

Key words: antiphospholipid syndrome, cerebral venous sinus thrombosis, pregnancy.

Introduction

Cerebral venous sinus thrombosis (CVST) as a cause of fatal outcome was first described in the early 19th century.¹ CVST is an uncommon condition of pregnancy. The true incidence of CVST in pregnancy is not known. However, data from multicenter studies have shown that cerebral vein and dural sinus thrombosis related to pregnancy and puerperium were 6.3% and 13.8%.² The mortality rate of this condition ranges from 5% to 30%.³ The predisposing conditions include puerperium, trauma, dehydration, infection, disseminated intravascular coagulation, hypercoagulation states, malignancy, connective tissue disease and medication (e.g. oral contraceptives, synthetic steroids and asparaginase).^{3,4}

Primary antiphospholipid syndrome (PAPS) is an autoimmune condition characterized by the occurrence of venous or arterial thrombosis, pregnancy complications or by the presence, upon repeated

determination, of elevated levels of antiphospholipid antibodies (aPL), including anticardiolipin antibody and lupus anticoagulant (LA), in the absence of other known autoimmune conditions.⁵ The incidence of thrombotic complications in patients with antiphospholipid syndrome (APS) is around 2.5% patient/years.⁶ The lower extremities is the most common site involved in venous thrombosis of APS, but upper extremities, intracranial veins, inferior and superior vena cava, hepatic veins, portal vein, renal vein and retinal veins are rare.⁷

Although CVST in pregnant women has been reported, most cases occur in the postpartum stage.^{8–14} Because the number of reported CVST cases in APS pregnant women is limited, there is little consensus on its management. Herein, we experienced a case of CVST with PAPS in the first trimester of pregnancy in which the pregnancy continued and a healthy child was delivered.

Received: September 26 2008.

Accepted: February 4 2009.

Reprint request to: Dr Tharangrut Hanprasertpong, Department of Obstetrics and Gynecology, Faculty of Medicine, Prince of Songkla University, Songkhla 90110, Thailand. Email: htharang@medicine.psu.ac.th

Case Report

A 20-year-old Thai primigravida woman, in her tenth week of pregnancy, experienced headache and a sudden onset of right hemiparesis. She denied any related previous medical history or previous history of headaches. On admission, her level of consciousness and other general physical examination findings were unremarkable. Her neurological system, however, revealed left hemiparesis. The subsequent computed tomography (CT) scan was unremarkable. The magnetic resonance imaging (MRI) presented a mixed-staged thrombus in the superior sagittal sinus and acute stage thrombi in the right frontal vein, right parietal cortical vein, right transverse sinus and right sigmoid sinus (Fig. 1a,b). The patient was immediately started on 40 mg of s.c. nadroparin sodium twice daily, and the following investigations were carried out: complete blood count, electrolytes, prothrombin time, activated partial thromboplastin time, LA, anticardiolipin G and M, activated protein C, protein S, antinuclear antibody and anti double strain DNA. All the tests were within normal limits except for the LA which was positive. Taking the investigative results together suggested APS. The patient's hemiparesis gradually improved and she was discharged and able to go home without neurological sequelae. An LA test was still positive at 12 weeks after the first admission, which was considered as confirmation of the APS. The patient continued the nadroparin sodium throughout her pregnancy. Maternal blood pressure and fetal growth were monitored throughout the pregnancy for early detection of pre-eclampsia and intrauterine fetal growth restriction.

At gestation week 33 she had a generalized tonic-clonic seizure lasting four minutes. At admission, she was afebrile, had a normal blood pressure, and no hemiparesis. An MRI appeared normal. Her seizure was controlled by sodium valproate. The patient recovered well after taking antiepileptic drugs and remained stable, without any recurring seizures.

At 37 weeks of gestation, she vaginally delivered a healthy female infant with a birth weight of 2800 g. Nadroparin sodium was withheld during delivery, as the last pre-delivery dose was administrated 12 h before induction of delivery and no more was given until 6 h post-delivery. The infant exhibited normal Apgar scores and showed normal development at the one-year follow up. On the sixth day post-partum the anticoagulant was changed from nadroparin sodium to

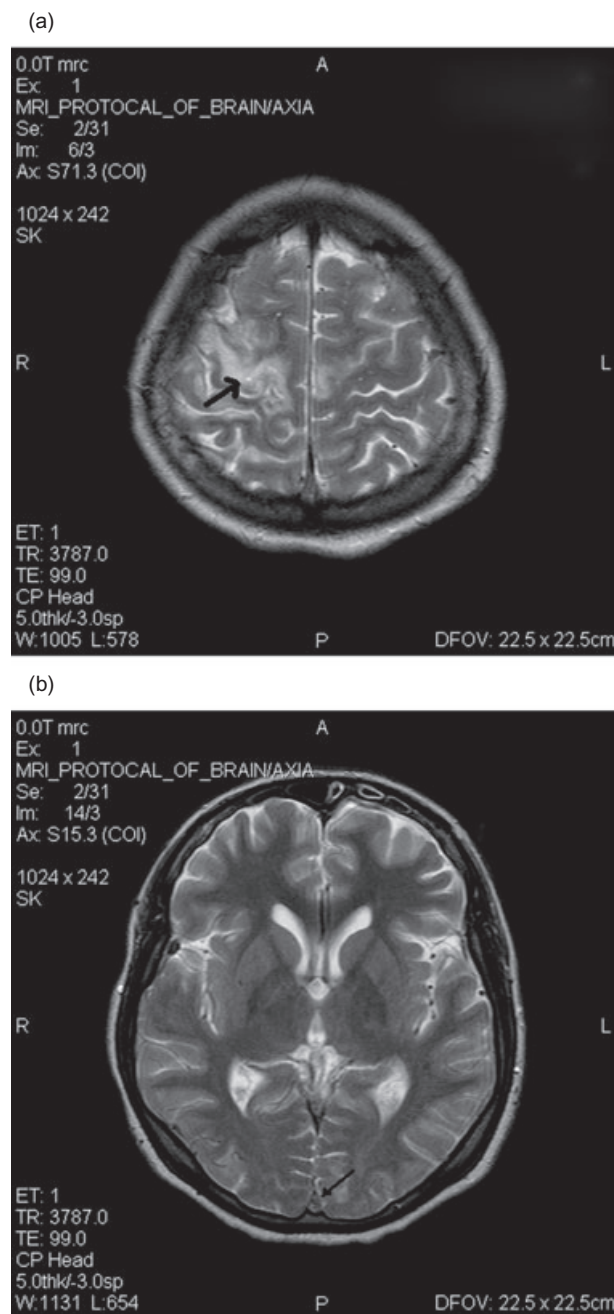


Figure 1 (a) Magnetic resonance image (MRI) shows bilateral high frontal brain edema, larger in the right side. (b) MRI shows mixed-staged thrombus in superior sagittal sinus.

warfarin, which was continued until the sixth week postpartum. The patient continued taking antiepileptic drugs and did not have any problems at the one-year follow up.

Discussion

CVST is characterized by lesions caused by the occlusion of the superior sagittal sinus, the dominant transverse sinus or the sigmoid sinus. The clinical features and their severity are highly variable, ranging from isolated headaches to a deep coma, depending on the extent and location of the effected sinus, the venous collateral vessels, and the rate of thrombus progression.^{3,4,10,15} The most frequent symptom associated with CVST is headaches.⁴ Other symptoms are seizures, nausea, vomiting, weakness, confusion and aphasia.^{3,9-15} The case at hand exhibited a sudden onset of headaches and hemiparesis. In pregnant women, most headaches are usually innocent. Paulson reported that more than 90% of pregnant patients with headaches have either migraine or tension-type headaches.¹⁶ However, a headache caused by CVST during pregnancy and puerperium is variable, so it is possible the physician may overlook this life-threatening condition. Therefore, we suggest that CVST should be considered in the differential diagnosis of any pregnant patient with additional risk factors for thrombosis who has headaches. Saw *et al.* reported 42 cases of dural venous sinus thrombosis; the commonest anatomical site of thrombosis was superior the sagittal sinus (64%). Multiple sites of thrombosis were more frequent than a single site as in our case.¹⁷ The possible mechanisms for the increased risk of CVST in the peripartum period are damage to venous sinuses due to fluctuation in intracranial pressure during delivery, and the hypercoagulable state associated with pregnancy due to platelet adhesion and an increase in clotting factors.¹³

In the present case, we observed a rare case of CVST with a persistent high-titer of lupus anticoagulant measured in the 10th and the 23rd weeks of pregnancy. Because there was no evidence of autoimmune diseases or other inciting factors such as infection or malignancy, PAPS was the determined diagnosis. Previous case reports of CVST during pregnancy detected aPL also.^{3,18} The pathogenesis of thrombosis associated with APS is not clear. Proposed pathophysiological mechanisms may be categorized into two types. The first one suggests that aPL may act *in vivo* by disrupting hemostatic reactions occurring on cell membranes. The aPL may alter the kinetics of the normal procoagulant and anticoagulant reactions by cross-linking membrane-bound proteins, by blocking protein-protein interactions, and/or by blocking the access of other proteins to the phospholipid membrane. The second one suggests that aPL may stimulate certain cells thereby

altering the expression and secretion of various molecules.¹⁹

In contrast to our case, in most previous postpartum CVST cases no aPL was detected.^{9-11,13,14} The possible mechanism of thrombosis during postpartum may be different from the one during the antenatal period. Some authors have suggested a link between dural puncture and the development of CVST postpartum.^{13,14,20} Dural puncture causes loss of cerebrospinal fluids (CSF) and the lowering of CSF pressure causes a downward shift of the brain, with traction on the cortical veins and sinuses. The deformation of the venous walls may induce thrombosis.^{4,13}

In the past, angiography was the mainstay diagnostic tool. But during pregnancy, other less invasive and non-radiation exposure imaging, such as CT and MRI, are more appropriate. There is no consensus on imaging technique of choice for diagnosing CVST during pregnancy. In our case, MRI was a sensitive test for the detection of CVST and may be the investigation test of choice when suspicion arises.^{14,21} Arxer *et al.* have reported a case of CVST in a late pre-eclamptic woman. The CT and MRI results were both reported as normal but magnetic resonance venography (MRV) revealed sinus thrombosis.¹¹ Nazziola *et al.* has also suggested that MRV should be performed when clinical suspicion for CVST exists and the noncontrast head CT scan demonstrates intracerebral hemorrhage, evolving infarction, hypodensity consistent with edema, or normal brain.¹⁰

CVST management includes the treatment of the underlying condition, the thrombolytic treatment, the reduction of intracranial pressure, symptomatic treatment and prevention of remote seizures. The treatment options for thrombosis include anticoagulation, thrombolytic therapy, and surgical thrombolectomy.^{3,10,12-14,18,22,23} Heparin or low molecular weight heparin (LMWH) is considered to be a common treatment in limiting the spread of the thrombus and accelerating its dissolution.^{10,12-14} LMWH, which was prescribed in our case, is preferable because of its longer half-life, easier dose adjustment and lower risk of thrombocytopenia and hemorrhage.²³ Patients who deteriorate despite heparin therapy might benefit from thrombolytic treatment.¹⁰ Chow *et al.* reported an accelerated recanalization of occulted dural sinuses and cerebral veins with rheolytic thrombectomy and intra-arterial thrombolysis.³ Aspirin and corticosteroid do not have any benefit for CVST in pregnant APS patients.^{6,24} Although the duration of treatment has not been well documented, we suggest the continuation of

treatment for at least 6 weeks into/during postpartum following the regimen for venous thrombosis embolism in pregnancy.²³

In conclusion, CVST is a rare condition in pregnancy that can present itself with a variety of signs and symptoms. Underlying causes such as APS should be considered. Accurate diagnosis and prompt treatment can provide a good outcome of pregnancy and can prevent long-term complications.

Acknowledgments

The authors would like to thank the Language Consultant at the Faculty of Medicine, Prince of Songkla University, Songkhla, Thailand for his editorial assistance.

References

1. Krabenbuhl H. Cerebral venous thrombosis; the diagnostic value of cerebral angiography. *Schweiz Arch Neurol Psychiatr* 1954; **74**: 261–287.
2. Ferro JM, Canhã P, Stam J, Boussier MG, Barinagarrementeria F; ISCVT Investigators. Prognosis of cerebral vein and dural sinus thrombosis: Results of the International Study on Cerebral Vein and Dural Sinus Thrombosis (ISCVT). *Stroke* 2004; **35**: 664–670.
3. Chow K, Gobin YP, Saver J, Kidwell C, Dong P, Vinuela F. Endovascular treatment of dural sinus thrombosis with rheolytic thrombectomy and intra-arterial thrombolysis. *Stroke* 2000; **31**: 1420–1425.
4. Stam J. Thrombosis of the cerebral veins and sinuses. *N Engl J Med* 2005; **352**: 1791–1798.
5. Miyakis S, Lockshin MD, Atsumi T *et al.* International consensus statement on an update of the classification criteria for definite antiphospholipid syndrome (APS). *J Thromb Haemost* 2006; **4**: 295–306.
6. Bick RL. Antiphospholipid thrombosis syndromes. *Hematol Oncol Clin North Am* 2003; **115**: 115–147.
7. Barker WF, Bick RL. The clinical spectrum of antiphospholipid syndrome. *Hematol Oncol Clin North Am* 2008; **22**: 33–52.
8. Nagai S, Horie Y, Akai T, Takeda S, Takaku A. Superior sagittal sinus thrombosis associated with primary antiphospholipid syndrome. *Neurol Med Chir (Tokyo)* 1998; **38**: 34–39.
9. Chisholm ME, Campbell DC. Postpartum postural headache due to superior sagittal sinus thrombosis mistaken for spontaneous intracranial hypotension. *Can J Anaesth* 2001; **48**: 302–304.
10. Nazzola E, Elkind MS. Dural sinus thrombosis presenting three months postpartum. *Ann Emerg Med* 2003; **42**: 592–595.
11. Arxer A, Pardina B, Blas I, Ramio L, Villalonga A. Dural sinus thrombosis in a late preeclamptic woman. *Can J Anaesth* 2004; **51**: 1050–1051.
12. Acheson J, Malik A. Cerebral venous sinus thrombosis presenting in the puerperium. *Emerg Med J* 2006; **23**: e44.
13. Ghatge S, Uppugonduri S, Kamarzaman Z. Cerebral venous sinus thrombosis following accident dural puncture and epidural blood patch. *Int J Obstet Anesth* 2008; **17**: 267–270.
14. Borum SE, Naul LG, McLeskey CH. Postpartum dural venous sinus thrombosis after postdural puncture headache and epidural blood patch. *Anesthesiology* 1997; **86**: 487–490.
15. Niwa J, Ohyama H, Matumura S, Maeda Y, Shimizu T. Treatment of acute superior sagittal sinus thrombosis by T-PA infusion via venography-direct thrombolytic therapy in the acute phase. *Surg Neurol* 1998; **49**: 425–429.
16. Paulson GW. Headaches in women, including women who are pregnant. *Am J Obstet Gynecol* 1995; **173**: 1734–1741.
17. Saw VP, Kollar C, Johnston IH. Dural sinus thrombosis: A mechanism-based classification and review of 42 cases. *J Clin Neurosci* 1999; **6**: 480–487.
18. Levine SR, Kieran S, Puzio K, Feit H, Patel SC, Welch KMA. Cerebral venous thrombosis with lupus anticoagulants. *Stroke* 1987; **18**: 801–804.
19. Espinosa G, Cervera R, Font J, Shoenfeld Y. Antiphospholipid syndrome: Pathogenic mechanisms. *Autoimmun Rev* 2003; **2**: 86–93.
20. Barrett J, Alves E. Postpartum cerebral venous sinus thrombosis after dural puncture and epidural blood patch. *J Emerg Med* 2005; **28**: 341–342.
21. Salvati CA. Cerebral vein thrombosis shown by MRI. *Headache* 1990; **650**: 650–651.
22. Benamer HT, Bone I. Cerebral venous thrombosis: Anticoagulants or thrombolytic therapy? *J Neurol Neurosurg Psychiatry* 2006; **69**: 427–430.
23. Clark P. Maternal venous thrombosis. *Eur J Obstet Gynecol Reprod Biol* 2008; **139**: 3–10.
24. James AH, Brancaccio LR, Price T. Aspirin and reproductive outcomes. *Obstet Gynecol Surv* 2008; **63**: 49–57.