

Unstable Stenosis of the Internal Carotid Artery Caused by a Craniofacial Nail-Gun Injury

—Case Report—

Tetsuya HIRAISHI^{*,**}, Tadashi KAWAGUCHI^{*}, Tsutomu KOBAYASHI^{*},
Masaru TOMIKAWA^{*}, Yasushi ITO^{**}, and Yukihiro FUJII^{**}

^{*}Department of Neurosurgery, Nagaoka Red Cross Hospital, Nagaoka, Niigata;

^{**}Department of Neurosurgery, Brain Research Institute, University of Niigata, Niigata

Abstract

A 30-year-old carpenter suffered accidental piercing of his jaw by a 3-inch nail from a nail gun. No neurological deficits were found on admission. Computed tomography showed that the tip of the nail had reached the foramen lacerum. Cerebral angiography revealed severe stenosis at the C₄ portion of the left internal carotid artery (ICA) and marked decrease in the flow of the distal ICA. He had developed right hemiparesis and sensory aphasia by the following morning. T₂-weighted and fluid-attenuated inversion recovery magnetic resonance imaging showed a focal hyperintense signal in the left central region indicating cerebral infarction. Repeat angiography demonstrated that the antegrade blood flow from the occluded point on the admission day had partially resumed, and endovascular trapping of the ICA was successfully carried out. The nail was then removed safely without problematic bleeding. The patient suffered no additional deficit, and his sensory aphasia and right hemiparesis gradually improved. The fluctuating blood flow through the unstable stenosis of the ICA related to nail movement possibly caused the delayed cerebral infarction. To avoid the occurrence of such events, rapid treatment after necessary investigations is recommended in patients with craniofacial penetrating injuries that affect the ICA.

Key words: nail, endovascular trapping, internal carotid artery, trauma, cerebral infarction

Introduction

Penetrating craniofacial injuries resulting from nail-gun use are increasingly reported around the world. The nail gun is a common tool in the workplace and even the home because of its simplicity and availability. The Centers for Disease Control and Prevention in the United States indicated that an average of 37,000 patients with injuries related to nail-gun use were treated annually in emergency departments during the 5-year period spanning 2001–2005.⁶⁾ The most common cause of nail-gun injury is work-related accidents, but self-harm or suicide in psychiatric patients is also known.⁹⁾ Various types of such craniofacial injuries may be associated with obstruction of the internal carotid artery (ICA). However, the therapeutic strategy will depend on various individual factors, such as the type and degree of the ICA injury, the dynamics of the cerebral blood flow, and the patient's condition. Endovascular techniques may be useful to treat the injured ICA.^{1,10,15)}

We treated a patient presenting with delayed cerebral ischemia caused by unstable stenosis of the ICA in the acute phase after a craniofacial nail-gun injury, using endovascular trapping to avoid further cerebrovascular de-

terioration.

Case Report

A 30-year-old carpenter suffered accidental piercing of the left side of his jaw by a 3-inch nail from a nail gun while working. He was ambulatory when admitted to our hospital. His Glasgow Coma Scale score was 15. He presented with restricted opening of the mouth and dysphagia due to pain, but no neurological deficits. Craniography showed the nail embedded within the soft tissue of the face (Fig. 1A). Multiplanar reconstructed computed tomography images revealed that the nail had reached the foramen lacerum (Fig. 1B–D). Cerebral digital subtraction angiography (DSA) on the day of admission revealed severe stenosis at the C₄ portion of the left ICA and marked decrease in the flow of the distal ICA (Fig. 2). DSA revealed no extravasation from the ICA and no evidence of vascular wall dissection or formation of a pseudoaneurysm. The crossflow through the anterior communicating artery (AcomA) and the backflow through the posterior communicating artery (PcomA) were satisfactory. We performed tracheostomy on the day of admission to avoid difficulty in breathing if laryngeal edema occurred.

He had developed slight right hemiparesis and sensory

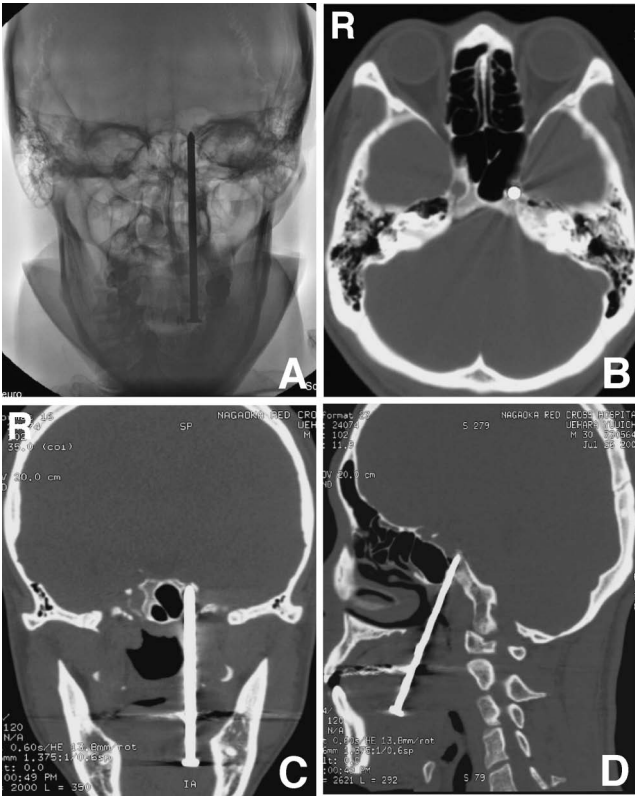


Fig. 1 A: Lateral craniogram showing a nail embedded in the face. B-D: Multiplanar reconstructed computed tomography images showing the exact location of the nail, with the tip of the nail reaching into the foramen lacerum as confirmed on the axial (B), coronal (C), and sagittal (D) views.

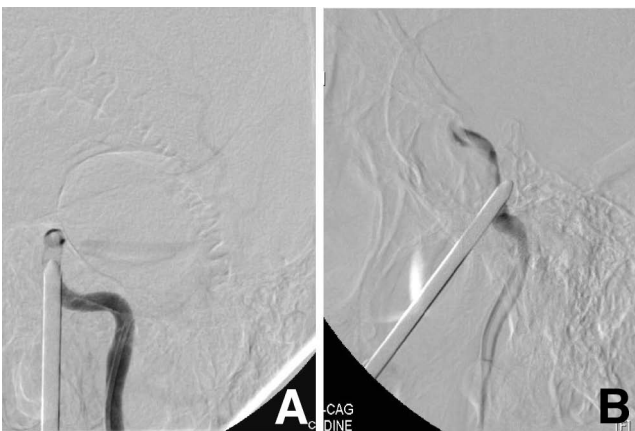

Fig. 2 Anteroposterior (A) and lateral (B) left internal carotid arteriograms showing the left internal carotid artery is severely stenotic at the C₄ portion due to compression by the nail, and the distal flow is markedly decreased. The anterior and middle cerebral arteries are not shown. There is no evidence of extravasation.

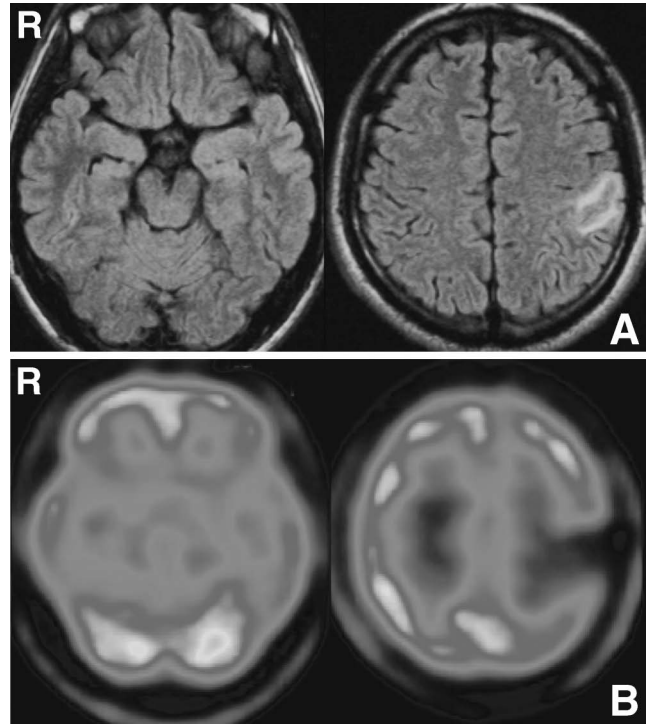


Fig. 3 A: Axial fluid-attenuated inversion recovery (FLAIR) magnetic resonance images showing a hyperintense signal indicating cerebral infarction in the left central region. B: Single photon emission computed tomography scans with technetium-99m hexamethylpropyleneamine oxime revealing decreased perfusion only in the focal region corresponding to the hyperintense signal on the FLAIR images.

aphasia by the following morning, and could not react to any vocal or gestural orders. T₂-weighted and fluid-attenuated inversion recovery (FLAIR) magnetic resonance imaging showed hyperintense areas in the cortico-subcortical region of the left frontoparietal lobe (Fig. 3A). Single photon emission computed tomography (SPECT) with technetium-99m hexamethylpropyleneamine oxime showed an obvious decrease in perfusion in the areas appearing hyperintense on FLAIR images (Fig. 3B). We promptly initiated anticoagulation with administration of 15,000 units/day of heparin and 60 mg/day of edaravone to prevent further cerebral infarctions.

On the third day after admission, we planned to repeat cerebral DSA and prepared to perform indicated endovascular treatment. DSA clearly demonstrated partial antegrade blood flow in the ICA from the point of occlusion on the day of admission, and also partially visualized the distal middle cerebral artery. We repeatedly attempted to perform endovascular trapping for the ICA around the injured portion. We finally accomplished complete obliteration of the left ICA (Fig. 4).

Immediately after endovascular intervention, the patient was transferred to the operation room. Under general anesthesia, the nail was safely removed without problematic bleeding (Fig. 5) by a team including an otolaryngological surgeon and an oral and maxillofacial

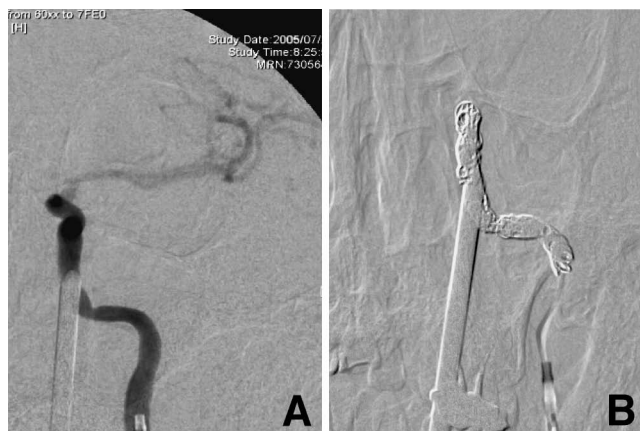

Fig. 4 Pre- (A) and post-embolization (B) anteroposterior left internal carotid arteriograms showing the antegrade flow to the top of the internal carotid artery (ICA) from the occluded point is clearly recanalized (A), and the middle cerebral artery can also be identified (A). Coil embolization of the ICA around the stenotic portion was performed to obliterate the blood flow (B).

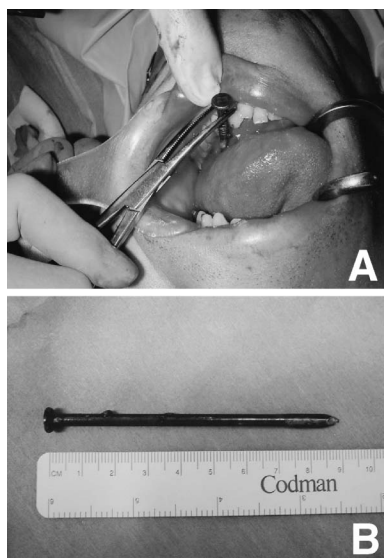


Fig. 5 Photographs showing the nail pulled out from under the tongue (A). This nail was 9 cm in length (B).

surgeon. Throughout this course of treatment, the patient suffered no additional deficit, and his sensory aphasia and right hemiparesis gradually improved.

Discussion

In the present case, the nail that was accidentally driven into the lower jaw unfortunately reached the foramen lacerum, but without perforating the ICA, and caused unstable stenosis of the ICA resulting in delayed cerebral infarction. Endovascular trapping of the ICA allowed us to remove the nail safely and also prevented further progression of the cerebrovascular events related to the injured

ICA. There is no clear consensus regarding the timing and method to treat such traumatic ICA injuries because of variations in their status and injury pattern, and the individual dynamics of cerebral circulation. We performed various evaluations to assess the injury and the patient's status as exactly as possible on admission. However, the cerebral infarction of the left frontoparietal lobe occurred on the day after admission. We speculate that the mechanism underlying this event was an artery-to-artery embolism originating from the stenotic portion. The thrombus was presumably formed distal to the angiographically occluded site of the ICA. Resumption of distal blood flow after revascularization due to movement of the nail accompanying movement of the lower jaw carried the thrombus to the distal vessels. Similar repeated cerebral infarctions were observed in a patient with a craniofacial screw injury.³⁾ Considering the occurrence of such delayed events, if the patient has any traumatic obstruction to the ICA resulting from a craniofacial penetrating injury, we recommend that the obstruction be treated rapidly after necessary investigations are performed. The timing of anticoagulant administration for such patients is controversial. We observed the patient's status without anticoagulants on the first day because of the risk of hemorrhagic events caused by the carotid injury. However, anticoagulant administration may be the optimum choice after initial diagnosis to prevent subsequent events.

Complications of ICA injuries, such as perforation of the ICA, pseudoaneurysm formation, dural arteriovenous fistula, carotid-cavernous fistula, fatal epistaxis, subarachnoid hemorrhage, and intracerebral hemorrhage, are well known to lead to posttraumatic neurological deficits.^{2,4,5,7,9,13,15)} Pseudoaneurysms that rupture after head injuries are associated with particularly high rates of mortality of 32–54%.^{5,9)} In the present case, we performed endovascular trapping of the ICA to remove the nail safely and also to prevent fatal bleeding and other complications such as pseudoaneurysm formation and traumatic carotid-cavernous fistula. We planned to remove the nail after coil embolization of the ICA from the distal to proximal sites of the obstructed portion. Cerebral aneurysm formation or growth may occur after trapping of the ICA.⁸⁾ Our patient will require careful long-term observation.

From the technical aspect, the proximal occlusion balloon catheter was used to control the blood flow in case of unexpected bleeding from the ICA during the procedure. The absence of neurological deficits on admission, when the ICA was almost occluded on DSA, the apparently adequate collateral circulation by cross flows through the AcomA and PcomA on DSA, and the limited focal decrease in perfusion at the region corresponding to obvious infarction on SPECT were considered to be favorable indicators of the patient's tolerance for ICA trapping. If poor collateral circulation is suspected, acetazolamide SPECT should be performed to confirm the residual capacity for cerebrovascular perfusion, and then ICA trapping may be performed after the appropriate bypass surgery. Although catheterization through the severely stenotic portion was possible in the present case, we generally manipulate the microcatheter and microguidewire via

the AcomA or PcomA into the distal ICA in more difficult cases.

Direct surgical trapping of the ICA or endovascular treatment with a covered stent^{11,12,14,16)} are other proposed treatment options. Surgical trapping of the ICA is the most successful method to occlude the ICA, but would have been extremely invasive in the present patient. Surgical trapping necessitates double ligation of the ICA at the cervical portion and at the proximal portion to the ophthalmic artery using permanent clipping via left pterional craniotomy. Recently, repair or reinforcement of the injured ICA with a covered stent has been attempted for lesions in the skull base and in the intracranial vasculature,¹⁴⁾ following the first report of autologous vein-covered stent repair of a cervical ICA pseudoaneurysm.¹¹⁾ Although this new technique would result in adequate restoration of the circulation in the ipsilateral ICA, embolic side effects may occur inside the stent. Therefore, this treatment is suitable for blunt injury of the ICA, but not penetrating injury. This distinction was obscure in the present case. Acute injury of the ICA should possibly not be manipulated within 48 to 72 hours of the event and endovascular stents placed in traumatized arteries require full systemic anticoagulation.⁵⁾

The treatment strategy for craniofacial penetrating injury involving the ICA should be determined for each patient based on the advantages and disadvantages of individual therapies, but we suggest that the wait and watch strategy is not ideal in the acute phase.

References

- 1) Al-Mefty O, Holoubi A, Fox JL: Value of angiography in cerebral nail-gun injuries. *AJNR Am J Neuroradiol* 7: 164-165, 1986
- 2) Auyeung KM, Lui WM, Chow LC, Chan FL: Massive epistaxis related to petrous carotid artery pseudoaneurysm after radiation therapy: emergency treatment with covered stent in two cases. *AJNR Am J Neuroradiol* 24: 1449-1452, 2003
- 3) Bogaerde VB, Viaene P, Thijs V: Iatrogenic perforation of the internal carotid artery by a transarticular screw: an unusual case of repetitive ischemic stroke. *Clin Neurol Neurosurg* 109: 466-469, 2007
- 4) Braun J, Gdal-On M, Goldsher D, Borovich B, Guilburd JN: Traumatic carotid aneurysms secondary to cavernous sinus penetration by wood: CT features. *J Comput Assist Tomogr* 11: 525-528, 1987
- 5) Briffell WL, Moore EE, Offner PJ, Brega KE, Franciose RJ, Burch JM: Blunt carotid arterial injuries: implications of a new grading scale. *J Trauma* 47: 845-853, 1999
- 6) Centers for Disease Control and Prevention (CDC): Nail-gun injuries treated in emergency departments—United States, 2001-2005. *MMWR Morb Mortal Wkly Rep* 56: 329-332, 2007
- 7) Coley SC, Pandya H, Hodgson TJ, Jeffree MA, Deasy NP: Endovascular trapping of traumatic carotid-cavernous fistulae. *AJNR Am J Neuroradiol* 24: 1785-1788, 2003
- 8) Fujiwara S, Fujii K, Fukui M: De novo aneurysm formation and aneurysm growth following therapeutic carotid occlusion for intracranial internal carotid artery (ICA) aneurysms. *Acta Neurochir (Wien)* 120: 20-25, 1993
- 9) Holmes B, Harbaugh RE: Traumatic intracranial aneurysms: a contemporary review. *J Trauma* 35: 855-860, 1993
- 10) Litvack ZN, Hunt MA, Weinstein JS, West GA: Self-inflicted nail-gun injury with 12 cranial penetrations and associated cerebral trauma. Case report and review of the literature. *J Neurosurg* 104: 828-834, 2006
- 11) Marotta TR, Buller C, Taylor D, Morris C, Zwimpfer T: Autologous vein-covered stent repair of a cervical internal carotid artery pseudoaneurysm: technical case report. *Neurosurgery* 42: 408-413, 1998
- 12) Pyun HW, Lee DH, Yoo HM, Lee JH, Choi CG, Kim SJ, Suh DC: Placement of covered stents for carotid blowout in patients with head and neck cancer: follow-up results after rescue treatments. *AJNR Am J Neuroradiol* 28: 1594-1598, 2007
- 13) Raymond J, Hardy J, Czepko R, Roy D: Arterial injuries in transsphenoidal surgery for pituitary adenoma; the role of angiography and endovascular treatment. *AJNR Am J Neuroradiol* 18: 655-665, 1997
- 14) Redekop G, Marotta T, Weill A: Treatment of traumatic aneurysm and arteriovenous fistulas of the skull base by using endovascular stents. *J Neurosurg* 95: 412-419, 2001
- 15) Rezaei AR, Lee M, Kite C, Smyth D, Jafar JJ: Traumatic posterior cerebral artery aneurysm secondary to an intracranial nail: case report. *Surg Neurol* 42: 312-315, 1994
- 16) Saatci I, Cekirge HS, Ozturk MH, Arat A, Ergungor F, Sekerci Z, Senveli E, Er U, Turkoglu S, Ozcan OE, Ozgen T: Treatment of internal carotid artery aneurysms with a covered stent: experience in 24 patients with mid-term follow-up results. *AJNR Am J Neuroradiol* 25: 1742-1749, 2004

Address reprint requests to: Tetsuya Hiraishi, M.D., Department of Neurosurgery, Brain Research Institute, University of Niigata, 1-757 Asahimachidori, Chuou-ku, Niigata, Niigata 951-8585, Japan.
e-mail: tetsuya_hiraishi@me.com