

Hemiparesis and Ischemic Changes of the White Matter After Intrathecal Therapy for Children With Acute Lymphocytic Leukemia

Yung Soon Yim, MD,*† Donald H. Mahoney Jr, MD,*
and Daniel G. Oshman, MD‡

Three children with acute lymphocytic leukemia (ALL) developed delayed-onset transient hemiparesis and facial palsy after intrathecal (IT) administration of methotrexate (MTX) alone or as part of triple intrathecal chemotherapy for central nervous system (CNS) prophylaxis. The hemiparesis developed 10 to 14 days after IT therapy. Two of three children also experienced transient, profound expressive dysarthria. These episodes occurred during maintenance treatment after multiple IT administrations and without previous CNS toxicity. Two of three children received intermediate-dose MTX, 1 g/m², not less than 5 weeks before events. These patients had not received cranial irradiation and had no evidence of CNS leukemia before or after these episodes. Ischemic changes on computerized tomographic scan or magnetic resonance imaging studies were documented in all three cases. Such changes are unusual manifestations of neurotoxicity in children after intrathecal therapy. *Cancer* 67:2058-2061, 1991.

SUCCESSFUL TREATMENT of childhood acute lymphocytic leukemia (ALL) requires therapy directed to the central nervous system (CNS).¹ Intrathecal (IT) therapy with methotrexate (MTX) alone, or in combination with hydrocortisone and cytosine arabinoside as triple intrathecal therapy (TIT) is used widely for control of meningeal leukemia.^{1,2} Various acute and chronic neurologic complications have been associated with this treatment.³⁻⁶ A transient neurologic dysfunction, characterized by hemiparesis, facial nerve weakness, speech disturbance, seizures, and the patient being obtunded has been observed in those who have been treated with high-dose parenteral MTX (doses > 8 to 10 g/m²) with citrovorum rescue.⁷⁻¹⁰ No computed tomography (CT) or magnetic resonance imaging (MRI) evidence of ischemic insult correlating with neurologic manifestations was detected in these patients.

From the *Department of Pediatrics, Hematology-Oncology Service, and the ‡Department of Radiology, Baylor College of Medicine and Texas Children's Hospital, Houston, Texas.

Supported in part by grant CA-03161 from the National Cancer Institute, DHHS, and by a †Clinical Fellowship Award from the American Cancer Society.

Address for reprints: Donald H. Mahoney, Jr, MD, Hematology-Oncology Section, Texas Children's Hospital, 6621 Fannin, MS: 3-289, Houston, TX 77030.

Accepted for publication October 18, 1990.

We report three very similar patients with ALL in remission who experienced transient hemiparesis and dysarthria 10 to 14 days after the administration of IT MTX alone, or TIT, during the course of maintenance therapy. Ischemic lesions corresponding anatomically with the patients neurologic complications were detected by CT or MRI examination.

Case Reports

Case 1

A 12-year-old white boy was diagnosed with non-T, non-B ALL in March 1984. At diagnosis, the patient had no organomegaly. The white blood cell count was 3200/mm³ and the cerebrospinal fluid (CSF) showed normal cytologic features. He achieved complete remission (CR) at the end of induction treatment consisting of weekly vincristine, daily prednisone, and six doses of L-asparaginase. Consolidation consisted of IT MTX 15 mg/m² followed by 4 days of intravenous (IV) MTX 15 mg/m²/day, which was repeated at 2-week intervals for six courses. The maintenance treatment consisted of daily, oral 6-mercaptopurine and weekly, oral MTX, with reinforcement with IT MTX 15 mg/m², and prednisone approximately every 16 weeks.

Eleven days after receiving IT MTX in treatment week 73, he experienced expressive dysarthria and left hemiparesis. Over the next 2 days he began to regain strength and was able to speak clearly. The significance of the clinical finding was not initially appreciated and no neurodiagnostic test or lumbar puncture

was obtained. Left-sided motor strength returned to near normal level within 2 weeks.

In August of 1985, he was transferred to the Hematology-Oncology Service of Texas Children's Hospital (Houston, TX). He continued to receive the same maintenance treatment without IT MTX. A neurologic reevaluation, including CT scan, was obtained approximately 6 months after the episode and demonstrated a lacunar, hypodense region in the right posterior frontal white matter, compatible with an old area of infarction (Fig. 1). He is currently off all therapy and remains in complete clinical remission (CCR) with only minimal weakness on the left side.

Case 2

A 5-year-old east Indian girl was diagnosed with non-T, non-B ALL in June 1984. At presentation the patient had no organomegaly. The leukocyte count was 24,600/mm³ and the CSF showed no evidence of leukemic involvement. She achieved a CR with vincristine and prednisone. She received intramuscular L-asparaginase 6000 U/m²/day for 14 days and two doses of cyclophosphamide 1000 mg/m² at 14-day intervals. She received pulses of TIT with MTX 15 mg/m², hydrocortisone 15 mg/m², and cytosine arabinoside 30 mg/m², and IV MTX 15 mg/m²/day for 4 days at 2-week intervals for six courses. Maintenance treatment consisted of daily oral 6-mercaptopurine, weekly oral MTX, which was reinforced with intermediate-dose IV MTX 1 g/m² and IT MTX 15 mg/m² at 8-week intervals, and 28 days of prednisone at 16-week intervals. Beginning at week 130, the

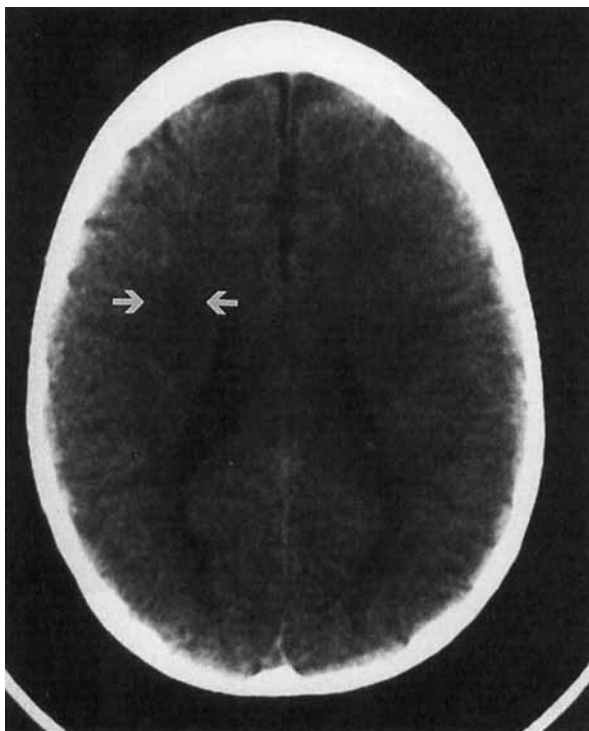


FIG. 1. A CT examination through the superior lateral ventricles demonstrates lucency in posterior frontal white matter consistent with old infarction.

routine CNS prophylaxis schedule was modified to TIT at 8-week intervals, with scheduled doses no earlier than 4 weeks after a course of intermediate-dose MTX.

She was well until 14 days after receiving TIT in week 135 and 42 days after intermediate-dose MTX when she developed sudden onset of right-sided weakness and slurred speech that rapidly progressed to complete right hemiparesis and aphasia. Upon hospitalization, she was alert and responsive but dysarthric. She had right central facial palsy with weakness of right arm and leg. She was not able to stand due to severe right-sided weakness. The CSF showed leukocyte count 1/μl, erythrocyte count 0/μl, protein 22 mg/dl, glucose 45 g/dl with normal cytologic findings. Her initial CT scan was normal. An electroencephalogram (EEG) strongly suggested a cortical lesion. She recovered her speech and motor function by the sixth hospital day.

A MRI 2 weeks after the episode showed a poorly defined region of abnormal signal intensity on T2-weighted imaging in the left centrum semiovale and corona radiata (Fig. 2). Follow-up MRI 4 months from the episode showed a persistent lesion without noticeable change. She completed maintenance treatment without TIT and intermediate-dose MTX in June 1987. She continues to remain CCR without motor or speech disturbance.

Case 3

A 3-year-old white boy was diagnosed with non-T, non-B ALL at age 3 years in December 1985. At presentation the patient had no organomegaly. The leukocyte count was 5300/mm³ and the CSF showed normal cytologic results. He achieved CR with vincristine and prednisone. He received intramuscular L-asparaginase 6000 U/m²/day for 14 days and two doses of cyclophosphamide 1000 mg/m² at a 14-day interval. He also received pulses of TIT followed by IV MTX 15 mg/m²/day for 4 days at 2-week intervals for six courses. Maintenance treatment, thereafter, consisted of daily oral 6-mercaptopurine and weekly intramuscular MTX. Reinforcement consisted of intermediate-dose MTX 1 g/m² and IT MTX 15 mg/m² every 8 weeks and 28 days of prednisone every 16 weeks. Beginning at week 61 of maintenance, the patient's routine CNS prophylaxis program was modified to TIT, administered every 8 weeks, with scheduled doses no earlier than 4 weeks after a course of intermediate-dose MTX.

Ten days after the TIT treatment in week 85, and 38 days after a course of intermediate-dose MTX, he developed right facial weakness, and weakness of the right arm and leg that rapidly progressed to complete hemiparesis. Upon hospitalization, he was drowsy and difficult to arouse. Neurologic examination revealed right central facial palsy, flaccid paralysis of right arm, and weakness in the right leg. He had increased deep tendon reflexes, positive clonus, and a positive Babinski sign on the right side.

The CSF showed leukocyte count 1/μl, erythrocyte count 0/μl, protein 15 mg/dl, glucose 75 g/dl with negative cytologic findings. A CT scan and an EEG within 6 hours of the event showed no focal abnormality. He became alert and responsive within a few hours. He regained strength by the sixth day of hospitalization.

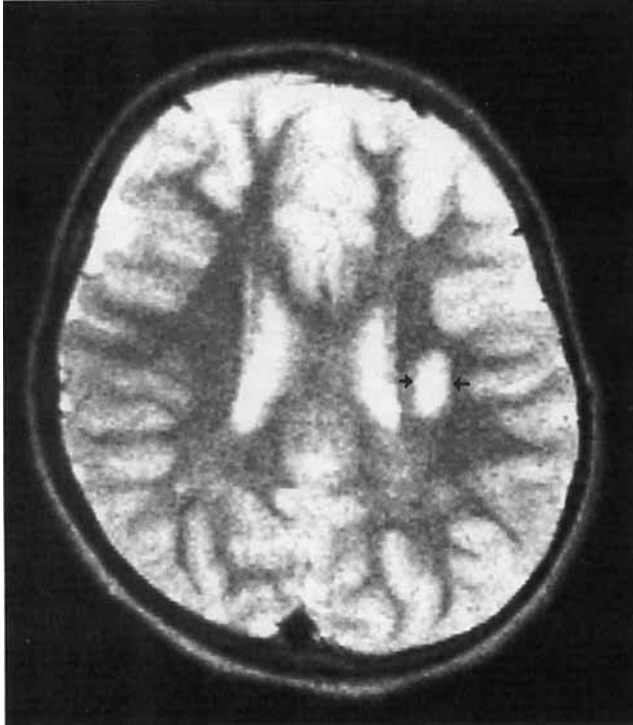


FIG. 2. A MRI image with T-2 weighting demonstrates small, well-defined area of increased signal in the centrum semiovale consistent with an ischemic lesion.

A MRI 10 days after the episode revealed an area of slightly increased spin density and T2 signal in the centrum semiovale on the left side suggestive of an ischemic lesion (Fig. 3). Follow-up MRI 2 months and 27 months after the event continued to show this lesion, and suggested that this may represent a small infarct. The patient has completed maintenance treatment without TIT and intermediate-dose MTX and remains in CCR with minimal weakness of the right upper extremity.

Discussion

Intrathecal MTX alone, as part of TIT, or in combination with irradiation is an essential part of successful CNS preventive therapy for childhood ALL. Neurologic complications may follow such therapy.^{1,2} Three clinical patterns of neurotoxicity have been observed: (1) an acute reaction, occurring within hours of IT chemotherapy, probably resulting from chemical arachnoiditis; (2) subacute toxicity occurring within days or weeks, and characterized by symptoms of seizures, paraparesis, or cerebellum abnormalities; and (3) a delayed leukoencephalopathy form that is more commonly observed when IT MTX is used with cranial irradiation.^{3,4,6}

We report three children who experienced transient, severe hemiparesis and facial nerve palsy 10 to 14 days after IT medication. Two children had a brief but pro-

found dysarthria. Seizure activity was not detected by EEG. The neurologic complications could not be attributed to metabolic, infectious, or leukemic causes. Preservative-free MTX, in Elliott's B solution, was used in preparation of IT medications and no technical difficulties were associated with administration of treatments. The children had no prior history of meningeal leukemia, and previously had received IT therapy without adverse effects. Focal, cortical defects most compatible with an ischemic insult, were documented by neuroimaging examination 2 weeks to 6 months after these transient neurologic dysfunctions. This form of neurologic sequelae rarely complicates IT therapy.

Intrathecal therapy alone as CNS prophylaxis is highly unlikely to produce structural CNS abnormalities.^{6,11} Seizures have been reported to occur in patients after IT MTX,¹² but is most frequent in those patients with meningeal leukemia and/or after cranial irradiation. There is no correlation with structural CNS abnormalities. Reversible and irreversible paraparesis have been reported in children after IT MTX and cytosine arabinoside. This neurotoxicity is uncommon (ten cases in the literature), and results from localized spinal myelopathy.^{13,14} In one case, a fatal encephalomyelopathy followed 24 hours after IT MTX.¹⁵ The use of neurotoxic preservatives in MTX preparations, unphysiologic pH/dilutions of MTX, or the presence of meningeal leukemia have been associated with the majority of these cases. None of these associations were present in our case reports.

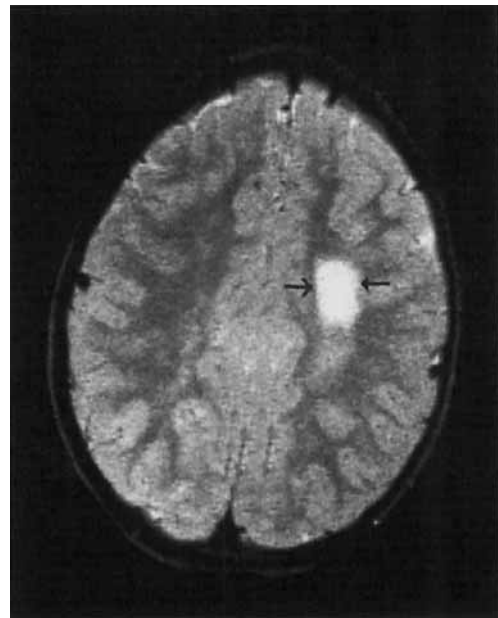


FIG. 3. A MRI image with T-2 weighting demonstrates an area of high signal in the left centrum semiovale. There is no distortion of adjacent white matter.

Transient neurologic dysfunction has followed courses of moderate-dose ($> 2 \text{ g/m}^2$)⁹ and high-dose ($> 8 \text{ g/m}^2$) IV MTX.^{7,8,10} The frequency in osteosarcoma patients receiving high-dose MTX is less than 4%.^{6,10} Symptoms have included hemiparesis, aphasia, cranial nerve palsies, and seizures. The prodromal interval averaged between 7 to 14 days, with a range of up to 50 days. The EEG were abnormal and indicated focal dysfunction. Cranial CT scans and CSF analyses were unremarkable. This form of neurotoxicity has not been reported in children with ALL or lymphoma, receiving moderate-dose or high-dose IV MTX, with or without IT MTX.^{1,6}

Our three patients experienced a transient neurologic dysfunction similar to the above cases. However, the complications were temporally associated with IT chemotherapy; no patient received IV MTX (1 g/m^2) earlier than 38 days before the neurologic complications. Unlike previous reports, our patients had CT or MRI findings of focal cortical injury. In two of three cases, the lesions were best defined by MRI scans performed 10 to 14 days after injury. The abnormalities have persisted on follow-up exams. These focal lesions are not identical to the lesions of leukoencephalopathy as reported in asymptomatic ALL patients who have been treated previously with intrathecal therapy and irradiation or intermediate-dose MTX.¹⁶⁻¹⁸ The focal cortical injuries observed in our cases suggest an ischemic or stroke-like insult. L-asparaginase therapy has been associated with thrombotic strokes.¹⁹ However, our patients had not received L-asparaginase recently. DiMario and Packer reported stroke syndromes in four of 31 patients with ALL presenting with acute mental status changes during the course of therapy. One of four patients had received IT MTX and had toxic levels of CSF MTX 8 days after administration. Neuroimaging studies were not performed.²⁰

In summary, transient neurologic dysfunction characterized by hemiparesis and dysarthria, and associated with ischemic insults to cortical white matter can be a rare complication of IT therapy. Patients presenting with similar symptoms 10 to 14 days after IT therapy should undergo a MRI examination to exclude possible ischemic CNS injury. Discontinuation of presymptomatic IT therapy should be considered for patients experiencing this neurologic complication.

REFERENCES

1. Bleyer WA, Poplack DA. Prophylaxis and treatment of leukemia in the central nervous system and other sanctuaries. *Semin Oncol* 1985; 12:131-148.
2. Crist W, Boyett L, Frankel R et al. Extended triple intrathecal chemotherapy (TIC) is highly effective and superior to brief TIC and intermediate-dose MTX as CNS prophylaxis in non-T, non-B ALL: A Pediatric Oncology Group study (Abstr). *Med Pediatr Oncol* 1988; 16:387.
3. Pochedly C. Neurotoxicity due to CNS therapy for leukemia. *Med Pediatr Oncol* 1977; 3:101-115.
4. Bleyer WA. Neurologic sequelae of methotrexate and ionizing radiation: A new classification. *Cancer Treat Rep* 1981; (Suppl) 65:88-89.
5. Pizzo P, Poplock D, Bleyer W. Neurotoxicities of current leukemia therapy. *Am J Pediatr Hematol Oncol* 1979; 1:127-138.
6. Ochs JJ. Neurotoxicity due to central nervous system therapy for childhood leukemia. *Am J Pediatr Hematol Oncol* 1989; 11:93-105.
7. Packer RJ, Grossman RI, Belasco JB. High-dose systemic methotrexate associated neurological dysfunction. *Med Pediatr Oncol* 1983; 11:159-161.
8. Jaffe N, Takaue Y, Anzai T, Robertson R. Transient neurologic disturbance induced by high-dose methotrexate treatment. *Cancer* 1985; 56:1356-1360.
9. Martino RL, Benson AB, Merritt JA et al. Transient neurologic dysfunction following moderate-dose methotrexate for undifferentiated lymphoma. *Cancer* 1984; 54:2003-2005.
10. Rosen G, Marcove RC, Caparros B et al. Primary osteogenic sarcoma: The rationale for preoperative chemotherapy and delayed surgery. *Cancer* 1979; 43:2163-2177.
11. Ochs JJ, Berger P, Brecher ML et al. Computed tomography brain scans in children with acute lymphocytic leukemia receiving methotrexate alone as central nervous system prophylaxis. *Cancer* 1980; 45:2274-2278.
12. Ochs J, Bowman WP, Pui C et al. Seizures in childhood lymphoblastic leukemia patients. *Lancet* 1984; 2:1422-1424.
13. Gagliano R, Costanzi J. Paraplegia following intrathecal methotrexate. *Cancer* 1976; 37:1663-1668.
14. Wolff L, Zigelboim J, Gale RP. Paraplegia following intrathecal cytosine arabinoside. *Cancer* 1979; 43:83-85.
15. Skullerud K, Halvorsen K. Encephalomyelopathy following intrathecal methotrexate treatment in a child with acute leukemia. *Cancer* 1978; 42:1211-1215.
16. Peyland-Ramu N, Poplack DG, Pizzo PA et al. Abnormal CT scans of the brain in asymptomatic children with acute lymphocytic leukemia after prophylactic treatment of the central nervous system with radiation and intrathecal chemotherapy. *N Engl J Med* 1978; 298:815-818.
17. Ochs JJ, Parvey LS, Whitaker JN et al. Serial cranial computed-tomography scans in children with leukemia given two different forms of central nervous system therapy. *J Clin Oncol* 1983; 1:793-799.
18. Allen JC, Rosen GR, Mehta BM, Horten B. Leukoencephalopathy following high-dose IV methotrexate chemotherapy with leukovorin rescue. *Cancer Treat Rep* 1980; 64:1261-1273.
19. Priest JR, Ramsey NKC, Latchaw RE et al. Thrombotic and hemorrhagic stroke complicating early therapy for childhood acute lymphoblastic leukemia. *Cancer* 1980; 46:1548-1554.
20. DiMario FJ, Packer RJ. Acute mental status changes in children with systemic cancer. *Pediatrics* 1990; 85:353-360.