

Intracranial Hemorrhage Associated With Convexity Meningioma After Cerebral Angiography

—Case Report—

Yoshiteru MIYAJIMA, Hidehiro OKA, Satoshi UTSUKI,
Satoru SHIMIZU, Sachio SUZUKI, and Kiyotaka FUJII

Department of Neurosurgery, Kitasato University School of Medicine, Sagamihara, Kanagawa

Abstract

A 63-year-old female developed left hemiparesis caused by intracranial intratumoral and peritumoral hemorrhage with cerebral herniation 4 days after cerebral angiography to evaluate right convexity and petrosal meningiomas. The cerebral angiography procedure may have caused the tumoral edema and intracranial hemorrhage because computed tomography on admission revealed the right convexity meningioma as slightly low density compared to before the hemorrhage. Administration of contrast medium is known to cause complications involving microcirculatory collapse and blood-brain barrier dysfunction associated with brain tumors. Therefore, the contrast medium may have affected the meningioma after cerebral angiography.

Key words: intracranial hemorrhage, meningioma, cerebral angiography, side effect, contrast medium

Introduction

Intracranial hemorrhage associated with brain tumor is not uncommon, especially with glioblastoma and metastatic brain tumor. The primary brain tumor most associated with hemorrhage is oligodendroglioma with an incidence of 14.3%, but which increases to 29.2% in the mixed type.⁵⁾ The incidence of hemorrhage is 15.8% for pituitary adenoma.¹¹⁾ The incidence of hemorrhage for metastatic brain tumors is 3% overall,¹¹⁾ but the most hemorrhagic tumor is melanoma, with an incidence of 35.7%.⁵⁾ In contrast, the incidence of hemorrhage with meningioma ranges from 0.5%–2.4%,^{4,5)} reported as acute subdural hematoma, chronic subdural hematoma,⁸⁾ and subarachnoid hemorrhage.⁶⁾

We treated a 63-year-old woman with severe intratumoral and peritumoral hemorrhage from a convexity meningioma who required emergency surgery for cerebral herniation 4 days after cerebral angiography.

Case Report

A 63-year-old female experienced a falling episode in January 2005. She consulted a physician and was found to have convexity and petrosal meningiomas. She could walk unaided in spite of her hemiparesis, had no disturbance of consciousness, cognitive impairment, or coagulation disorder, and was not taking anticoagulant medication in June 2005. Computed tomography revealed tumors as

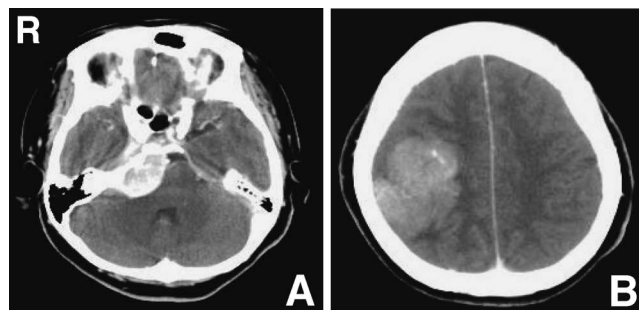


Fig. 1 Computed tomography scans with contrast medium showing right petrosal (A) and convexity meningiomas (B).

slightly high density compressing the surrounding parenchymal tissue. The tumors were located in the right convexity and the petrosal region, and computed tomography with contrast medium revealed tumor enhancement (Fig. 1). The diagnosis was convexity and petrosal meningiomas.

The patient was taken to our hospital for preoperative angiography on June 2, 2005. Cerebral angiography revealed that the right middle meningeal artery and internal carotid artery fed the petrosal meningioma, and the right middle meningeal artery and middle cerebral artery fed the upper one third and lower two thirds of the convexity meningioma, respectively. The middle cerebral artery which fed the convexity meningioma was shifted downward (Fig. 2). These findings are typical of meningioma.

The angiography procedure included administration of iopamidol 75 ml (Iopamiron 300; Bayer AG, Leverkusen, Germany) as a contrast agent and heparin sodium 1500 units. She was discharged from our hospital without incident on June 4, 2005.

Soon after discharge, she suffered sudden onset of severe headache and loss of consciousness while watching television. On admission, she was semi-comatose with a systolic blood pressure of 220 mmHg, anisocoria (rt>lt), and complete left hemiplegia. Computed tomography revealed intratumoral and peritumoral hemorrhages associated with the low density convexity meningioma (Fig. 3).

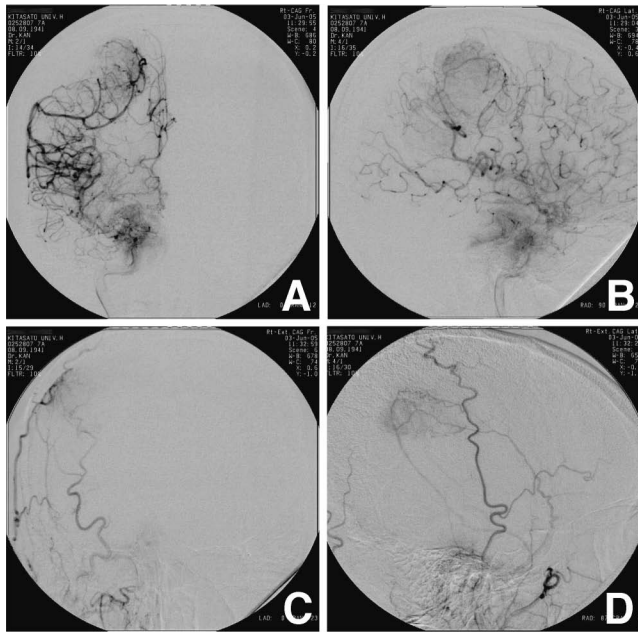


Fig. 2 Right internal carotid angiograms, anteroposterior view (A) and lateral view (B), showing the middle cerebral artery compressed downward, and contributing to the blood supply of the medial-inferior two thirds of the convexity meningioma. Right external carotid angiograms, anteroposterior view (C) and lateral view (D), showing the middle meningeal artery contributing to the blood supply of one third of the convexity meningioma.

She underwent emergency surgery to remove the tumor and hematoma, and decompression craniotomy. No subdural hematoma or subarachnoid hemorrhage was found at craniotomy. The bleeding from the tumor was stopped by blocking the branches of the middle cerebral artery which were feeding the tumor. Histological examination revealed transitional type meningioma.

The patient gradually regained consciousness and could carry on a simple conversation, but hydrocephalus and hemiparesis persisted. Thereafter, she underwent surgery for the placement of a ventriculoperitoneal shunt on August 11, and cranioplasty on August 23. She was discharged from our hospital with hemiparesis.

Discussion

The present case of meningioma was associated with both intratumoral and peritumoral hemorrhages. Hemorrhage associated with meningioma after cerebral angiography has not been described previously. Presumably the hemorrhage with meningioma was caused by collapse of the fragile arteries feeding the meningioma and draining vein,^{1,3)} resulting in hemorrhagic infarction of the tumor.^{1,3,7)} Since the hematoma was in the same location as the abnormal vascular network feeding the medial-inferior two thirds of the convexity meningioma, this abnormal vascular network was suspected of being the bleeding point (Fig. 4). Moreover, bleeding from the meningioma at operation was stopped by blocking a branch of the middle cerebral artery feeding the convexity meningioma.

Since the hemorrhage occurred 4 days after cerebral angiography was performed, the hemorrhage was probably caused by the cerebral angiography procedure. Four possible mechanisms of hemorrhage following cerebral angiography can be considered: Coagulopathy caused by heparin administration; intratumoral infarction caused by thrombosis induced by cerebral angiography; intratumoral infarction caused by microvascular failure induced by the contrast medium; and contrast medium-related osmotic changes acting on the fragile microvascular network of the tumor-associated circulation. The first mechanism is irrelevant, because the hemorrhage occurred 4 days after the cerebral angiography, and the half-

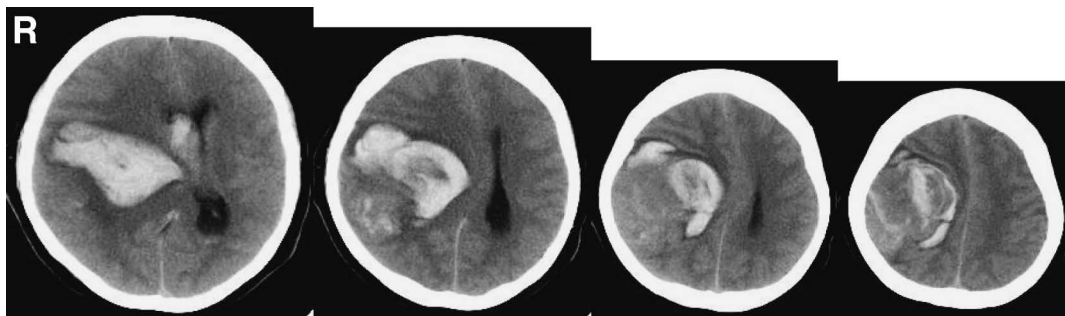


Fig. 3 Computed tomography scans showing a hematoma located inside and outside of the tumor, and intraventricular hemorrhage without subarachnoid or subdural hematoma.

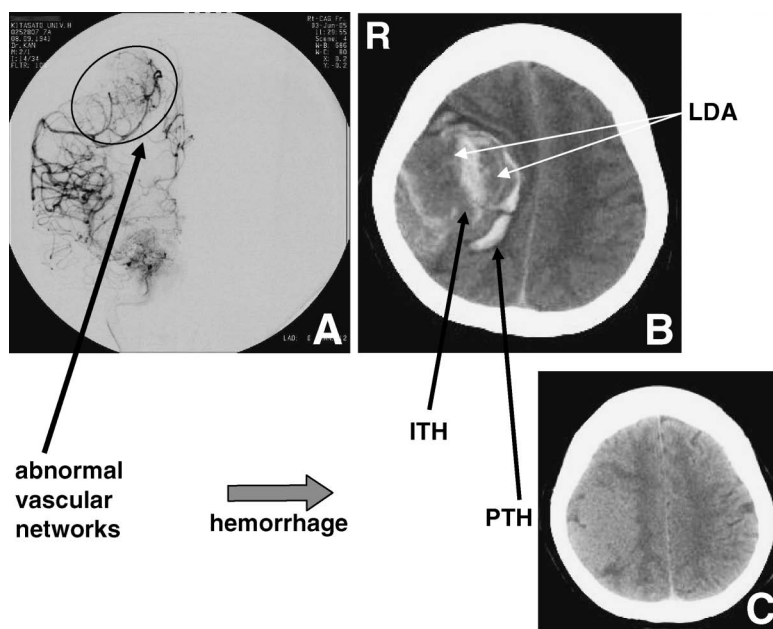


Fig. 4 Right internal carotid angiogram, anteroposterior view (A), showing the middle cerebral artery contributing to the supply of the lower two thirds of the convexity meningioma. The location of the abnormal vascular network from the middle cerebral artery is in accordance with the hematoma. Computed tomography scans showed the tumor as less dense after hemorrhage (B) than before hemorrhage (C), suggesting intratumoral infarction. We assumed that the bleeding point was the abnormal vascular network. ITH: intratumoral hematoma, LDA: low density area, PTH: peritumoral hematoma.

time of the heparin natrium is an hour. Intracranial hemorrhage associated with meningioma after embolization is reported to be caused by proximal pulsation within 10 hours after occlusion of the vascular networks.²⁾ Since this hemorrhage occurred 4 days after cerebral angiography, the second mechanism is unlikely. In addition, angiography did not seem to be the direct cause in this case.

The effect of contrast medium on brain tumor is unclear. Brain tumors which are enhanced strongly are highly affected by the high osmotic pressure of the contrast medium because of blood-brain barrier dysfunction. High osmotic pressure induced by contrast medium may have deleterious effects. For example, computed tomography after coil embolization for a ruptured aneurysm revealed that enhanced brain tissue and edema, with resultant neurological deficit.¹⁰⁾ In addition, intratumoral hemorrhage has occurred in a pituitary adenoma after cerebral angiography.⁹⁾ Presumably cell achesis, tearing of the tight junctions, circulatory collapse of the microvascular elements, and vascular spasm are precipitated by the high osmotic pressure of the contrast medium. Therefore, the high osmotic pressure of the contrast medium could affect the meningioma through blood-brain barrier dysfunction in part of the brain tumor, resulting in strong enhancement and brain edema. In the present case, we speculate that the intratumoral and peritumoral hemorrhage associated with the meningioma originated from collapse of the abnormal microvascular networks stretched by the swelling tumor volume, and precipitated by the high circulatory osmotic pressure.

The present case of intracranial hemorrhage associated with meningioma after cerebral angiography was presumably caused by the effect of the high osmotic pressure of the contrast medium on the meningioma through blood-brain barrier dysfunction, resulting in enhancement of part of the tumor and brain edema. However, this conclusion has no theoretical basis. This case illustrates the necessity to consider the risks associated with cerebral angiography when performing evaluations of meningiomas.

Acknowledgments

This work was supported in part by Grants-in-Aid for Scientific Research from the Ministry of Education (Nos. 10877218, 13671462, and 19591700) and a Parent's Association Grant from Kitasato University, School of Medicine, Japan.

References

- 1) Bosnjak R, Derham C, Popovic M, Ravnik J: Spontaneous intracranial meningioma bleeding: clinicopathological features and outcome. *J Neurosurg* 103: 473-484, 2005
- 2) Kallmes DF, Evans AJ, Kaptain GJ, Mathis JM, Jensen ME, Jane JA, Dion JE: Hemorrhagic complications in embolization of a meningioma: case report and review of the literature. *Neuroradiology* 39: 877-880, 1997
- 3) Kim DG, Park CK, Paek SH, Choe GY, Gwak HS, Yoo H, Jung HW: Meningioma manifesting intracerebral haemorrhage: a possible mechanism of haemorrhage. *Acta Neurochir (Wien)* 142: 165-168, 2000
- 4) Kohli CM, Crouch RL: Meningioma with intracerebral

- hematoma. *Neurosurgery* 15: 237-240, 1984
- 5) Kondziolka D, Bernstein M, Resch L, Tator CH, Fleming JF, Vanderlinden RG, Schutz H: Significance of hemorrhage into brain tumors: clinicopathological study. *J Neurosurg* 67: 852-857, 1987
 - 6) Latchaw JP Jr, Dohn DF, Hahn JF, von der Luft E: Subarachnoid hemorrhage from an intracranial meningioma. *Neurosurgery* 9: 433-435, 1981
 - 7) Martinez-Lage JF, Poza M, Martinez M, Esteban JA, Antunez MC, Sola J: Meningiomas with haemorrhagic onset. *Acta Neurochir (Wien)* 110: 129-132, 1991
 - 8) Okuno S, Touho H, Ohnishi H, Karasawa J: Falx meningioma presenting as acute subdural hematoma: case report. *Surg Neurol* 52: 180-184, 1999
 - 9) Suga T, Kagawa S, Goto H, Yoshioka K, Hosoya T: [A case of pituitary adenoma progressing to pituitary apoplexy on the occasion of cerebral angiography]. *No Shinkei Geka* 24: 475-479, 1996 (Jpn, with Eng abstract)
 - 10) Uchiyama Y, Abe T, Hirohata M, Tanaka N, Kojima K, Nishimura H, Norbash AM, Hayabuchi N: Blood brain-barrier disruption of nonionic iodinated contrast medium following coil embolization of a ruptured intracerebral aneurysm. *AJNR Am J Neuroradiol* 25: 1783-1786, 2004
 - 11) Wakai S, Yamakawa K, Manaka S, Tamaqua K: Spontaneous intracranial hemorrhage caused by brain tumor: its incidence and clinical significance. *Neurosurgery* 10: 437-444, 1982

Address reprint requests to: Yoshiteru Miyajima, M.D., Department of Neurosurgery, Kitasato University School of Medicine, 1-15-1 Kitasato, Sagamihara, Kanagawa 228-8555, Japan.
e-mail: y_miya@fc4.so-net.ne.jp