


# Ischemic Stroke in a 7-Month-Old Infant With Antiphospholipid Antibody and Homozygous C677T Methylenetetrahydrofolate Reductase (MTHFR) Polymorphism

Journal of Child Neurology  
25(8) 1047-1050  
© The Author(s) 2010  
Reprints and permission:  
sagepub.com/journalsPermissions.nav  
DOI: 10.1177/0883073809356710  
http://jcn.sagepub.com  


Se Hee Kim, MD,<sup>1</sup> Hee Hwang, MD,<sup>1</sup> Jong Hee Chae, MD, PhD,<sup>1</sup>  
Ki Joong Kim, MD, PhD,<sup>1</sup> Yong Seung Hwang, MD, PhD,<sup>1</sup> and  
Byung Chan Lim, MD<sup>1</sup>

## Abstract

Prothrombotic risk factors in children with ischemic stroke have been increasingly recognized with recent developments in technology. Extensive evaluation including a detailed family history is required to identify various inherited or acquired prothrombotic conditions. We report a 7-month-old male who presented with right hemiparesis. Acute cerebral infarction in the area supplied by the left lenticulostriate artery was confirmed through magnetic resonance imaging. De novo synthesis of antiphospholipid antibodies and homozygous methylenetetrahydrofolate reductase (MTHFR) polymorphism were identified as presumed prothrombotic risk factors. His twin sister and mother were also positive for antiphospholipid antibodies. Multiple risk factors for ischemic stroke should be considered, particularly in the perinatal and infancy period. This case also underlines the rare familial occurrence of antiphospholipid antibodies and its relationship to ischemic stroke in infancy.

## Keywords

infant, stroke, risk factor, antiphospholipid antibody, methylenetetrahydrofolate reductase

Received October 29, 2009. Received revised November 8, 2009. Accepted for publication November 9, 2009.

The risk factors of ischemic stroke in the pediatric age group are poorly understood compared with those for adults, which comprise atherosclerosis, hypertension, diabetes, hypercholesterolemia, and smoking. In addition to a few well-known risk factors, such as congenital heart disease and arteriopathies resulting from dissection or certain infections,<sup>1</sup> various prothrombotic factors are increasingly being recognized as playing an important role in ischemic stroke in children.<sup>2-4</sup>

Here, we report a 7-month-old male who presented with right-sided hemiparesis. Two prothrombotic risk factors were identified after extensive evaluation: native antiphospholipid antibodies and homozygous methylenetetrahydrofolate reductase (MTHFR) C677T polymorphism. His mother and twin sister were also positive for antiphospholipid antibodies, suggesting familial occurrence.

## Case Report

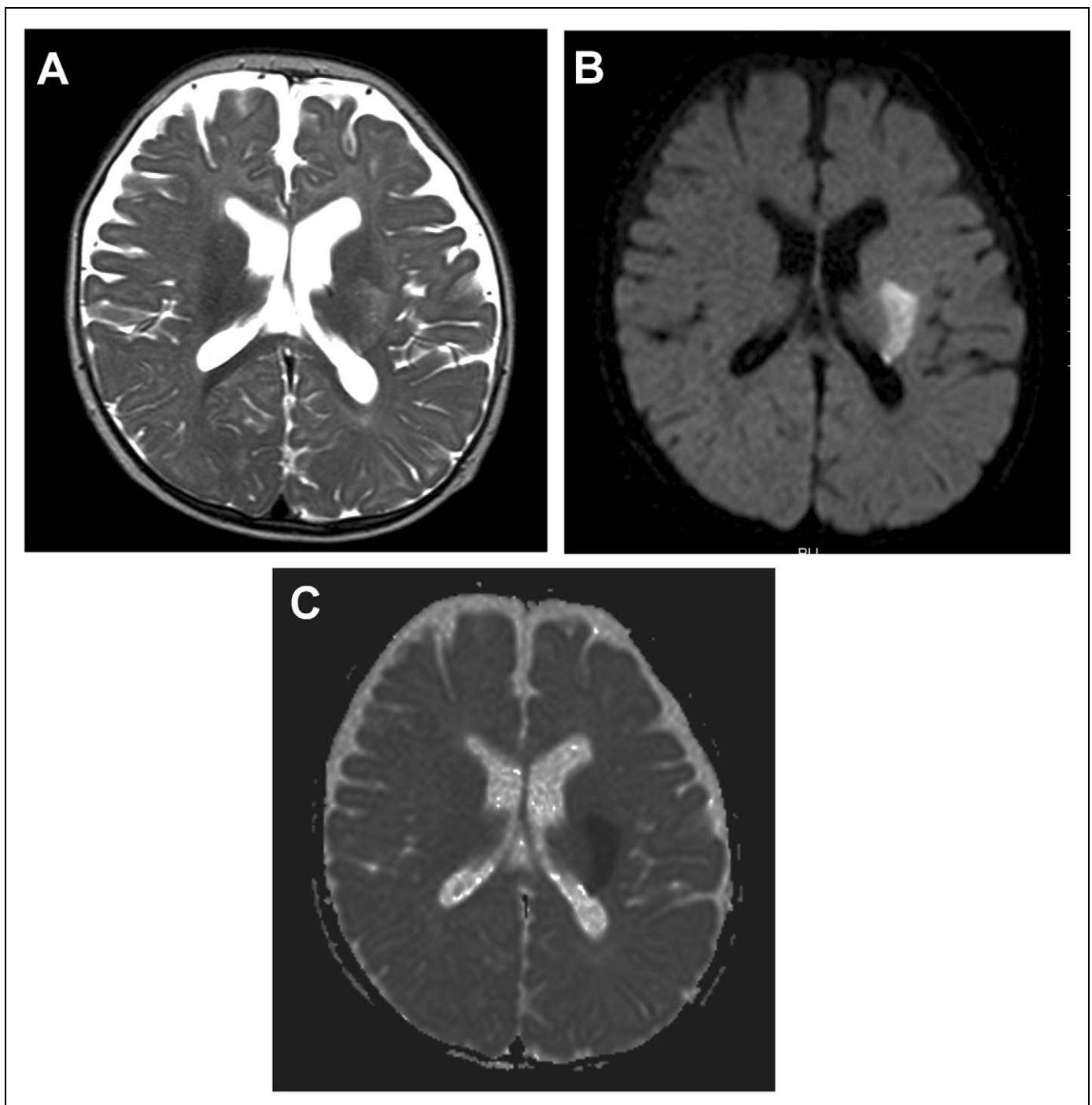
A 7-month-old male was admitted because of a right-sided weakness, which had begun 2 hours before his admission. He was a natural discordant twin born second at a gestational age of 35 weeks and 3 days. He was born from an emergency cesarean section because of placenta totalis and without any

perinatal events. His developmental milestones were normal. His mother had a history of 1 intrauterine fetal death at 8 weeks of gestation. He had no history of chickenpox infection. Three family members within 3 generations on the maternal side (maternal grandfather and maternal great-grandparents) suffered from stroke. The maternal grandfather died of stroke in his 30s. A neurological examination was conducted on his arrival and revealed a right-sided hemiparesis including facial muscles with a decreased muscle strength of grade 3. Deep-tendon reflexes were increased, and the Babinski reflex was present on the right side. He was alert, and the remainder of his neurological examination results was normal. No other physical abnormalities were noted.

Department of Pediatrics, Seoul National University College of Medicine, Seoul, Korea

## Corresponding Author:

Byung Chan Lim, Department of Pediatrics, Seoul National University College of Medicine, Seoul National University Hospital, 28 Yongon-Dong, Jongno-Gu, Seoul, 110-744, Korea  
Email: prabbit@medimail.co.kr



**Figure 1.** Magnetic resonance imaging of the patient at the onset. (A) Axial T2-weighted image demonstrating subtle high-signal intensity in the left putaminal area and posterior limb of the internal capsule. Diffusion-weighted imaging (B) and apparent diffusion coefficient mapping (C) demonstrating the presence of diffusion restriction in the same area.

Brain magnetic resonance imaging conducted on the day of admission showed a subtle high-signal intensity in the left putaminal area and the posterior limb of the internal capsule on T2-weighted images (Figure 1A) and diffusion restriction in the same area, as demonstrated by the presence of hyperintensity on diffusion-weighted imaging (Figure 1B) and depressed apparent diffusion coefficient mapping (Figure 1C).

These observations were compatible with acute lenticulostriate artery infarction. No stenosis or occluded area was noted on magnetic resonance angiography. An echocardiogram finding was normal. Various prothrombotic risk factors were evaluated: anticardiolipin antibody, lupus anticoagulant, protein C, protein S, antithrombin III, serum homocysteine, lipoprotein (a), factor V Leiden mutation, MTHFR polymorphism

**Table 1.** Profile of Antiphospholipid Antibodies and Methylenetetrahydrofolate Reductase (MTHFR) Polymorphism in Patient, Twin Sister, and Mother

	Patient (7 mo, 10 mo)	Twin Sister (10 mo)	Mother
Anticardiolipin IgG antibody (<15 IgG phospholipid or GPL)	21.8, 18.9	34	Negative
Anticardiolipin IgM antibody (<12.5 IgM phospholipid or MPL)	Negative, 12.6	32.1	Negative
Lupus anticoagulant	Negative	Negative	Weakly positive
MTHFR C677T	TT homozygote	CT heterozygote	CT heterozygote
MTHFR A1298C	AA homozygote	AC heterozygote	AC heterozygote

(C677T, A1298C), and prothrombin G20210A mutation. Two prothrombotic risk factors were identified: anticardiolipin antibody IgG was mildly elevated, and anticardiolipin antibody IgM was negative. MTHFR genotyping revealed homozygous MTHFR C677T polymorphism. The anticardiolipin antibody IgG remained elevated, and anticardiolipin antibody IgM was detected at borderline levels when re-evaluated after 14 weeks. The patient's twin sister and mother were also evaluated. The anticardiolipin antibody IgG and anticardiolipin antibody IgM were elevated in the twin sister, and lupus anticoagulant was positive in his mother. Specific data for the patient, his twin sister, and mother are presented in Table 1.

Antithrombotic treatment was not started immediately because there was a small acute hemorrhage around the infarction area. After the hemorrhage spontaneously resolved, the patient was prescribed with aspirin and physical therapies. After a 6-month follow-up period, his right-side muscle strength had improved, and no further attacks had occurred.

## Discussion

Although the presence of antiphospholipid antibodies was recognized as a risk factor for ischemic stroke in children in a previous study,<sup>2</sup> the evaluation of its clinical significance in the context of pediatric ischemic stroke remains poor, mainly because of the relatively low incidence of pediatric antiphospholipid syndrome and the lack of sufficient multicenter data. Moreover, ischemic stroke accounts for only about 30% of thrombotic events in pediatric antiphospholipid syndrome.<sup>5</sup> The role of antiphospholipid antibodies in ischemic stroke has been more actively studied in the perinatal-onset group because these antibodies can be transferred transplacentally from the mother with antiphospholipid antibodies, or antiphospholipid syndrome, possibly affecting the prothrombotic status of the fetus and neonate. A recent well-designed clinical study,<sup>6</sup> review,<sup>7</sup> and case report<sup>8</sup> support the related risk of antiphospholipid antibodies. However, these studies also point out that other comorbid prothrombotic conditions are usually required for ischemic stroke to occur. The clinical presentation of our patient with homozygous MTHFR C677T polymorphism in addition to antiphospholipid antibodies supports this concept that multiple prothrombotic risk factors are required for ischemic stroke. However, it is not clear whether the antiphospholipid antibodies were transferred from his mother or synthesized de novo, considering that the onset of the stroke

was beyond the perinatal period. The abortion history of the mother and several stroke episodes in 3 members on the maternal side of the family raise the suspicion that there might be an inherited factor in addition to the passive transfer of antiphospholipid antibodies. The results of repeated testing of the patient at 10 months of age plus the presence of prothrombotic risk factors in the patient's twin sister and mother favored the de novo synthesis of antiphospholipid antibodies. The presence of different antiphospholipid antibodies in the infants and mother requires some speculation. One family study revealed a high prevalence of various antiphospholipid antibodies in the family members of patients with antiphospholipid syndrome, which were not necessarily the same as those seen in patients.<sup>9</sup> De novo synthesis of antiphospholipid antibodies in preterm newborns from mothers with antiphospholipid syndrome has also been demonstrated,<sup>10</sup> which suggests that passive transfer of antibodies across the placenta is not the only way fetuses and neonates acquire antiphospholipid antibodies. Therefore, different antiphospholipid antibodies from the mothers can be produced de novo, even during the fetal period. However, it remains to be determined whether the current antibody status of the patient and his twin sister resulted from inheritance of genetic susceptibility to antiphospholipid syndrome or vertical transmission of phospholipid antigens from the mother during gestation. We plan to regularly follow-up the antiphospholipid antibodies status of the patient and his twin sister. If the levels of antiphospholipid antibodies in the patient and his twin sister decrease over time, this would support the hypothesis that a transient immune response might be caused by transient exposure to antigens from the mother during the gestational period.

It is interesting that the patient's twin sister, despite higher titers of antiphospholipid antibodies, remained asymptomatic. She had heterozygous MTHFR C677T polymorphism. It would be interesting to know whether this difference in genotype generates a difference in clinical phenotype. The evidence is insufficient to determine this at present because MTHFR polymorphisms showed an only modestly increased risk for ischemic stroke.<sup>3</sup> However, the concept that multiple prothrombotic factors add to the risk of ischemic stroke is supported by our patient.

The presence of multiple prothrombotic risk factors required the maintenance of antithrombotic treatment in our patient. Although anticoagulation in patients with pediatric antiphospholipid antibody syndrome is associated with lower recurrence of thrombotic events, according to one report,<sup>11</sup> a recent study of 121 patients reported that both anticoagulation

and antiaggregation therapy were used similarly in patients with arterial thrombosis.<sup>5</sup> The MTHFR C677T homozygous state may also require the maintenance of antithrombotic treatment and folate supplementation. Based on the clinical evidence described above, we selected aspirin as the antithrombotic treatment. As the repeated serum homocystein levels were normal (6.2 and 5.2  $\mu\text{mol/L}$ ; reference, 5–15  $\mu\text{mol/L}$ ), we decided not to supplement with folate.

In conclusion, our 7-month-old patient with ischemic stroke highlights the importance of conducting a thorough evaluation of prothrombotic risk factors and family history, with specific emphasis on the familial occurrence of antiphospholipid antibodies in infancy. It would be useful to pay more attention to this age group, although hampered by low prevalence, because infancy may have overlapping clinical features and risk factors with perinatal and later childhood periods.

### Declaration of Conflicting Interests

The authors declared no potential conflicts of interest with respect to the authorship and/or publication of this article.

### Funding

The authors disclosed receipt of the following financial support for the research and/or authorship of this article: This study was supported by a grant of the Korea healthcare technology R&D project, Ministry of Health, Welfare and Family Affairs, Republic of Korea (A080588).

### References

- Bernard TJ, Goldenberg NA. Pediatric arterial ischemic stroke. *Pediatr Clin North Am*. 2008;55:323-338, viii.
- Kenet G, Sadetzki S, Murad H, et al. Factor V Leiden and antiphospholipid antibodies are significant risk factors for ischemic stroke in children. *Stroke*. 2000;31:1283-1288.
- Haywood S, Liesner R, Pindora S, Ganesan V. Thrombophilia and first arterial ischaemic stroke: a systematic review. *Arch Dis Child*. 2005;90:402-405.
- Herak DC, Antolic MR, Krleza JL, et al. Inherited prothrombotic risk factors in children with stroke, transient ischemic attack, or migraine. *Pediatrics*. 2009;123:e653-660.
- Avcin T, Cimaz R, Silverman ED, et al. Pediatric antiphospholipid syndrome: clinical and immunologic features of 121 patients in an international registry. *Pediatrics*. 2008;122:e1100-1107.
- Simchen MJ, Goldstein G, Lubetsky A, et al. Factor V Leiden and antiphospholipid antibodies in either mothers or infants increase the risk for perinatal arterial ischemic stroke. *Stroke*. 2009;40:65-70.
- Boffa MC, Lachassinne E. Infant perinatal thrombosis and antiphospholipid antibodies: a review. *Lupus*. 2007;16:634-641.
- Paro-Panjan D, Kitanovski L, Avcin T. Neonatal antiphospholipid syndrome associated with heterozygous methylenetetrahydrofolate reductase C677T and prothrombin G20210A gene mutations. *Rheumatology (Oxford)*. 2007;46:720-721.
- Goldberg SN, Conti-Kelly AM, Greco TP. A family study of anticardiolipin antibodies and associated clinical conditions. *Am J Med*. 1995;99:473-479.
- Soares Rolim AM, Castro M, Santiago MB. Neonatal antiphospholipid syndrome. *Lupus*. 2006;15:301-303.
- Berkun Y, Padeh S, Barash J, et al. Antiphospholipid syndrome and recurrent thrombosis in children. *Arthritis Rheum*. 2006;55:850-855.