

SHORT COMMUNICATION

A novel neuropsychiatric phenotype of *KCNJ2* mutation in one Taiwanese family with Andersen–Tawil syndrome

Hoi-Fong Chan¹, Meng-Ling Chen², Jen-Jen Su², Li-Chin Ko², Chin-Hsien Lin^{2,3} and Ruey-Meei Wu²

Andersen–Tawil syndrome (ATS) is a rare familial potassium channelopathy characterized by the clinical triad of periodic paralysis, cardiac arrhythmia and dysmorphic facial/skeletal features. The majority of ATS patients are caused by mutations of the *KCNJ2* gene, which encodes the inward-rectifying potassium channel protein Kir2.1. However, the effects of the *KCNJ2* mutation on the central nervous system are rarely studied. In this report, we describe a heterozygous missense mutation (p.Thr192Ile) in the *KCNJ2* gene, which segregates with the disease phenotype in an ATS family. It is noted that in addition to the classical clinical phenotypes of ATS, the index patient exhibited major depression and pyramidal tract signs with diffuse periventricular white matter lesions without contrast enhancement. This mutation and the unusual clinical manifestations observed underscore the phenotypic complexity underlying ATS. Our observations expand the current knowledge of the phenotypic variability of ATS caused by the *KCNJ2* mutation. Patients with ATS, especially those carrying the *KCNJ2* mutations, should be monitored for their potential neuropsychiatric system involvement.

Journal of Human Genetics (2010) 55, 186–188; doi:10.1038/jhg.2010.2; published online 29 January 2010

Keywords: ATS; cardiac arrhythmia; periodic paralysis; Taiwanese; white matter

INTRODUCTION

Andersen–Tawil syndrome (ATS) is a rare autosomal-dominant potassium channelopathy characterized by periodic paralysis, cardiac conduction abnormalities and characteristic facial and skeletal dysmorphic features.¹ The latter included short stature, small head size, ocular hypertelorism, broad nose, low-set ears, cleft palate, mandibular hypoplasia, bilateral transverse palmar creases and clinodactyly of the fifth fingers and toes.¹ It is estimated that ~62% of patients with ATS have mutations in the *KCNJ2* gene on chromosome 17q23, which encodes the pore-forming subunit of an inward-rectifying potassium channel protein, Kir2.1. Mutations in the *KCNJ2* gene cause loss of function and dominant-negative suppression effects on the Kir2.1 protein, which result in reducing the cellular resting membrane potential and disturbing the cardiac and skeletal muscle excitability.²

Although the potassium channel protein Kir2.1 is widely expressed with predominance in the skeletal muscles, heart and brains, the clinical expressivity and severity are variable. In addition, given that the importance of potassium channels in neural development is indisputable, as evidenced by the weaver mouse model, the neuropsychiatric phenotypes of ATS are rarely reported.^{3–5} One recent study showed that patients with mutations in the *KCNJ2* gene are frequently associated with deficits in executive function and abstract reasoning, suggesting that the clinical phenotypes of ATS may involve the central

nervous system (CNS).⁴ In addition, although infantile afebrile seizures were observed in 4 of 23 Japanese ATS patients, it remains unclear why these 4 patients only experienced seizures in infancy.⁵ To further characterize the neuropsychiatric phenotype of ATS, we herein describe a patient with a genetically confirmed *KCNJ2* mutation, who had major depression and diffuse intracranial white matter lesions with pyramidal tracts signs in addition to the clinical triad of ATS.

CASE REPORT

A 35-year-old woman first presented at age 27 with episodic paralysis. The onset of four-limb weakness was acute and progressed to near quadriplegia within 3 days. The duration of each episode was 5–6 days and there were no obvious triggering factors. There was no history of remarkable developmental milestone delay. She had typical ATS facial/skeletal features, including short stature, broad forehead, ocular hypertelorism, small head size, low-set ears, mandibular hypoplasia and clinodactyly of the fifth fingers and toes. Neurological examinations revealed symmetric quadriparesis with proximal muscle group predominance and truncal weakness. It is noted that her deep tendon reflex was hyperreflexia with positive Babinski's sign on the left side. All sensory modality was intact and no fatigability was shown. There were no cranial nerves or cerebellum abnormalities. Laboratory test showed mild hypokalemia ($K=2.7$) and normal thyroid function.

¹Department of Neurology, En Chu Kong Hospital, Taipei, Taiwan; ²Department of Neurology, National Taiwan University Hospital, Taipei, Taiwan and ³Department of Neurology, National Taiwan University Hospital Yun-Lin Branch, Yun-Lin, Taiwan
Correspondence: Dr C-H Lin, Department of Neurology, National Taiwan University Hospital, Yun-Lin Branch, Yun-Lin, Taiwan.
E-mail: q93421022@ntu.edu.tw

Received 16 November 2009; revised 26 December 2009; accepted 28 December 2009; published online 29 January 2010

She regained her muscle power after oral potassium supplement. A 24 h Holter electrocardiography showed transient ventricular bigeminy and prolonged QT interval, which fulfilled the criteria for long-QT syndrome. Series of image analysis were arranged for her positive pyramidal signs. The cervical magnetic resonance image (MRI) was unremarkable, but head MRI showed multiple white matter lesions without gadolinium enhancement in bilateral hemispheres (Figures 1a and b). As the patient did not have any vascular risk factors of atherosclerosis and young age at clinical presentation, lacunar infarcts are unlikely. Further cerebrospinal fluid examination for suspected demyelinating process was refused by the patient. The result of visually evoked potential exam was symmetric and normal. Electroencephalogram (routine and with photic stimulations) showed no epileptiform activity. Peripheral nerve conduction study was arranged for asymmetrical Babinski's sign and the result was normal. Complete neuropsychiatric examination revealed normal intellectual functions. There were no deficits in executive function or abstract reasoning, which was mentioned in the patients with ATS in one previous study, but severe depressed mood was noted.⁴ Suicide ideation and frequent self-injury attempts were noted thereafter. Her case was later diagnosed as major depression at the age of 35 years according to DSM-IV criteria.⁶

Tracing back her family history, her 8-year-old older son is also affected with ATS with the clinical presentation of cardiac long-QT syndrome and characteristic facial/skeletal features. There are no similar white matter lesions on the MRI scan as the proband. However, complete neuropsychiatric test revealed normal intellectual function but borderline decreased executive function, which was

measured by the Trail Making Test. His school performance was poor and was recognized as being learning-disabled, which required modified educational programs by his school. Family history was also significant for her mother having cardiac arrhythmia and dysmorphic facial features (Figure 1c). Analysis of the *KCNJ2* gene revealed a heterozygous c.575C>T (p.Thr192Ile) mutation, which segregates with the disease phenotype (Figures 1c and d).

DISCUSSION

The patient described here had clinical, electrophysiological and genetic features suggestive of the rare cases previously reported as ATS.¹ Nowadays, more than 30 point mutations of the *KCNJ2* gene have been described in patients with ATS, but no obvious phenotype-genotype correlations are observed.^{2,7,8} In our study, we identified one heterozygous missense mutation, p.Thr192Ile (T192I), in the *KCNJ2* gene which segregates with the disease phenotype in this index family. T192I, which was located in the putative cytoplasmic chain after the second transmembrane region M2 of Kir2.1, is postulated to have a crucial role in arranging the location of the phosphatidylinositol-4, 5-bisphosphate (PIP2) binding motif (PKKR, 186–189).⁹ This codon has been reported to have one confirmed mutation, p.Thr192Ala, in two independent Japanese patients with ATS.^{5,9} Therefore, given its amino acid position and co-segregation with disease clinical phenotype, we postulate that T192I is most likely the cause of disease in our index patient.

In addition to the well-known triad of clinical signs, our case provides direct evidence that ATS could be associated with neuropsychiatric phenotypes, manifesting as diffuse periventricular white

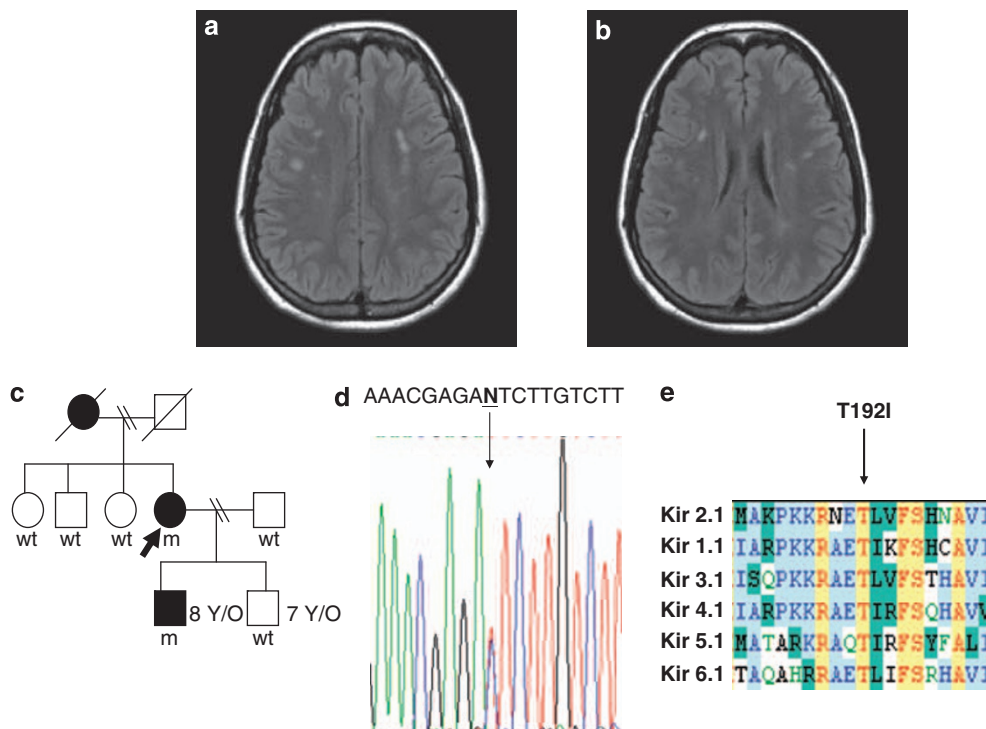


Figure 1 Family pedigree, MRI images and genetic findings in our index patient with *KCNJ2* mutation. (a, b) Fluid-attenuated inversion recovery MRI shows multifocal oval lesions involving the periventricular and subcortical white matter. (c) Family pedigree of our index family. Black symbols denote family members affected with ATS. The proband we described is marked with an arrow. The patient's age at the time of the study is indicated on the top right. m, mutated alleles; wt, normal alleles. (d) Chromatograms of direct sequencing of the *KCNJ2* genomic sequence. The position of the mutations identified in this study is indicated. (e) Amino-acid alignment of one subunit from each of the seven members of the inward-rectifying potassium channels. The mutation identified in this study is denoted above the alignment. The conserved protein residues are marked in yellow. The amino-acid residues were aligned using the program Vector NTI (<http://www.invitrogen.com/site/us/en/home/LINNEA-Online-Guides/LINNEA-Communities/Vector-NTI-Community/Vector-NTI.html>).

matter lesions with pyramidal tract signs and major depression. To prove the connectivity between major depression and ATS is not easy, especially depression is common in patients carrying chronic disease. However, the white matter lesions are not commonly seen clinical signs in a previously healthy subject. Therefore, it is logical to correlate this phenotype with ATS and worth investigating the impact of the *KCNJ2* mutation on the CNS. Our observations support previous studies that Kir2.1 has an important role in neural development.³ It is noted that there is one similar case reported in the previous literature that multiple white matter hyperintense lesions were found in a 24-year-old woman with ATS caused by the *KCNJ2* mutation, who also had diffuse pyramidal signs.¹⁰ Consistent with our neuropsychiatric findings, one recent study that performed neuropsychological tests on ten ATS patients from eight unrelated families showed that cognitive dysfunctions, including defects in executive functions and abstract reasoning, could be part of the ATS clinical spectrums.⁴ Combined with our observations, these findings suggest that the neuropsychiatric phenotypes of ATS may be largely underestimated by clinicians and further large sample studies are warranted to clarify the detail of the CNS involvement in ATS.

The inwardly rectifying potassium channel family (Kirs) is crucial for numerous cellular functions, including regulating the membrane potentials of neurons and potassium siphoning in glia cells.^{11–13} The proper buffering and siphoning of extracellular potassium levels by the glia cells is instrumental for providing an electrochemical gradient for driving potassium into glia and thus regaining the propagation of neuronal action potential between the nodes of Ranvier.¹⁴ Therefore, dysfunction of Kirs may lead to cell death and structure lesions in the CNS. Deletion of Kirs in mouse models has been shown to cause hypomyelination of white matter structures mimicking leukodystrophy, which is supportive with the multiple periventricular hyperdense lesions in our patient.¹⁵ In our study, we found that the *KCNJ2* T192I mutation is the genetic cause of ATS in our index family. T192I is located on the highly conserved region of the C-terminal intracellular domain of the Kir2.1 protein (Figure 1e), highlighting the importance of this residue in the evolution.⁵ Given the conservation at this amino acid position across different members of the inward-rectifying potassium channels, this substitution may disrupt the functional inward-rectifying currents and possibly the protein–protein interaction of the Kir2.1 protein. Therefore, we propose that the loss of function mutation of the *KCNJ2* gene noted in our patient may have a dominant-negative effect on the function of the Kir2.1 protein, which impairs the maintenance of neuronal action potential on the myelin sheath with resultant hypomyelination. Future studies with a larger number of patients are warranted to confirm our hypothesis.

In conclusion, our case provides a direct link between ATS and white matter disease and expands the clinical phenotype of this rare familial syndrome. Patients with ATS, especially those carrying *KCNJ2* mutations, should be monitored for their potential neuropsychiatric system involvement.

CONFLICT OF INTEREST

The authors declare no conflict of interest.

ACKNOWLEDGEMENTS

We thank the patients who have participated in this study and the staff of the Second Core Lab, Department of Medical Research of National Taiwan University Hospital, for technical support during the study.

- Andersen, E. D., Krasilnikoff, P. A. & Overvad, H. Intermittent muscular weakness, extrasystoles, and multiple developmental anomalies. A new syndrome? *Acta. Paediatr. Scand.* **60**, 559–564 (1971).
- Plaster, N. M., Tawil, R., Tristani-Firouzi, M., Canun, S., Bendahhou, S., Tsunoda, A. *et al.* Mutations in Kir2.1 cause the developmental and episodic electrical phenotypes of Andersen's syndrome. *Cell* **105**, 511–519 (2001).
- Patil, N., Cox, D. R., Bhat, D., Faham, M., Myers, R. M. & Peterson, A. S. A potassium channel mutation in weaver mice implicates membrane excitability in granule cell differentiation. *Nat. Genet.* **11**, 126–129 (1995).
- Yoon, G., Quitania, L., Kramer, J. H., Fu, Y. H., Miller, B. L. & Ptacek, L. J. Andersen-Tawil syndrome: definition of a neurocognitive phenotype. *Neurology* **66**, 1703–1710 (2006).
- Haruna, Y., Kobori, A., Makiyama, T., Yoshida, H., Akao, M., Doi, T. *et al.* Genotype-phenotype correlations of *KCNJ2* mutations in Japanese patients with Andersen-Tawil syndrome. *Hum. Mutat.* **28**, 208–220 (2007).
- Gmitrowicz, A. & Kucharska, A. Developmental disorders in the fourth edition of the American classification: diagnostic and statistical manual of mental disorders (DSM IV—optional book). *Psychiatr. Pol.* **28**, 509–521 (1994).
- Hosaka, Y., Hanawa, H., Washizuka, T., Chinushi, M., Yamashita, F., Yoshida, T. *et al.* Function, subcellular localization and assembly of a novel mutation of *KCNJ2* in Andersen's syndrome. *J. Mol. Cell Cardiol.* **35**, 409–415 (2003).
- Davies, N. P., Imbrici, P., Fialho, D., Herd, C., Bilsland, L. G., Weber, A. *et al.* Andersen-Tawil syndrome: new potassium channel mutations and possible phenotypic variation. *Neurology* **65**, 1083–1089 (2005).
- Sooma, M., Schönhera, R., Kubob, Y., Kirsch, C., Klingerc, R. & Heinemann, S. H. Multiple PIP2 binding sites in Kir2.1 inwardly rectifying potassium channels. *FEBS Lett.* **490**, 49–53 (2001).
- Sansone, V. & Tawil, R. Management and treatment of Andersen-Tawil syndrome (ATS). *Neurotherapeutics* **4**, 233–237 (2007).
- Neusch, C., Weishaupt, J. H. & Bahr, M. Kir channels in the CNS: emerging new roles and implications for neurological diseases. *Cell Tissue Res.* **311**, 131–138 (2003).
- Kalsi, A. S., Greenwood, K., Wilkin, G. & Butt, A. M. Kir4.1 expression by astrocytes and oligodendrocytes in CNS white matter: a developmental study in the rat optic nerve. *J. Anat.* **204**, 475–485 (2004).
- Zaritsky, J. J., Eckman, D. M., Wellman, G. C., Nelson, M. T. & Schwarz, T. L. Targeted disruption of Kir2.1 and Kir2.2 genes reveals the essential role of the inwardly rectifying K(+) current in K(+)-mediated vasodilation. *Circ. Res.* **87**, 160–166 (2000).
- Walz, W. Chloride/anion channels in glial cell membranes. *Glia* **40**, 1–10 (2002).
- Neusch, C., Rozengurt, N., Jacobs, R. E., Lester, H. A. & Kofuji, P. Kir4.1 potassium channel subunit is crucial for oligodendrocyte development and *in vivo* myelination. *J. Neurosci.* **21**, 5429–5438 (2001).