

ACKNOWLEDGMENTS

The authors are grateful to Dr. James M. Powers for reviewing the histological findings and to Dr. Jacqueline Bello for reviewing the magnetic resonance imaging scans.

Received for publication, August 8, 1990; accepted, September 28, 1990.

Dr. Goodman's current address is: Division of Neurosurgery, UMDNJ-Robert Wood Johnson Medical School, New Brunswick, NJ 08903-0019.

Reprint requests: Robert R. Goodman, M.D., Ph.D., UMDNJ-Robert Wood Johnson Medical School, Division of Neurosurgery, MEB 464, 1 Robert Wood Johnson Place, CN 19, New Brunswick, NJ 08903-0019.

REFERENCES

- Berger MS, Wilson CB: Posterior fossa epidermoid cysts. *J Neurosurg* 62:214-219, 1985.
- Buchheit WA, Delgado TE: The surgical removal of acoustic neuromas, in Schmidek HH, Sweet W (eds): *Operative Neurosurgical Techniques: Indications, Methods and Results*. New York, Grune & Stratton, 1982, vol 1, pp. 637-647.
- Cushing H: The surgical mortality percentages pertaining to a series of two thousand verified intracranial tumors. *Arch Neurol Psychiatry* 27:1273-1280, 1932.
- Grant FC, Austin GM: Epidermoids: Clinical evaluation and surgical results. *J Neurosurg* 7:190-198, 1950.
- House WF (ed): Transtemporal bone microsurgical removal of acoustic neuromas. *Arch Otolaryngol* 80:597-756, 1964 (monograph).
- Kitaoka K, Abe H, Tashiro K, Kawamoto T, Miyasaka K: The coexistence of basal epidermoid tumor and trigeminal neurinoma within the posterior fossa. *No Shinkei Geka* 14:1243-1248, 1986.
- MacCarty CS, Leavens ME, Love JG, Kernohan JW: Dermoid and epidermoid tumors in the central nervous system of adults. *Surg Gynecol Obstet* 108:191-198, 1956.
- Mahoney W: Die Epidermoide der Zentral-nervensystems. *Z Gesamte Neurol Psychiatr* 155:416-471, 1936.
- Mikhael MA, Ciric IS, Wolff AP: MR diagnosis of acoustic neuromas. *J Comput Assist Tomogr* 11:232-235, 1987.
- Nestor JJ, Korol HW, Nutik SL, Smith R: The incidence of acoustic neuromas. *Arch Otolaryngol Head Neck Surg* 114:680, 1988 (letter).
- Netsky MG: Epidermoid tumors: Review of the literature. *Surg Neurol* 29:477-483, 1988.
- Rubinstein LJ: Tumors of the central nervous system, in *Atlas of Tumor Pathology*. Washington, DC, Armed Forces Institute of Pathology, 1972, ser 2, fasc 6.
- Salazar J, Vaquero J, Saucedo G, Bravo G: Posterior fossa epidermoid cysts. *Acta Neurochir (Wien)* 85:34-39, 1987.
- Scott RM, Wolpert SM, Bartoshesky LE, Zimble S, Klauber GT: Dermoid tumors occurring at the site of previous myelomeningocele repair. *J Neurosurg* 65:779-783, 1986.
- Toglia UJU, Netsky MG, Alexander E Jr: Epithelial (epidermoid) tumors of the cranium: Their common nature and pathogenesis. *J Neurosurg* 23:384-393, 1965.
- Tos M, Thomas J: Epidemiology of acoustic neuromas. *J Laryngol Otol* 98:685-692, 1984.
- Tytus JS, Pennybacker J: Pearly tumors in relation to the central nervous system. *J Neurol Neurosurg Psychiatry* 19:241-259, 1956.
- Vion-Dury J, Vincentelli F, Jiddane M, Van Bunnan Y, Rumeau L, Grisoli F, Salamon G: MR imaging of epidermoid cysts. *Neuroradiology* 29:333-338, 1987.

COMMENT

The authors describe the case of a patient who had both an acoustic schwannoma and an epidermoid cyst lying adjacent to each other in the cerebellopontine angle. This is the first reported case of such an entity. I agree with the authors that this is probably a chance occurrence.

Paul B. Nelson
Pittsburgh, Pennsylvania

0148-396X/91/2801-0436\$03.00/0

NEUROSURGERY

Copyright © 1991 by the Congress of Neurological Surgeons

Vol. 28, No. 3, 1991

Printed in U.S.A.

A Huge Intracranial Xanthogranuloma in the Middle Cranial Fossa: Case Report

Seigo Koyama, M.D., Takashi Tsubokawa, M.D., Yoichi Katayama, M.D., and Hitoshi Hirota, M.D.

Department of Neurological Surgery, Nihon University School of Medicine, Tokyo, Japan

Xanthogranulomas of the dura presenting with clinical symptoms are rare. We report here a case of a huge dural xanthogranuloma in the middle cranial fossa, which caused hemiparesis through marked displacement and stenosis of the middle cerebral artery. Although such tumors usually arise in association with histiocytosis X or familial hyperlipoproteinemia, the present case was not associated with these diseases. (*Neurosurgery* 28:436-439, 1991)

Key words: Brain neoplasm, Xanthogranuloma

INTRODUCTION

Xanthogranulomas of the central nervous system, which arise usually in the choroidal plexus or the dura, are not uncommon as an incidental finding at autopsy (4, 30). Reports of these tumors presenting with clinical symptoms are

rare, however, and are generally those originating from the choroidal plexus, which cause symptoms due to obstruction of the cerebrospinal fluid pathways. Xanthogranulomas of the dura that are large enough to cause symptoms are also rare. We report a case of a huge xanthogranuloma of the dura causing hemiparesis through marked displacement and ste-

nosis of the middle cerebral artery. Although dural xanthogranulomas usually occur in association with histiocytosis X or familial hyperlipoproteinemia, this case was not associated with these diseases.

CASE REPORT

A 67-year-old man was in good health until September 30, 1989, when he suddenly experienced motor weakness of the left upper extremity. He subsequently experienced several alternating episodes of gradual improvement and sudden deterioration of the paresis. He eventually became hemiplegic on the left side.

Plain skull roentgenograms and tomograms demonstrated mottled calcification in the right temporal region and destruction of the base of the middle fossa. Computed tomographic scans revealed an isodense mass within the right middle fossa and high-dense portions in its marginal and central areas. Coronal plane computed tomographic scans clearly demonstrated destruction of the base of the middle cranial fossa (Fig. 1). The mass was minimally enhanced by administration of contrast medium. T1-weighted magnetic resonance images showed the mass as a low intensity lesion. The mass was enhanced heterogeneously by administration of gadolinium diethylene-triamine-pentaacetic acid. The temporal lobe and lateral ventricle were markedly displaced (Fig. 2). Right carotid angiograms revealed a remarkable displacement of the middle cerebral artery and stenosis of the M1 portion. No tumor staining was observed.

Laboratory investigation demonstrated moderate normocytic, normochromic anemia, which was later found to be caused by intestinal bleeding from rectal cancer. Neither hypercholesterolemia nor hyperlipoproteinemia was noted. Other laboratory data were also unremarkable.

On December 22, 1989, the patient underwent surgical removal of the tumor by the transzygomatic approach. The tumor was encapsulated by hard fibrous tissue that could not be separated from the dura of the base of the middle cranial fossa. No invasion into the brain tissue was seen. There were several cysts of various sizes containing brownish fluid within the tumors. The temporal bone was partially destroyed by the tumor and partially hypertrophic. The greater part of the pars

squamosa of the temporal bone was also resected. The postoperative course was uneventful. No evidence of regrowth of the tumor was found 5 months after surgery.

Histopathological examination of the removed tumor revealed proliferation of foamy histiocytes, multinucleated giant cells and cholesterol clefts, and infiltration of inflammatory cells throughout the tumor (Figs. 3 and 4). There was no evidence of proliferation of meningothelial cells. These characteristics were consistent with those of xanthogranulomas. Identical tumor cells were also recognized in the adjacent temporal bone tissue.

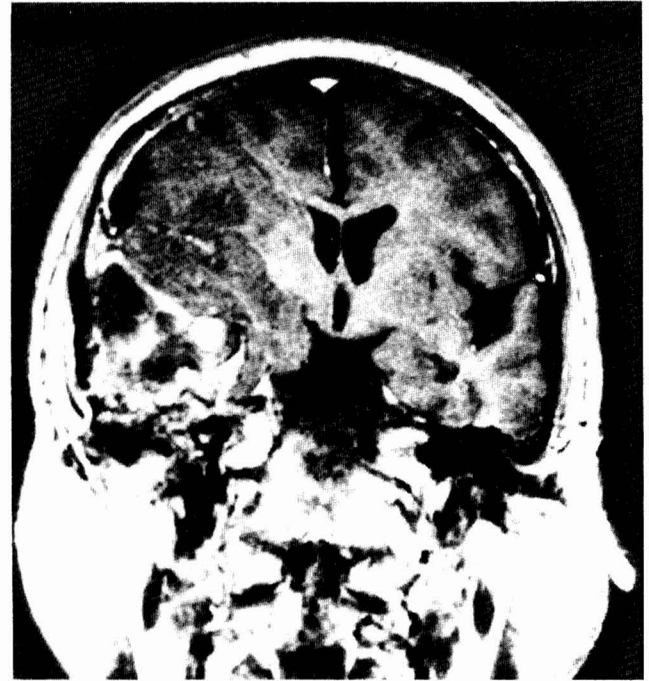

FIG. 2. T1-weighted magnetic resonance image after intravenous administration of gadolinium diethylene-triamine-pentaacetic acid showing a mixed signal intensity mass lesion and displacement of the temporal lobe and lateral ventricle by the mass.

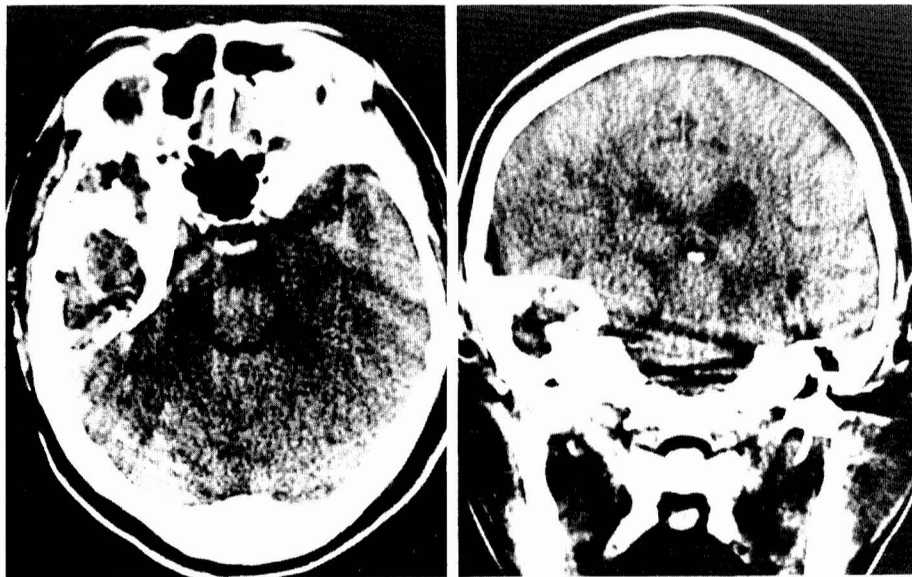


FIG. 1. *Left*, plain computed tomographic scan (axial view) showing an isodense mass within the right middle fossa and high dense portions in its marginal and central areas. *Right*, plain computed tomographic scan (coronal view) demonstrating destruction of the base of the right middle fossa.

FIG. 3. Histopathological findings demonstrating foamy histiocytes, cholesterol clefts, and infiltration of inflammatory cells (hematoxylin and eosin, $\times 100$).

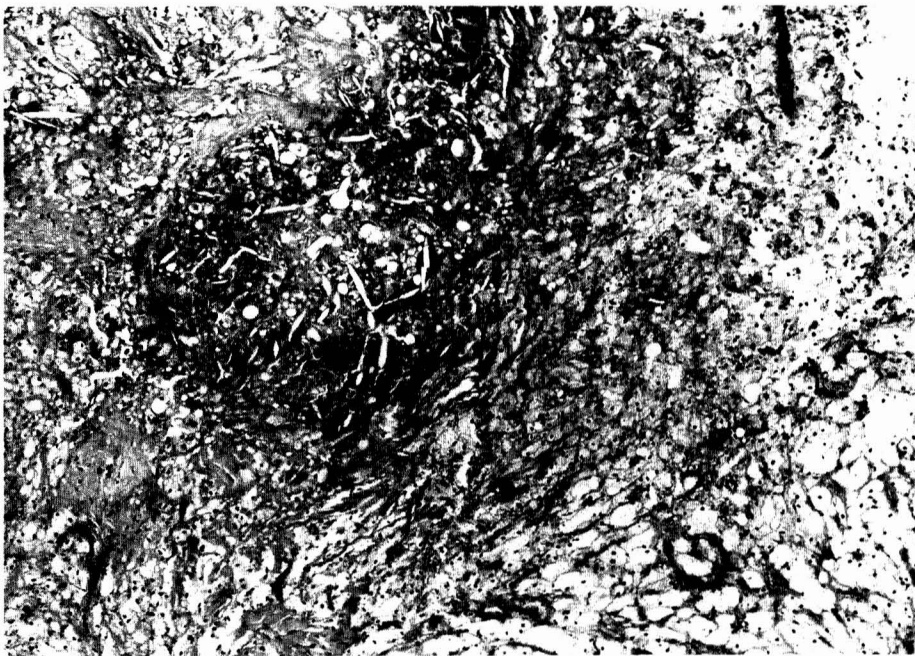
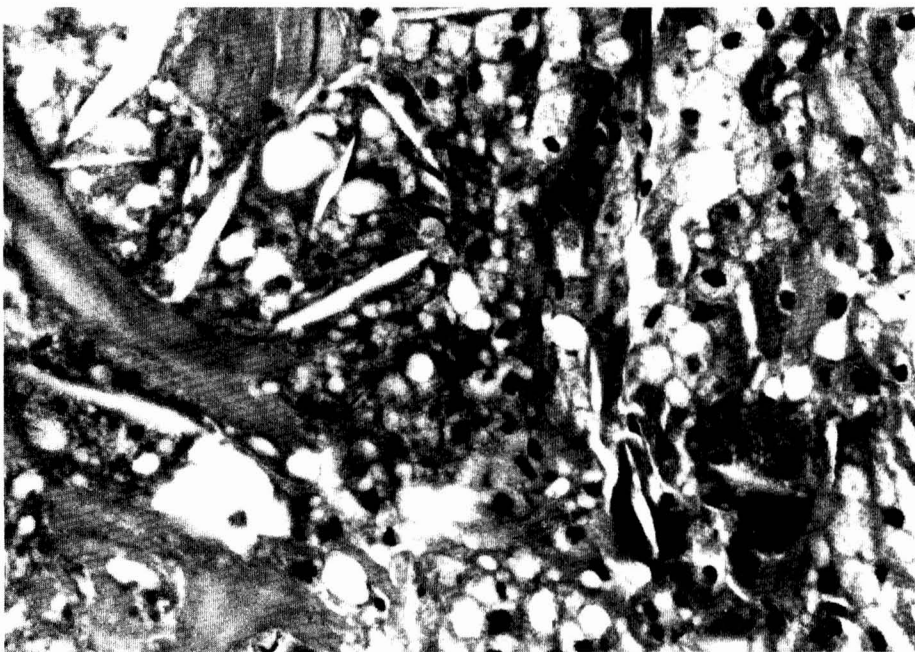


FIG. 4. Histopathological findings (hematoxylin and eosin, $\times 400$).



DISCUSSION

Xanthogranulomas of the central nervous system are not uncommon at autopsy. Choroid plexus xanthogranulomas, for example, are found in 1.6 to 7% of all autopsies (4, 30). These xanthogranulomas are, however, too small to cause clinical symptoms. Twenty-two cases of xanthogranulomas of the choroid plexus that presented with clinical symptoms were found in our literature search. Among these, 15 occurred in the 3rd ventricle (2, 7-9, 11, 14, 15, 19, 22, 25, 26, 29) and 7 in the lateral ventricle (10, 12, 16, 17, 21, 23, 27). The symptoms in these cases were produced by obstruction of the cerebrospinal fluid pathways. Seven (2, 11, 14, 22, 25, 26) of the 15 cases (47%) of xanthogranulomas within the 3rd ven-

tricle were associated with colloid cysts, which may also interfere with the cerebrospinal fluid pathways. The sharing of a common pathogenetic process by choroid plexus xanthogranulomas and colloid cysts has therefore been postulated (24). For this reason, many authors think that desquamated epithelial cells migrating into the choroid plexus accumulate and release lipids, which provokes the infiltration of inflammatory cells. That is, xanthogranulomatous lesions associated with colloid cysts are, in fact, degenerative changes within the cyst.

In contrast to choroid plexus xanthogranulomas, tumors of the dura with similar histological features are likely to produce clinical symptoms even less frequently (5). We found only 8 cases (1, 3, 5, 6, 13, 18, 20, 28) with clinical symptoms in the

literature, most of which were huge in size. The clinical symptoms in the present case were most probably caused by compression of the middle cerebral artery by the huge tumor.

Dural xanthogranulomas usually occur with a background of histiocytosis X or familial hyperlipoproteinemia. All of the 8 reported cases of dural xanthogranulomas were, in fact, associated with these diseases. This association is in clear contrast to the observation that only 2 (9%) (8, 16) of the 22 choroid plexus xanthogranulomas occurred in patients with such diseases. Many patients with dural xanthogranulomas had multiple lesions, reflecting the presence of systemic pathogenetic factors in most dural xanthogranulomas. Several authors assumed that factors in the putative autoimmune process of histiocytosis X may have a lipotropic effect, which causes undifferentiated mesenchymal cells in the dura to undergo xanthomatous transformation (18). It appears, therefore, that xanthogranulomas of the choroid plexus and the dura represent similar end points of different, that is, local and systemic, pathological processes. Only one reported case had both dural and choroid plexus xanthogranulomas (28). The dural xanthogranuloma in the present case occurred without a background of either histiocytosis X or hyperlipoproteinemia and formed a solitary tumor. This tumor therefore represents the first reported case of a large dural xanthogranuloma not associated with the above diseases. It may have been a result of xanthomatous transformation of undifferentiated mesenchymal cells of the dura induced by some unknown cause.

Received for publication, July 2, 1990; accepted, final form, September 24, 1990.

Reprint requests: Seigo Koyama, M.D., Department of Neurological Surgery, Nihon University School of Medicine, 30 Oyaguchi-Kamimachi, Itabashiku, Tokyo 173, Japan.

REFERENCES

1. Akazawa S, Kurata A, Ikeda Y, Toyama K, Miyake S, Takamori M, Takaoka Y: A case of familial type hyperlipoproteinemia with a huge intracranial xanthoma, hypertension, and periarticular bone lesions. *Nippon Naika Gakkai Zasshi* 69:867-873, 1980.
2. Antunes JL, Kvam D, Ganti SR, Louis KM, Goodman J: Mixed colloid cysts-xanthogranulomas of the third ventricle. *Surg Neurol* 16:256-261, 1981.
3. Arnold HA, Bainborough AR: Weber-Christian disease with visceral involvement: Case report and review of the literature. *Can Med Assoc J* 89:1138-1142, 1963.
4. Ayres WW, Haymaker W: Xanthoma and cholesterol granuloma of the choroid plexus: Report of the pathological aspect in 29 cases. *J Neuropathol Exp Neurol* 19:280-295, 1960.
5. Elian M, Bornstein B, Matz S, Askenasy HM, Sandbank U: Neurological manifestations of general xanthomatosis: Hand-Schüller-Christian disease. *Arch Neurol* 21:115-120, 1969.
6. Ferrer-Roca O, Segura F, Nogue S, Duro JC, Soriano E: Fibrosis multi-focal o sistêmica con afectación de áreas inusuales (cavidad craneal). *Rev Clin Esp* 152:489-494, 1979.
7. Gherardi R, Nguyen JP, Gaston A, Poirier J: Symptomatic xanthogranuloma of the third ventricle: A clinicopathological report. *Eur Neurol* 23:156-162, 1984.
8. Godersky JC, Rockswold G, Larson DA: Xanthogranuloma of the third ventricle producing hydrocephalus. *Neurosurgery* 7:68-78, 1980.
9. Hadfield MG, Ghatak NR, Wanger GP: Xanthogranulomatous colloid cyst of the third ventricle. *Acta Neuropathol (Berl)* 66:343-346, 1985.
10. Handagoon P, Pitakdamrongwong N, Shuangshoti S: Xanthogranulomas of choroid plexus. *Neuroradiology* 29:172-173, 1987.
11. Jaer O, Loken AC, Nesbakken R: Hydrocephalus due to xanthogranuloma: Case report. *J Neurosurg* 39:659-661, 1973.
12. Lynch JC, de Moraes GP, Duarte F: Xanthogranuloma do plexo corioideo: Relato de caso. *Arq Neuropsiquiatr* 46:191-194, 1988.
13. Mangiardi JR, Rappaport HZ, Ransohoff J: Systemic Weber-Christian disease presenting as an intracranial mass lesion: Case report. *J Neurosurg* 52:134-137, 1980.
14. Matsushima T, Fukui M, Kitamura K, Soejima T, Ohta M, Okano H: Mixed colloid cyst-xanthogranuloma of the third ventricle: A light and electron microscopic study. *Surg Neurol* 24:457-462, 1985.
15. Montaldi S, Deruaz J-P, Cai Z, de Tribolet N: Symptomatic xanthogranuloma of the third ventricle: Report of two cases and review of the literature. *Surg Neurol* 32:200-205, 1989.
16. Morello A, Campesi G, Bettinazzi N, Albiggiani A: Neoplastiform xanthomatous granulomas of choroid plexus in a child affected by Hand-Schüller-Christian disease: Case report. *J Neurosurg* 26:536-541, 1967.
17. Pear BL: Xanthogranuloma of the choroid plexus. *AJR* 143:401-402, 1984.
18. Pick P, Jean E, Horoupian D, Factor S: Xanthogranuloma of the dura in systemic Weber-Christian disease. *Neurology* 33:1067-1070, 1983.
19. Razavi-Encha F, Gray F, Gaston A, Gherardi R, Caron JP, Poirier J: Symptomatic xanthogranuloma of the choroid plexus of the third ventricle: A new case with ultrastructural study. *Surg Neurol* 27:569-574, 1987.
20. Rees A, Lee G, Stocks J, Vella MA, Katz J, Galton DJ: Raised intracranial pressure due to large intracranial xanthoma. *Br Med J* 288:1722-1723, 1984.
21. Rosner S: Xanthoma of the choroid plexus in a child. *J Nerv Ment Dis* 125:339-341, 1957.
22. Rush JL, Kusske JA, Porter RW, Pribram HW: Xanthogranulomas of the third ventricle. *Neurosurgery* 4:329-333, 1979.
23. Rutherford GS, Mathew B: Xanthogranuloma of the choroid plexus of lateral ventricle, presenting with parosmia and parageusia. *Br J Neurosurg* 1:285-288, 1987.
24. Shuangshoti S, Netsky MG: Xanthogranuloma (xanthoma) of choroid plexus: The origin of foamy (xanthoma) cells. *Am J Pathol* 48:503-533, 1966.
25. Shuangshoti S, Phonprasert C, Suwanwela N, Netsky MG: Combined neuroepithelial (colloid) cyst and xanthogranuloma (xanthoma) in the third ventricle. *Neurology* 25:547-552, 1975.
26. Szper I, Oi S, Leestma J, Kim KS, Wetzel NE: Xanthogranuloma of the third ventricle: Case report. *J Neurosurg* 51:565-568, 1979.
27. Terao H, Kobayashi S, Teraoka A, Okeda R: Xanthogranulomas of the choroid plexus in a neuro-epileptic child: Case report. *J Neurosurg* 48:649-653, 1978.
28. Vaquero J, Leunda G, Cabezudo JM, Juan M, Herrero J, Bravo G: Posterior fossa xanthogranuloma: Case report. *J Neurosurg* 51:718-722, 1979.
29. Wiot JG, Lukin RR, Tomsick TA: Xanthogranuloma of the third ventricle. *AJNR* 10:57, 1989.
30. Wolf A, Cowen D, Graham S: Xanthomas of the choroid plexus in man. *J Neuropathol Exp Neurol* 9:286-297, 1950.