

Standard and limitation of intraoperative monitoring of the visual evoked potential

Kunihiko Kodama, MD, Tetsuya Goto, MD, Atsushi Sato, MD
Keiichi Sakai, MD, Yuichiro Tanaka, MD, Kazuhiro Hongo, MD

Corresponding author: Tetsuya Goto, MD

Department of Neurosurgery

Shinshu University School of Medicine

Asahi 3-1-1, Matsumoto 390-8621, Japan

Tel: +81-263-37-2690

Fax: +81-263-37-0480

E-mail: tegotou@shinshu-u.ac.jp

Abstract

Background:

Visual evoked potential (VEP) has been installed as one of the intraoperative visual function monitorings. It remains unclear, however, whether intraoperative VEP monitoring facilitates as a real time visual function monitoring with satisfactory effectiveness and sensitivity. To evaluate this, relationships between VEP waveform changes and postoperative visual function were analyzed retrospectively.

Methods:

Intraoperative VEP monitoring was carried out for 106 sides (eyes) in 53 surgeries, including 2 intraorbital, 36 parasellar and 15 cortical lesions in Shinshu University Hospital under total intravenous anaesthesia (TIVA). Red light flash stimulation was provided to each eye independently. VEP recording and postoperative visual function were analyzed.

Results:

In 103 out of 106 sides (97%), steady VEP monitoring was recorded. Stable VEP was acquired from eyes having corrected visual acuity greater than 0.4. VEP was not recorded in one side with corrected visual acuity of 0.3 and two sides in whom sevoflurane was used incidentally for anaesthesia. Transient VEP decrease was observed in 3 sides, but visual function was preserved. Permanent VEP decrease was seen in 7 sides, which presented visual impairment postoperatively. In one side, visual acuity improved but minor visual field defect was encountered postoperatively, though VEP unchanged throughout the surgery.

Conclusions:

Intraoperative monitoring of VEP predicts postoperative visual function: reversible change in VEP means visual function to be preserved. Visual field defect without decrease in the visual acuity may not be

predicted by VEP monitoring. Intraoperative VEP monitoring will be mandatory for surgeries harboring a risk of visual impairment.

Keywords

intraoperative electrophysiological monitoring; visual evoked potential; visual acuity; visual field

Purpose

Neurosurgical procedures for treatment of tumours or vascular lesions along the visual pathways carry a risk of visual dysfunction. This applies mostly to parasellar tumours and aneurysms, but also to temporal and occipital lobe tumours and intraorbital lesions. An already impaired visual pathway is particularly at risk in patients with parasellar lesions, such as tuberculum sellae meningiomas, craniopharyngiomas and internal carotid-paraclinoid aneurysms. Postoperative visual impairment is a larger concern in patients with preserved visual function. A reliable method for real time visual function monitoring would assist in intraoperative decision making regarding radicality of excision and intermittent manoeuvres near the optic apparatus.

It was difficult to obtain stable VEP in real time intraoperative monitoring because of interruption by anaesthesia, in addition to insufficient and unstable stimuli delivery [17, 18]. However, VEP has recently been established for use in intraoperative visual function monitoring [1, 5 – 14, 16 – 18, 21, 22]. Due to conflicting reports on the usefulness of intraoperative monitoring of visual function by VEP, a consensus has yet to be reached and it remains unclear whether intraoperative VEP monitoring can be used in real time visual function monitoring with satisfactory results and sensitivity. In the present study, VEP was examined in surgeries associated with a high risk of optic apparatus damage. The relationships between VEP waveform changes and postoperative visual function were examined.

Clinical Materials and Methods

Between 2004 and 2007, intraoperative VEP monitoring was performed in 106 sides (eyes) in 53 patients (2 intraorbital, 36 parasellar and 15 cortical lesions) in our institute. Clinical application of intraoperative VEP monitoring has been approved by the Ethical Committee of Shinshu University School of Medicine, and informed consent was obtained from the patients and their family. Flash VEP was recorded with a Neuropack evoked potential measuring system (Nihon Kohden, Tokyo, Japan). All patients were maintained under total intravenous anaesthesia (TIVA). Goggles incorporating with 15 red light (660 nm)-emitting diodes (Unique Medical Co. Ltd, Tokyo, Japan) (Fig. 1) were placed over the patients' closed eyelids in both sides. The goggles had a thin and curved design and were made from reinforced plastic suitable for ethylene oxide gas sterilisation. The goggles were placed on a sterilised drape after craniotomy if the skin flap interfered with desirable goggle positioning at the early stage of craniotomy, such as bifrontal craniotomy and orbitozygomatic osteotomy. Flashing light intensity of the diodes can be adjusted with an electric current ranging from 0 to 20 mA by a bath amplifier, resulting in a light intensity of 0 to 175 mCd in the goggles. Averaged VEP waveform was obtained after each eye was stimulated separately. The stimulus average was 1 flash (40 ms)/s, and 40 to 100 flashes were recorded to obtain each averaged VEP waveform. Recording was performed in a montage of the 5 channels, with electrodes placed on the bilateral earlobes (A+) and the left occiput (LT and LO), occipital midline (Oz), and the right occiput (RO and RT). Bandpass was set from 1,000 to 10 Hz. A small negative potential and a large positive potential around 100 ms were recorded. The amplitude of the VEP was defined as the voltage difference between these two potentials. Needle electrodes were inserted subcutaneously at the lateral canthi for electroretinogram (ERG) recording. ERG was recorded simultaneously with VEP to guarantee delivery of adequate flash stimuli to the retina.

VEP was recorded first after completion of patient setup. At least 2 consecutive ERG and VEP were recorded to confirm the reproducibility of the ERG and VEP waveforms after setup in the

absence of surgical procedures. Minimal stimulation intensity that produced maximal potential amplitude around 100 ms, supramaximal stimulation, was set for the stimulation intensity. The supramaximal stimulation ranged from 8 to 12 mA, resulting in 70 to 105 mCd in our series. The mean amplitude of initial VEP was 3.5 ± 1.2 μ V. Then, VEP was recorded at each step in the surgical procedures. An amplitude decrease less than 50% of the control level was defined as positive. The examiner promptly advised the operator if a significant VEP change was observed, and the surgical procedure was ceased until VEP recovered upon the operator's decisions. Intraoperative VEP changes were assessed and evaluated by comparison with postoperative visual function. Corrected visual acuity was used as visual acuity in this study.

Results

Correlation of intraoperative VEP change and postoperative visual function

Intraoperative VEP was recorded in 103 of 106 sides (97%). Preoperative visual acuity ranged from 0.3 to 1.5. VEP was not recorded in one side with visual acuity of 0.3, and two sides in a patient in whom sevoflurane was used incidentally for anaesthesia. Minimum visual acuity was 0.4 in the patients in whom stable VEP was recorded. Stable VEP was acquired in 103 other sides throughout the surgeries, and no complications related to VEP monitoring were encountered. The results of VEP changes and visual outcome are shown in the Table. In the unchanged group, one visual field defect occurred in one side, but visual acuity and fields improved or remained unchanged in other patients postoperatively. No visual impairment occurred in the group in which VEP showed a transient decrease. Severe visual dysfunction occurred in the permanent VEP loss group.

Illustrative cases

Patient 1 was a 62-year-old woman with a 6-mm right unruptured paraclinoid aneurysm. The

contralateral approach was adopted for clipping surgery. The relatively thick superior hypophyseal artery originated from the aneurysm body, and ran to the optic chiasm and the right optic nerve. Before clipping the neck of the aneurysm, this artery was transiently occluded. Five minutes after occlusion, the VEP decreased to flat. However, the VEP recovered 5 minutes after release. After further dissection, the artery was transiently occluded again, and a reproducible transient VEP decrease was observed. Complete neck clipping was abandoned, and body clipping was carried out to preserve the superior hypophyseal artery. The VEP amplitude was maintained after the clipping procedure. The patient encountered no visual impairment postoperatively [8].

Patient 2 was a 60-year-old woman with an 11-mm right P2 unruptured aneurysm. A posterior subtemporal approach was taken. Five minutes of transient proximal occlusion before clipping produced a transient VEP change, which was mainly apparent as an amplitude decrease accompanied with a latency delay of positive wave around 100 ms. The sudden VEP change recovered after release of occlusion. Second transient occlusion also showed the same VEP change. Finally, the amplitude recovered and remained at the control level after release of occlusion (Fig. 2). The patient did not show any visual impairment postoperatively.

Patient 3 was a 51-year-old woman with a 15-mm unruptured left internal carotid artery aneurysm. Preoperative neuroimaging revealed an aneurysm protruding superomedially under the left optic nerve, which was compressed by the aneurysm dome superiorly (Fig. 3A, B). Her visual acuity was 1.0 in the left eye preoperatively. In the operative field, the right optic nerve appeared very thin and was compressed toward the superior direction by the aneurysmal dome. VEP acquired by the left eye stimuli was recorded before craniotomy. The amplitude of VEP decreased gradually during dissection of the Sylvian fissure and approaching the left optic nerve, and finally the VEP disappeared. But, the VEP appeared gradually during optic canal unroofing. However, the amplitude decreased again when manipulating and dissecting the optic nerve from the aneurysmal dome and did not recover (Fig. 3C). Postoperatively, the left eye appeared to be blind.

Patient 4 was a 59-year-old man with recurrent Cushing disease and

transcranial tumour removal was carried out by the right pterional approach. Preoperative visual acuity was 1.2 in both sides, and no field defect was noted. During optic canal unroofing, a diamond drill damaged some part of the right optic nerve unintentionally. VEP monitoring was stable and maintained at the control level before and after the procedure. His visual acuity improved to 1.5 in both sides. However, he showed lower nasal quadrantanopsia postoperatively (Fig. 4).

Discussion

Feasibility of VEP for intraoperative real time monitoring

Intraoperative flash VEP monitoring has been considered useful [1, 5 – 8, 10, 12-14, 16 – 18, 21, 22] or unreliable [2 – 4, 9, 11, 19, 20]. VEP has been criticised as not being “stable”. Some authors have reported considerable intra- and interindividual variability of the VEP recordings and they concluded that intraoperative VEP monitoring in surgically anaesthetised patients was not reliable [19, 20]. On the other hand, under TIVA, the amplitude of the VEP is larger and less variable in amplitude and latency [15, 17, 18]. In our series, some degrees of VEP changes were observed in the patients under TIVA, but stable waveforms were recorded even with longer operating time. In comparing waveform changes before and after a certain surgical procedure, it is reasonable and acceptable that VEP changes during the procedure are due to the procedure itself. It is necessary to suspend the procedure to observe chronological VEP changes. In our series, VEP was lost in 7 sides during surgery, and all patients showed severe postoperative visual disturbance. In contrast, 3 sides with transient VEP decrease and restoration during surgery showed no visual impairment after surgery. With our method, one VEP recording requires only 32 s (inter-stimulation interval 800 ms × 40 times). A sudden VEP change during a particular surgical step seems to indicate visual impairment, and intraoperative flash VEP monitoring is feasible for real time visual function monitoring. A VEP recording method with greater temporal resolution may be able to detect VEP changes at the reversible stage even in the group with

visual impairment in this study.

Stable stimulation method

Stimulation delivery is another critical point for stable intraoperative VEP monitoring. We used custom-designed goggles incorporating red light-emitting diodes capable of withstanding sterilisation. Supramaximal stimulation intensity on VEP was measured initially and stably maintained in all patients using these goggles. Lighter and more durable goggle development and cautious goggle setup promise stable delivery of stimuli, which had been a major obstacle for intraoperative VEP monitoring.

Mechanism of VEP change

Damage to the visual pathway during surgical procedures can be divided into three types: 1) ischaemic injury due to occlusion of the arteries supplying the optic apparatus, such as transient artery occlusion in aneurysm clipping surgery; 2) mechanical damage to the optic apparatus by dissection and/or retraction of the visual pathway, such as the optic nerve, chiasm and tract; and 3) a combination of 1) and 2).

VEP loss in patient 1 was considered due to ischaemia in the optic nerve and/or chiasm by transient occlusion of the superior hypophyseal artery supplying these parts of the visual apparatus. Intraoperative VEP monitoring detected ischaemic changes within a few minutes after the onset of ischaemia. In patient 2, the VEP decrease seemed to reflect ischaemia of the optic radiation and/or primary visual cortex by transient posterior cerebral artery occlusion. In patient 3, VEP aggravation can be considered due to mechanical damage, such as stretching of the optic nerve by aneurysm and/or surgical manipulation.

It is difficult to determine which type of damage in the visual pathway is related to changes in

VEP. Therefore, it is important to evaluate and confirm the presence of VEP changes at each step in the surgical procedure to prevent postoperative visual complications.

Limitation of intraoperative VEP for real time monitoring

Postoperative hemianopsia could be detected as sudden VEP changes, but quadrantanopsia could not be detected on intraoperative VEP monitoring in this series. Thus, VEP can disclose visual acuity impairment with greater sensitivity than partial visual field defects, which do not affect acuity. Moreover, VEP changes reflect visual acuity more sensitively than visual field defects. Especially, sudden VEP changes can disclose hemianopsia caused by ischaemia, but it may be difficult to detect minor visual field defects resulting from gradual manipulation on the optic radiation.

Conclusions

Volatile anaesthetic agents disturb VEP recording. VEP can be steadily monitored in patients with corrected visual acuity greater than 0.4. Permanent VEP loss means postoperative severe visual dysfunction. Transient VEP changes do not indicate postoperative visual disturbance. Visual field defects without decreases in the visual acuity may not be predicted by VEP monitoring.

The authors declare that we have no conflict of interest.

References

- [1] Albright AL, Sclabassi RJ (1985) Cavitron ultrasonic surgical aspirator and visual evoked potential monitoring for chiasmal gliomas in children. Report of two cases. *J Neurosurg* 63: 138-40
- [2] Cedzich C, Schramm J, Fahlbusch R (1987) Are flash-evoked visual potentials useful for intraoperative monitoring of visual pathway function? *Neurosurgery* 21:709-715
- [3] Cedzich C, Schramm J, Mengedoht CF, Fahlbusch R (1988) Factors that limit the use of flash visual evoked potentials for surgical monitoring. *Electroencephalogr Clin Neurophysiol* 71: 142-145
- [4] Cedzich C, Schramm J (1990) Monitoring of flash visual evoked potentials during neurosurgical operations. *Int Anesthesiol Clin* 28: 165-169
- [5] Chacko AG, Babu KS, Chandy MJ (1996) Value of visual evoked potential monitoring during trans-sphenoidal pituitary surgery. *Br J Neurosurg* 10: 275-278
- [6] Costa e Silva I, Wang AD, Symon L (1985) The application of flash visual evoked potentials during operations on the anterior visual pathways. *Neurol Res* 7: 11-16
- [7] Feinsod M, Selhorst JB, Hoyt WF, Wilson CB (1976) Monitoring optic nerve function during craniotomy. *J Neurosurg* 44: 29-31
- [8] Goto T, Tanaka Y, Kodama K, Kusano Y, Sakai K, Hongo K (2007) Loss of visual evoked potential following temporary occlusion of the superior hypophyseal artery during aneurysm clip placement surgery. Case report. *J Neurosurg* 107: 865-867
- [9] Harding GF, Bland JD, Smith VH (1990) Visual evoked potential monitoring of optic nerve function during surgery. *J Neurol Neurosurg Psychiatry* 53: 890-895
- [10] Herzon GD, Zelear DL (1994) Intraoperative monitoring of the visual evoked potential during endoscopic sinus surgery. *Otolaryngol Head Neck Surg* 111: 575-579
- [11] Hussain SS, Laljee HC, Horrocks JM, Tec H, Grace AR (1996) Monitoring of intra-operative visual evoked potentials during functional endoscopic sinus surgery (FESS) under general anaesthesia. *J Laryngol Otol* 110: 31-36
- [12] Jones NS (1997) Visual evoked potentials in endoscopic and anterior skull base surgery: a review. *J Laryngol Otol* 111:513-516
- [13] Kamada K, Todo T, Morita A, Masutani Y, Aoki S, Ino K, Kawai K, Kirino T (2005) Functional monitoring for visual pathway using real-time visual evoked potentials and optic-radiation tractography. *Neurosurgery* 57(1 Suppl):121-127
- [14] Kodama, K, Goto T, Sato A, Sakai K, Tanaka Y, Hongo K (2008) [Intraoperative monitoring of visual evoked potential for aneurysm clipping surgery.] *Surg Cereb Stroke* 36: 350-354
- [15] Nakagawa I, Hidaka S, Okada H, Kubo T, Okamura K, Kato T (2006) [Effects of sevoflurane and propofol on evoked potentials during neurosurgical anesthesia.] *Masui* 55: 692-698.
- [16] Ota T, Kawai K, Kamada K, Kin T, Saito N (2009) Intraoperative monitoring of cortically recorded visual response for posterior visual pathway. *J Neurosurg* : published online July 24, 2009; DOI: 10.3171/2009.6.JNS081272.

- [17] Sasaki T, Ichikawa T, Sakuma J, Suzuki K, Matsumoto M, Itakura T, Kodama N, Murakawa M (2006) [Intraoperative monitoring of visual evoked potentials.] *Masui* 55: 302-313
- [18] Sasaki T, Itakura T, Suzuki K, Kasuya H, Munakata R, Muramatsu H, Ichikawa T, Sato T, Endo Y, Sakuma J, Matsumoto M (2009) Intraoperative monitoring of visual evoked potential: introduction of a clinically useful method. *J Neurosurg* : published online February 6, 2009; DOI: 10.3171/2008.9.JNS08451.
- [19] Wiedemayer H, Fauser B, Armbruster W, Gasser T, Stolke D (2003) Visual evoked potentials for intraoperative neurophysiologic monitoring using total intravenous anesthesia. *J Neurosurg Anesthesiol* 15: 19-24
- [20] Wiedemayer H, Fauser B, Suddalcioglu IE, Armbruster W, Stolke D (2004) Observation on intraoperative monitoring of visual pathways using steady-state visual evoked potentials. *Eur J Anesthesiol* 21: 429-33
- [21] Wilson WB, Kirsch WM, Neville H, Stears J, Feinsod M, Lehman RA (1976) Monitoring of visual function during parasellar surgery. *Surg Neurol* 5: 323-329
- [22] Wright JE, Arden G, Jones BR (1973) Continuous monitoring of the visually evoked response during intra-orbital surgery. *Trans Ophthalmol Soc U K* 93: 311-314

Figure legends

Fig. 1 Newly-designed stimulating goggle. A: outer (left) and inner sides (right). B: goggles setup on eyelid.

Fig. 2 Intraoperative VEP recording with flash stimulation to the right eye in patient 2. Channel of montage: LT-A+, LO-A+, Oz-A+, RO-A+ and RT-A+, One division: $2\mu\text{V}/20\text{mS}$. A : Before transient occlusion, B: 5 min. after first occlusion, VEP decreased, C: 5 min. after first transient occlusion release, VEP recovered, D: 5 min. after second transient occlusion, VEP decreased again, E: 10 min after second transient occlusion release, VEP recovered.

Fig. 3 Preoperative three-dimensional left carotid angiogram (A) and CT angiogram (B) in patient 3 demonstrating a 15-mm internal carotid-ophthalmic artery aneurysm with broad neck protruding superomedially. Intraoperative VEP recording with flash stimulation to the left eye (C). Channel of montage: LT-A+, LO-A+, Oz-A+, RO-A+ and RT-A+, One division: $2\mu\text{V}/20\text{mS}$, and ERG of the left eye. One division: $20\mu\text{V}/20\text{mS}$. a: before craniotomy, b: after craniotomy, VEP decreased, c: 10 min. after optic canal unroofing, VEP recovered, d: final waveform after clipping, VEP decreased again.

Fig. 4 Preoperative (A) and postoperative (B) Gd-enhanced MRI visual fields and acuities of patient 4. The tumor was removed adequately, but right eye demonstrated lower nasal quadrantanopsia postoperatively. Visual acuities improved. Intraoperative VEP waveforms showed no significant change (C). Channel of montage: LT-A+, LO-A+, Oz-A+, RO-A+ and RT-A+, One division: $2\mu\text{V}/20\text{mS}$.

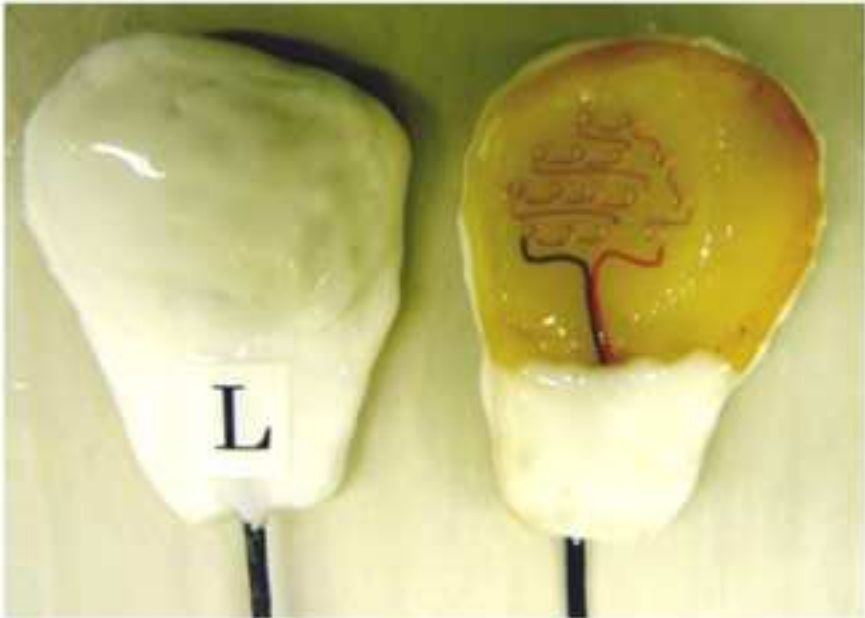
Table: VEP change and visual function outcome

VEP amplitude change		visual function outcome	
decreased, restored	3	unchanged	3
decreased, not restored	7	VF defect, VA unchanged	4
		VA impairment	3
unchanged	93	minor VF defect	1
		unchanged	92

total: N= 103 sides

Fig. 1 newly-designed stimulating goggle

A



B

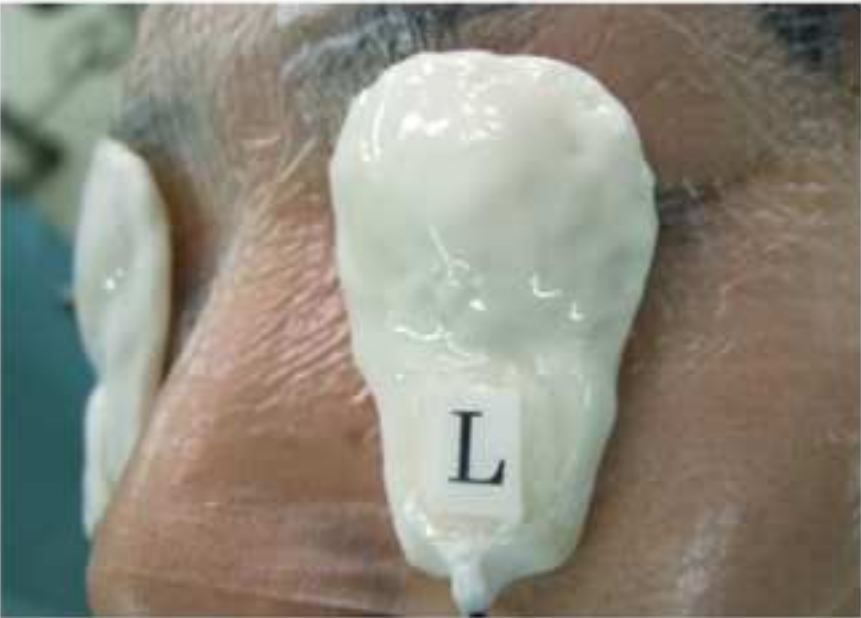

Fig. 2 intraoperative VEP recording in patient 2.

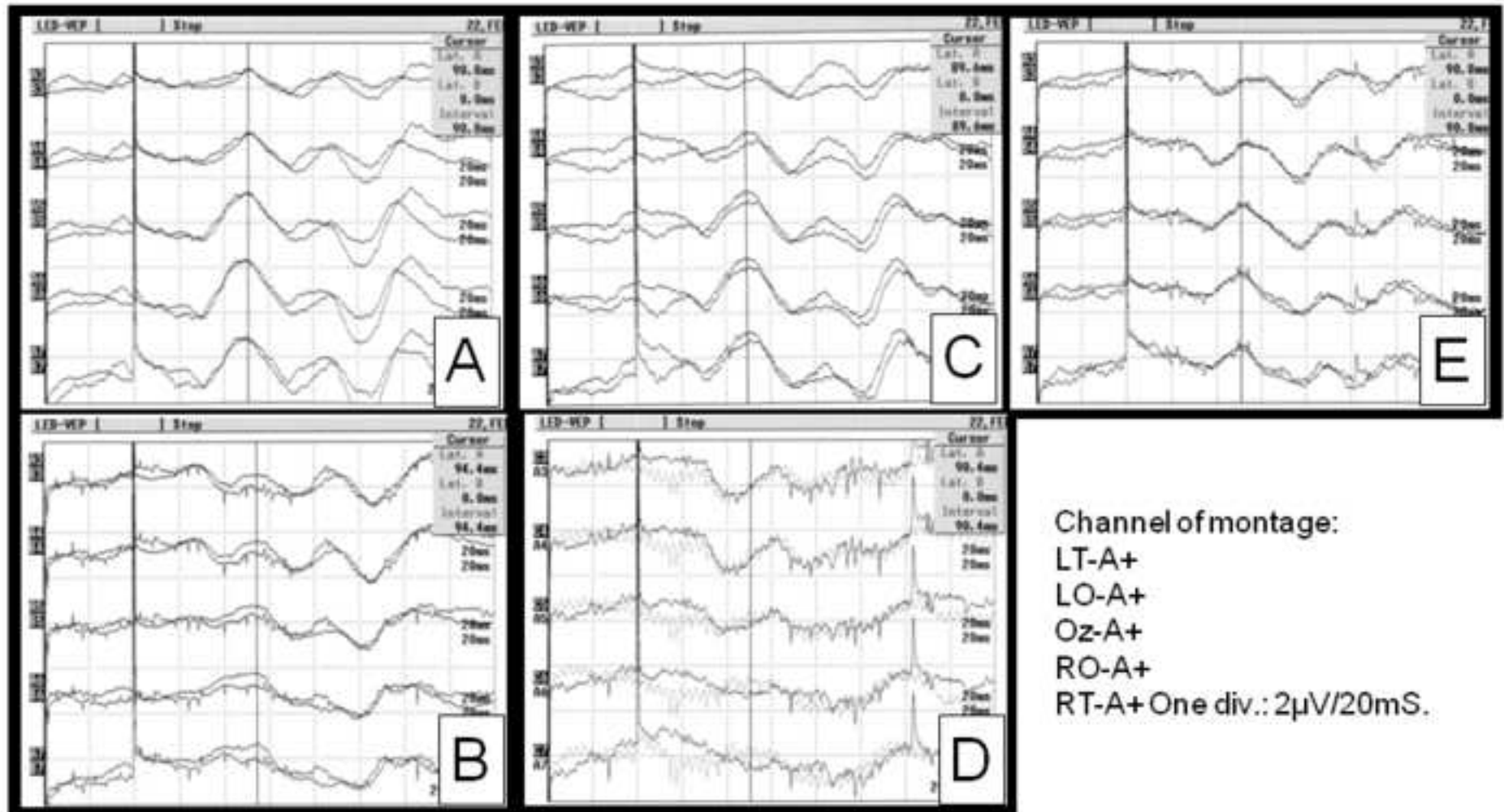
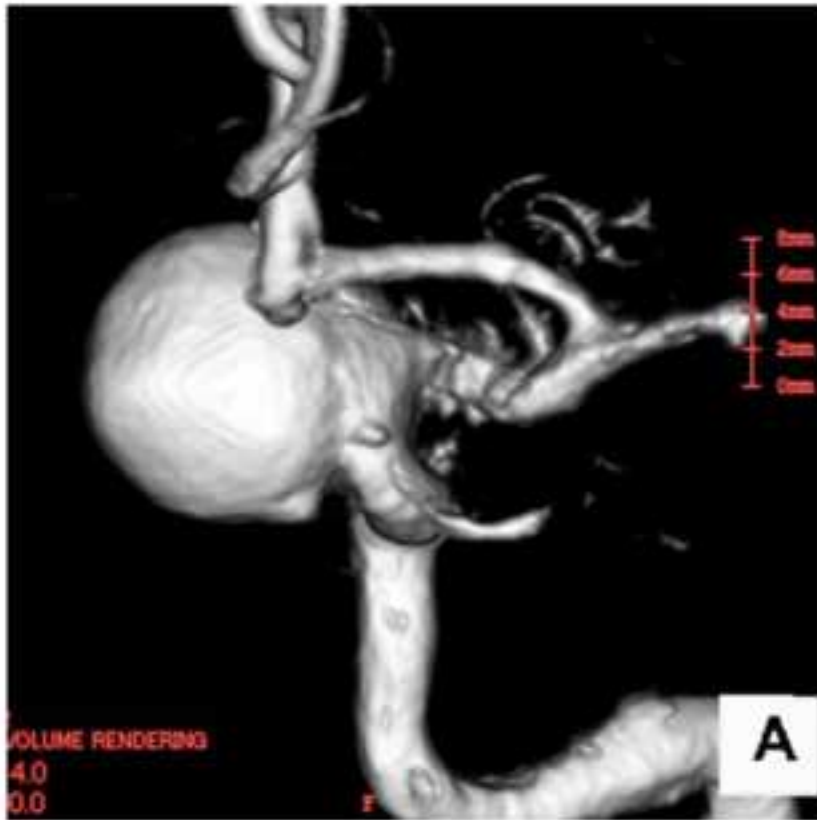

Fig. 3 preoperative neuroimaging and intraoperative VEP recording in patient 3

A



B

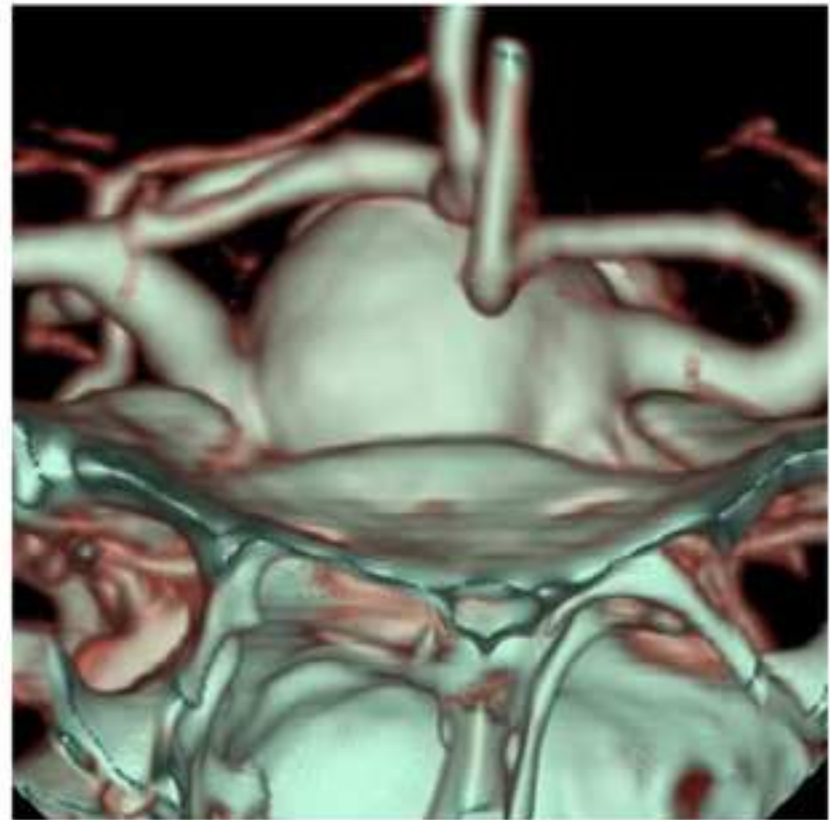
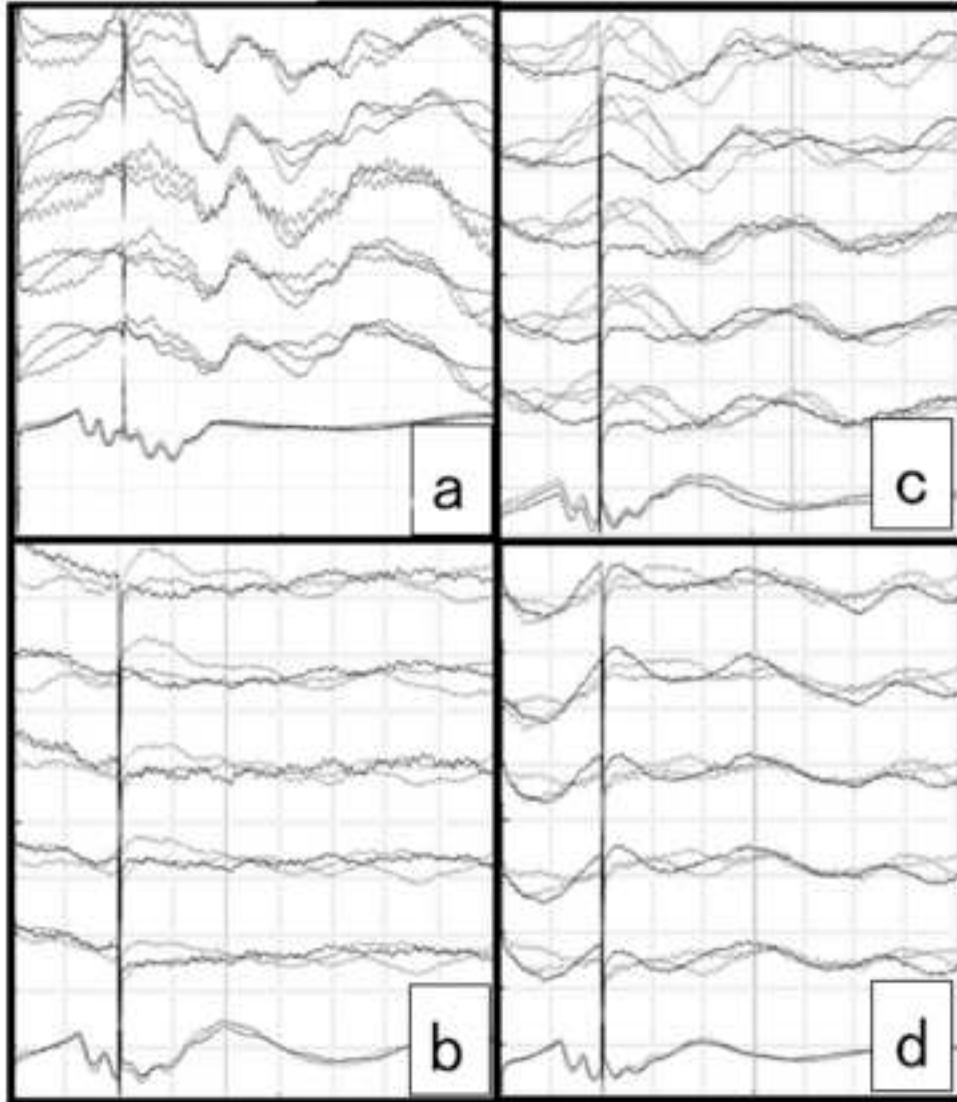


Fig. 3C



Channel of montage:

LT-A+

LO-A+

Oz-A+

RO-A+

RT-A+

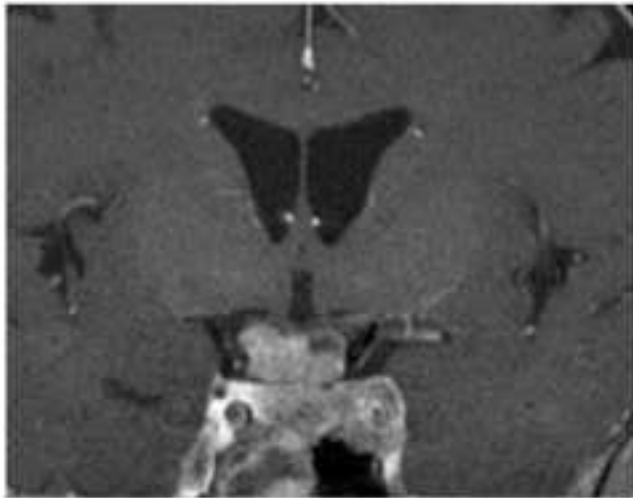ERG

One div.: 2 μ V/20mS

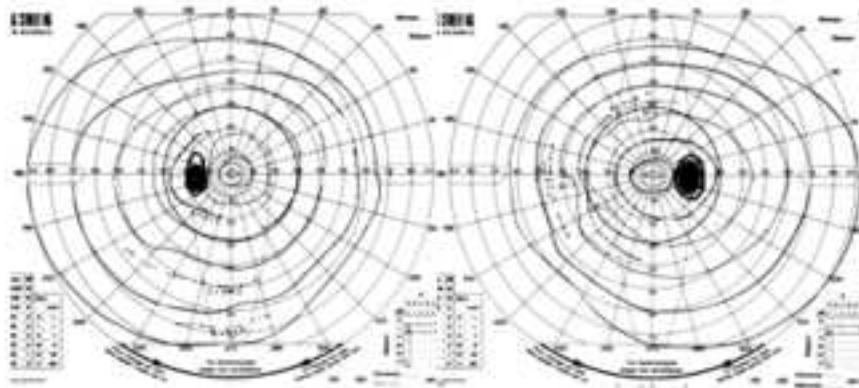
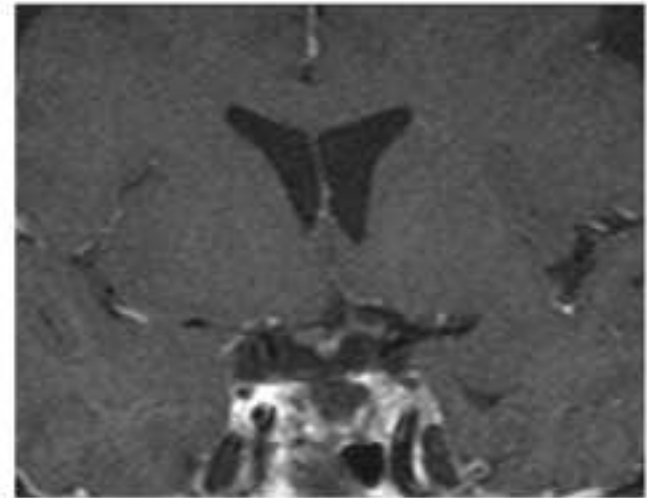
One div.: 20 μ V/20mS

Fig. 4 pre- and postoperative MRI, visual function and intraoperative VEP recording in patient 4

A




B



VA: 1.2

1.2



VA: 1.5

1.5

Fig. 4C

