

Central Neurocytoma Presenting With Massive Hemorrhage Leading to Coma

—Case Report—

Yuzo TERAOKAWA, Takashi TSURUNO*, Kenichi ISHIBASHI,
Yumiko OKADA*, Katsumi SHIMOTAKE*, and Takaho MURATA*

Department of Neurosurgery, Osaka City University Graduate School of Medicine, Osaka;

*Department of Neurosurgery, Suisyokai Murata Hospital, Osaka

Abstract

A 21-year-old man presented with a hemorrhagic central neurocytoma manifesting as acute onset of disturbance of consciousness and right hemiparesis. Computed tomography (CT) demonstrated a tumor in the left lateral ventricle during the course of evaluation for mental alteration 12 days before onset, but the tumor was left untreated because the patient refused to visit a neurosurgical institution. CT on admission revealed a large mass lesion located in the body of the lateral ventricle associated with massive intratumoral and intraventricular hemorrhage. He underwent emergent surgery for evacuation of the tumor with hematoma, and his neurological symptoms gradually recovered after surgery. The present case highlights the possibility of rapid deterioration of symptoms by massive hemorrhage from central neurocytoma. Surgical intervention should thoroughly be considered, if intratumoral hemorrhage is present, as hemorrhage from the central neurocytoma may lead to serious neurological complications.

Key words: central neurocytoma, intraventricular hemorrhage, intratumoral hemorrhage, brain tumor, MIB-1 index

Introduction

Central neurocytoma was first described in 1982 as a well-differentiated tumor of neuronal origin,⁸⁾ and is now classified as a grade II brain tumor according to the World Health Organization classification.¹⁴⁾ Central neurocytoma accounts for only 0.1–1.0% of all central nervous system tumors,¹⁸⁾ which are most often found in young adults.^{1,18)} Central neurocytoma is typically located in the lateral ventricle, representing approximately 10% of all intraventricular tumors.¹⁸⁾ Central neurocytoma usually manifests as increased intracranial pressure and hydrocephalus, or may occasionally be asymptomatic. Central neurocytoma with acute development of symptoms associated with hemorrhage is rare and not well understood.

We describe a case of central neurocytoma manifesting as intratumoral and intraventricular hemorrhage that caused acute onset of disturbance of consciousness and right hemiparesis.

Case Report

A 21-year-old right-handed man first presented to another hospital with a one-year history of mental alteration. Computed tomography (CT) of the brain revealed a homogeneously high-density mass lesion, 45 mm in maximum di-

ameter, located in the body of the left lateral ventricle (Fig. 1). The clinician at the prior hospital instructed the patient to consult a neurosurgeon for further evaluation and treatment, but he did not visit a medical institution and the lesion was left untreated. The patient suffered sudden onset of severe headache and disturbance of consciousness 12 days after the lesion was detected, and was taken to our hospital by ambulance. His past medical history was unremarkable.

On admission, blood pressure and heart rate were nor-

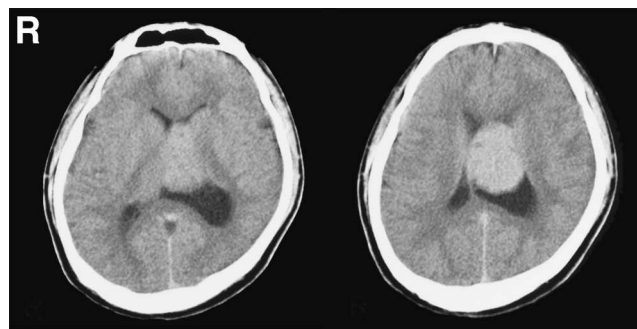


Fig. 1 Computed tomography scans obtained at another hospital showing a diffusely high-density mass lesion, 45 mm in maximum diameter, located in the body of the left lateral ventricle.

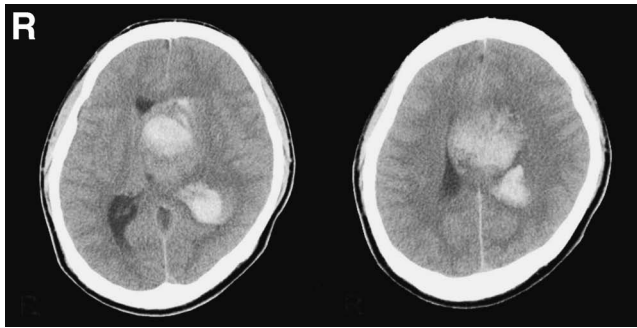


Fig. 2 Computed tomography scans on admission indicating an enlarged mass lesion, 56 mm in maximum diameter, in the left lateral ventricle associated with massive intratumoral and intraventricular hemorrhage.

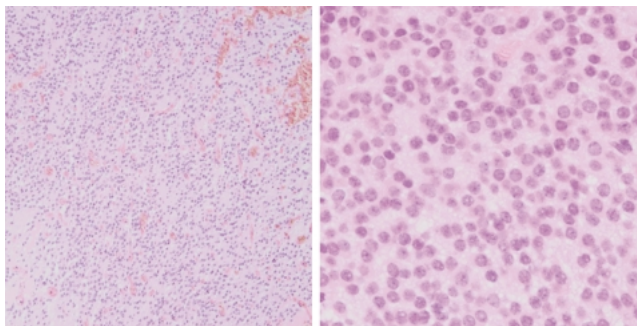


Fig. 3 Photomicrographs of the surgical specimen revealing neurocytoma with numerous small capillaries (left: hematoxylin and eosin stain, $\times 100$) and no malignant features (right: hematoxylin and eosin stain, $\times 400$).

mal, but neurological examination showed disturbance of consciousness (Japan Coma Scale III-100, Glasgow Coma Scale 6) and moderate right hemiparesis (manual muscle test 3/5). CT revealed an enlarged mass lesion, 56 mm in maximum diameter, located mainly in the left lateral ventricle associated with massive intratumoral and intraventricular hemorrhage. The lateral ventricle was slightly dilated (Fig. 2).

The patient underwent emergent surgery for evacuation of the tumor with hematoma via a transcallosal approach on the day of admission. Intraoperatively, the tumor appeared grossly to be a grayish mass. The mass was very fragile and hemorrhagic, and was attached to the ventricle wall and fed by numerous small vessels. Gross total removal of the tumor was achieved in a piecemeal fashion.

Histological examination found hypervascularity in some areas, but malignant features such as atypical nuclei and mitosis were absent (Fig. 3). Immunohistochemical staining was positive for both synaptophysin and neuron-specific enolase, and negative for glial fibrillary acidic protein and Olig2 (Fig. 4). No hemosiderin deposits or calcification was identified microscopically. MIB-1 staining for Ki-67 antigen was relatively high with a value of 3.4%. The histological diagnosis was neurocytoma.

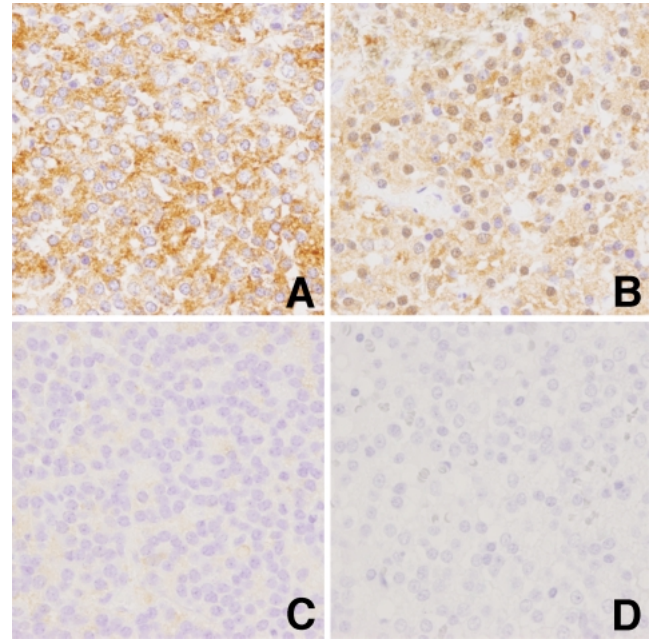


Fig. 4 Photomicrographs showing positive immunoreactivity for synaptophysin (A, $\times 400$) and neuron-specific enolase (B, $\times 400$), and negative immunoreactivity for glial fibrillary acidic protein (C, $\times 400$) and Olig2 (D, $\times 400$).

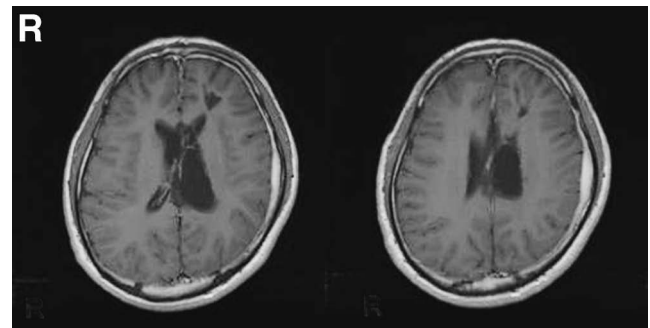


Fig. 5 T₁-weighted magnetic resonance images with contrast medium obtained 4 months after surgery demonstrating no evidence of a recurrent tumor.

No adjuvant therapy was performed, because intraoperative observation confirmed the tumor was grossly removed. Magnetic resonance (MR) imaging performed 4 months after surgery showed no evidence of a recurrent tumor (Fig. 5). The patient's consciousness and right hemiparesis improved gradually, and he was discharged, walking unaided, 6 months after surgery, although memory disturbance and slight right hemiparesis persisted.

Discussion

Spontaneous intracranial hemorrhage from brain tumors has been reported with an incidence ranging from 1.7–14.6%.^{11,13,24,30} The incidence of intracranial hemor-

Table 1 Characteristics of cases of hemorrhagic central neurocytomas

Case No.	Author (Year)	Age (yrs)/ Sex	Location of the tumor	Initial symptom associated with hemorrhage	Vascularization	MIB-1 index (%)	Remarks
1	Kubota et al. (1991) ¹²⁾	25/M	bil lateral ventricles	ND	abundant blood vessels	ND	died on the first operative day
2	Smoker et al. (1991) ²⁶⁾	26/M	lt lateral ventricle	grand mal seizure	not particular on angiograms	ND	—
3	Goergen et al. (1992) ⁷⁾	18/F	lt lateral ventricle	sudden headache	ND	ND	—
4	Kim et al. (1992) ¹⁰⁾	25/M	bil lateral and third ventricles	increased intracranial pressure	high vascularity on the basis of surgery	ND	—
5	Agranovich et al. (1993) ¹⁾	28/M	bil lateral ventricles	sudden severe headache	no evidence of neovascularity on angiograms	ND	repeated hemorrhage
6	Chang et al. (1993) ³⁾	?/M	?	ND	ND	ND	2 of 13 cases were associated with intratumoral hemorrhage
7	?/M	?/M	?	ND	ND	ND	repeated hemorrhage
8	Okamura et al. (1995) ²¹⁾	23/M	lt lateral ventricle	unconsciousness, severe headache after 2 yrs	numerous thin-walled capillaries	ND	—
9	Majos et al. (1997) ¹⁵⁾	40/M	third ventricle	brief syncope followed by severe headache	ND	ND	—
10	Namiki et al. (1998) ¹⁹⁾	50/M	bil lateral ventricles	gradual weakness in rt extremities	prominent small blood vessels with sclerotic walls	ND	15 yrs after initial treatment by partial removal and radiotherapy
11	Balko and Schultz (1999) ²⁾	51/M	lt lateral ventricle	found dead	numerous capillaries	<1	sudden death
12	Jamshidi et al. (2001) ⁹⁾	22/F	bil lateral ventricles	sudden severe headache	some blood capillaries	<2	—
13	Vates et al. (2001) ²⁹⁾	35/M	rt lateral ventricle	lt hemiparesis followed by disturbance of consciousness	tumor blush on angiogram	ND	coexistence of a fusiform aneurysm on a lateral lenticulostriate branch of rt middle cerebral artery
14	Gallina et al. (2005) ⁸⁾	68/F	fourth ventricle	sudden severe headache and vomiting	rich vascularization without angiopathy features	1	—
15	Smets et al. (2005) ²⁵⁾	25/M	rt lateral ventricle	sudden headache and vomiting	no vascular proliferation	few	coexistence of thrombocytopenia
16	Nishibayashi et al. (2006) ²⁰⁾	43/M	lt lateral ventricle	sudden headache	numerous thin-walled capillaries	quite low	—
17	Present case	21/M	lt lateral ventricle	sudden headache and coma	high vascularity	3.4	—

ND: not described, ?: unclear.

rhage from brain tumors other than pituitary adenomas was reported to be 2.9% (45 of 1550 cases).³⁰⁾ Of those 45 cases, 19 cases were asymptomatic, and only 11 cases (0.7% of the 1550 cases) were associated with rapid deterioration of symptoms. Consequently, acute development of neurological symptoms due to hemorrhage from brain tumor, as seen in the present case, is considered to be rare.

Sixteen cases of hemorrhage from central neurocytoma have been reported,^{1-3,6,7,9,10,12,15,19-21,25,26,29)} excluding three cases of hemorrhagic extraventricular neurocytoma.^{17,23,28)} Since the first case of central neurocytoma in 1982,⁸⁾ more than 500 cases of central neurocytoma have been reported in total,^{18,25)} so these 16 hemorrhagic cases account for approximately 3% of all reported central neurocytomas. Accordingly, hemorrhage from central neurocytoma may not be so rare as previously considered, although the reported number is still too small to be conclusive.

The characteristics of the present case and the previous 16 hemorrhagic central neurocytomas are summarized in Table 1. Fourteen patients (82%) were male, the left lateral ventricle was more predominantly involved than the right lateral ventricle, and two cases had hemorrhage more than once. Although several previous reports suggest that central neurocytoma has predominance in males^{5,18,27)} and in the left lateral ventricle,⁴⁾ the male preference of 82% appears to be much higher in hemorrhagic central neurocytomas. Furthermore, hypervascularity on the basis of angiography or histological examination was recognized in 10 of the 13 cases with documented vascularity (77%). Angiography showed marked or moderate vascularity in 10 (59%) of 17 cases of central neurocytoma.²²⁾ Hypervascularity may be more common in hemorrhagic central neurocytoma than in non-hemorrhagic central neurocytoma, but a large number of cases must be examined.

Several causative factors for hemorrhage from central neurocytomas have been proposed, such as the presence of hypertensive heart disease²⁾ or thrombocytopenia,²⁵⁾ thin-walled tumor vessels,²⁰⁾ and coexistence of an aneurysm originating from a feeding artery into the tumor.²⁹⁾ In the present case, hypervascularity was recognized by intraoperative observation and histological examination, as seen in previous cases of hemorrhagic central neurocytoma.^{2,6,9,10,12,19-21,29)} Hypervascularity may be attributable to the occurrence of hemorrhage in central neurocytoma. Rapid tumor growth is considered to be a contributing factor for hemorrhage in metastatic brain tumors.¹⁶⁾ Possibly the high proliferation potential may be related to hemorrhage in central neurocytoma as well. The MIB-1 labeling index, a marker of proliferation of the tumor, ranges from 0.3–8% in central neurocytoma,⁴⁾ but most cases of central neurocytoma had low proliferation potential with a MIB-1 value of less than 1%.¹⁸⁾ Several previous cases of hemorrhagic central neurocytoma had low proliferation potentials,^{2,6,9,20,25)} in contrast to our observation that MIB-1 index was relatively high, indicating high proliferation potential. Given these findings, a high MIB-1 index does not appear to be a definite predisposing factor for hemorrhage in central neurocytoma.

The present case is valuable in that CT was performed

before the hemorrhagic onset. Central neurocytomas are known to appear as an iso- or slightly high density mass on CT.^{7,10,17)} The most frequent feature of central neurocytoma is a pattern of punctuate, scattered high density with intratumoral multiple small cysts, giving a granular appearance.³¹⁾ This high density appearance is attributed to intratumoral calcifications seen on half of the cases of central neurocytoma, although high density areas on CT of the brain are generally associated with hemorrhage, calcification, or high cellularity lesions. In contrast, the CT before onset in our case showed the tumor as a diffuse and fairly high density mass without a granular appearance, which we believe was not typical for central neurocytoma. In fact, histological examination found no calcification in our case. MIB-1 index value was high, but cellularity of the tumor did not differ from non-hemorrhagic neurocytoma. The cause of such high density remains unclear because only CT was performed at the prior hospital, but we cannot eliminate the possibility that the tumor had already bled before the first consultation. MR imaging might have been helpful to rule out intratumoral hemorrhage in the present case.

The present case of hemorrhagic central neurocytoma manifested as massive hemorrhage leading to coma. Central neurocytomas are generally known to grow indolently, but the present case highlights the possibility of acute deterioration of symptoms by massive hemorrhage from central neurocytoma. Although we are still uncertain as to whether the high CT density of the lesion in the present case was related to the occurrence of hemorrhage, we consider that MR imaging should be performed without delay for atypical high density mass in the ventricle to rule out intratumoral hemorrhage, because hemorrhage from brain tumor may lead to serious neurological deterioration, as seen in the present case. Clinicians should be aware of this unique presentation of central neurocytoma, and surgical intervention should thoroughly be considered, if hemorrhage is demonstrated by neuroimaging examinations.

Acknowledgments

We are grateful to Dr. Mitsunori Kanagaki at the Department of Radiology, Kyoto University, Kyoto, Dr. Kenichi Wakasa at the Department of Pathology, Osaka City University Graduate School of Medicine, and Dr. Yoshiyasu Iwai at the Department of Neurosurgery, Osaka City General Hospital, Osaka, for their valuable comments in preparing this study.

Part of this study was presented orally at the regional meeting of the Japan Neurosurgical Society in April 2009.

References

- 1) Agranovich AL, Ang LC, Fryer CJ: Central neurocytoma: report of 2 cases and literature review. *J Neurooncol* 16: 47–53, 1993
- 2) Balko MG, Schultz DL: Sudden death due to a central neurocytoma. *Am J Forensic Med Pathol* 20: 180–183, 1999
- 3) Chang KH, Han MH, Kim DG, Chi JG, Suh DC, Kim SJ, Cha

- SH, Han MC: MR appearance of central neurocytoma. *Acta Radiol* 34: 520–526, 1993
- 4) Eng DY, DeMonte F, Ginsberg L, Fuller GN, Jaecle K: Craniospinal dissemination of central neurocytoma. Report of two cases. *J Neurosurg* 86: 547–552, 1997
 - 5) Ferreol E, Sawaya R, de Courten-Myers GM: Primary cerebral neuroblastoma (neurocytoma) in adults. *J Neurooncol* 7: 121–128, 1989
 - 6) Gallina P, Mouchaty H, Buccoliero AM, Di Lorenzo N: Haemorrhagic central neurocytoma of the fourth ventricle. *Acta Neurochir (Wien)* 147: 1193–1194, 2005
 - 7) Goergen SK, Gonzales MF, McLean CA: Interventricular neurocytoma: radiologic features and review of the literature. *Radiology* 182: 787–792, 1992
 - 8) Hassoun J, Gambarelli D, Grisoli F, Pellet W, Salamon G, Pellissier JF, Toga M: Central neurocytoma. An electron-microscopic study of two cases. *Acta Neuropathol* 56: 151–156, 1982
 - 9) Jamshidi J, Izumoto S, Yoshimine T, Maruno M: Central neurocytoma presenting with intratumoral hemorrhage. *Neurosurg Rev* 24: 48–52, 2001
 - 10) Kim DG, Chi JG, Park SH, Chang KH, Lee SH, Jung HW, Kim HJ, Cho BK, Choi KS, Han DH: Intraventricular neurocytoma: clinicopathological analysis of seven cases. *J Neurosurg* 76: 759–765, 1992
 - 11) Kondziolka D, Bernstein M, Resch L, Tator CH, Fleming JF, Vanderlinden RG, Schutz H: Significance of hemorrhage into brain tumors: clinicopathological study. *J Neurosurg* 67: 852–857, 1987
 - 12) Kubota T, Hayashi M, Kawano H, Kabuto M, Sato K, Ishise J, Kawamoto K, Shirataki K, Iizuka H, Tsunoda S, Katsuyama J: Central neurocytoma: immunohistochemical and ultrastructural study. *Acta Neuropathol* 81: 418–427, 1991
 - 13) Little JR, Dial B, Belanger G, Carpenter S: Brain hemorrhage from intracranial tumor. *Stroke* 10: 283–288, 1979
 - 14) Louis DN, Ohgaki H, Wiestler OD, Cavenee WK, Burger PC, Jouvet A, Scheithauer BW, Kleihues P: The 2007 WHO classification of tumours of the central nervous system. *Acta Neuropathol* 114: 97–109, 2007
 - 15) Majos C, Coll S, Pons LC: Central neurocytoma arising in the third ventricle. *Neuroradiology* 39: 270–272, 1997
 - 16) Mandybur TI: Intracranial hemorrhage caused by metastatic tumors. *Neurology* 27: 650–655, 1977
 - 17) McCutchen TQ, Smith MT, Jenrette JM, Van Tassel P, Patel SJ, Thomas CR Jr: Interparenchymal hemorrhagic neurocytoma: an atypical presentation of a rare CNS tumor. *Med Pediatr Oncol* 32: 440–446, 1999
 - 18) Mineura K: [Central neurocytoma]. *No Shinkei Geka* 28: 583–597, 2000 (Jpn, with Eng abstract)
 - 19) Namiki J, Nakatsukasa M, Murase I, Yamazaki K: Central neurocytoma presenting with intratumoral hemorrhage 15 years after initial treatment by partial removal and irradiation. *Neurol Med Chir (Tokyo)* 38: 278–282, 1998
 - 20) Nishibayashi H, Uematsu Y, Terada T, Itakura T: Neurocytoma manifesting as intraventricular hemorrhage—case report. *Neurol Med Chir (Tokyo)* 46: 41–45, 2006
 - 21) Okamura A, Goto S, Sato K, Ushio Y: Central neurocytoma with hemorrhagic onset. *Surg Neurol* 43: 252–255, 1995
 - 22) Paek SH, Kim JE, Kim DG, Han MH, Jung HW: Angiographic characteristics of central neurocytoma suggest the origin of tumor. *J Korean Med Sci* 18: 573–580, 2003
 - 23) Ritz R, Roser F, Bornemann A, Hahn U, Freudenstein D: Extraventricular neurocytoma presenting with intratumoral hemorrhage. *Clin Neuropathol* 24: 101–105, 2005
 - 24) Scott M: Spontaneous intracerebral hematoma caused by cerebral neoplasms. Report of eight verified cases. *J Neurosurg* 42: 338–342, 1975
 - 25) Smets K, Salgado R, Simons PJ, De Clercq R, De Smedt K, Cras P: Central neurocytoma presenting with intraventricular hemorrhage: case report and review of literature. *Acta Neurol Belg* 105: 218–225, 2005
 - 26) Smoker WR, Townsend JJ, Reichman MV: Neurocytoma accompanied by intraventricular hemorrhage: case report and literature review. *AJNR Am J Neuroradiol* 12: 765–770, 1991
 - 27) Tamiya T, Furuta T, Asari S, Nishimoto A: Central neurocytoma—case report. *Neurol Med Chir (Tokyo)* 30: 178–183, 1990
 - 28) Taylor CL, Cohen ML, Cohen AR: Neurocytoma presenting with intraparenchymal cerebral hemorrhage. *Pediatr Neurol* 29: 92–95, 1998
 - 29) Vates GE, Arthur KA, Ojemann SG, Williams F, Lawton MT: A neurocytoma and an associated lenticulostriate artery aneurysm presenting with intraventricular hemorrhage: case report. *Neurosurgery* 49: 721–725, 2001
 - 30) Wakai S, Yamakawa K, Manaka S, Takakura K: Spontaneous intracranial hemorrhage caused by brain tumor: its incidence and clinical significance. *Neurosurgery* 10: 437–444, 1982
 - 31) Wichmann W, Schubiger O, von Deimling A, Schenker C, Valavanis A: Neuroradiology of central neurocytoma. *Neuroradiology* 33: 143–148, 1991

Address reprint requests to: Yuzo Terakawa, M.D., Department of Neurosurgery, Osaka City University Graduate School of Medicine, 1-4-3 Asahi-machi, Abeno-ku, Osaka 545-8585, Japan.
e-mail: terakawa@msic.med.osaka-cu.ac.jp