

# Cerebral palsy in siblings caused by compound heterozygous mutations in the gene encoding protein C

CHOONG YI FONG<sup>1</sup> | ANDREW D MUMFORD<sup>2</sup> | MARCUS J LIKEMAN<sup>3</sup> | PHILIP E JARDINE<sup>1</sup>

**1** Department of Paediatric Neurology, Bristol Royal Hospital for Children, Bristol, UK. **2** Bristol Heart Institute, University of Bristol, Bristol Royal Infirmary, Bristol, UK.

**3** Department of Paediatric Neuroradiology, Bristol Royal Hospital for Children, Bristol, UK.

Correspondence to Dr Philip Jardine at the Department of Paediatric Neurology, Bristol Royal Hospital for Children, Level 6 UBHT Education Centre, Upper Maudlin Street, Bristol BS2 8AE, UK.  
E-mail: Philip.jardine@bristol.ac.uk

## PUBLICATION DATA

Accepted for publication 7th December 2009.

Published online 19th February 2010.

## LIST OF ABBREVIATIONS

*PROC* Protein C gene

PVHI Periventricular haemorrhagic infarction

We report two sisters with extensive bilateral periventricular haemorrhagic infarction (PVHI) causing cerebral palsy (CP). The older sister presented at 20 months with cortical visual blindness, spastic diplegia, and purpura fulminans. The younger sister presented aged 3 days old with apnoeas and multifocal seizures. She subsequently had global developmental delay, cortical visual blindness, spastic quadriplegia, epilepsy, and purpura fulminans at age 2 years. Neuroimaging of both siblings showed bilateral PVHI consistent with bilateral cerebral intramedullary venous thrombosis occurring at under 28 weeks' gestation for the older sister and around time of birth for the younger sister. At latest follow-up, the older sister (13y) has spastic diplegia at Gross Motor Function Classification System (GMFCS) level II, and the younger sister (10y) has spastic quadriplegia at GMFCS level IV. Both sisters showed partial quantitative reduction in plasma protein C antigen and severe qualitative reduction in plasma protein C anticoagulant activity. They were heterozygous for two independent mutations in the protein C gene (*PROC*). There was no other risk factor for CP. To our knowledge, this is the first family reported with compound heterozygous *PROC* mutations as the likely genetic cause of familial CP. This report adds to the list of known monogenic causes of CP.

Cerebral palsy (CP) describes a group of permanent disorders affecting the development of movement and posture, causing activity limitation, attributed to non-progressive disturbances that occurred in the developing fetal or infant brain.<sup>1</sup> CP is a disorder with multiple aetiologies.<sup>2</sup> CP due to perinatal stroke and congenital porencephaly is associated with some inherited prothrombotic states including protein C deficiency, factor V Leiden, and prothrombin G20210A polymorphisms.<sup>3–5</sup>

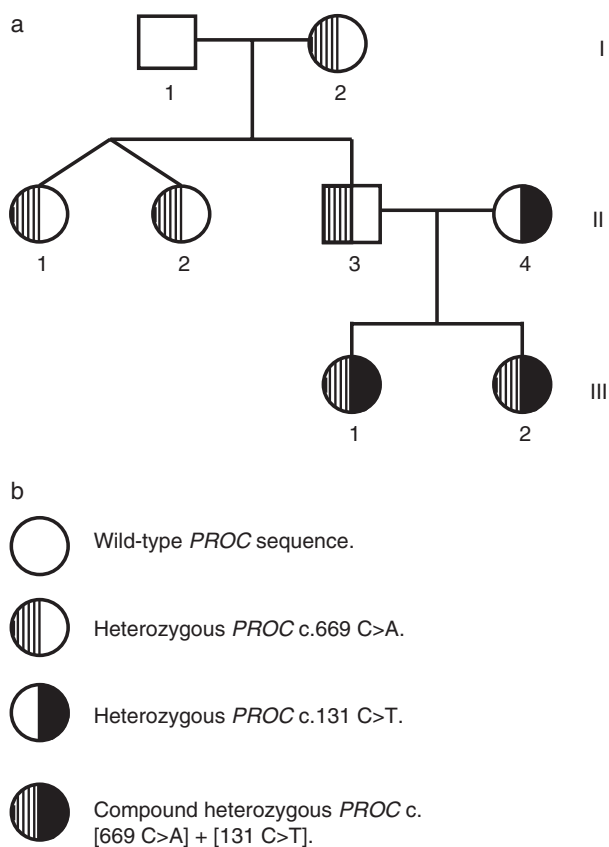
Protein C is a vitamin-K-dependent plasma glycoprotein that associates with the endothelial protein C receptor on vascular endothelium and is then activated by the thrombin–thrombomodulin complex during coagulation. Activated protein C with its cofactor protein S exerts an anticoagulant effect through inactivation of procoagulant factors Va and VIIIa.<sup>6</sup> Partial protein C deficiency (OMIM reference 612283) is associated with heterozygous mutations in the protein C gene (*PROC*) resulting in reduced anticoagulant activity and is a long-term risk factor for venous thromboembolic disease.<sup>7,8</sup> Severe protein C deficiency is a rare disorder that presents early in life with severe venous thrombosis including purpura fulminans.<sup>7,8</sup> Individuals with severe protein C deficiency are typically homozygous or compound heterozygous for *PROC* mutations. Protein C deficiency may arise from failure of pro-

tein C synthesis, resulting in a quantitative reduction in plasma protein C concentration (type I deficiency). Alternatively, there may be synthesis of dysfunctional protein C showing normal quantitative protein C antigen but reduced qualitative protein C anticoagulant activity (type II deficiency).<sup>6–8</sup>

We recently reported the molecular and genetic basis of two sisters with severe protein C deficiency showing two independent *PROC* point mutations associated with composite type I and type II protein C deficiency.<sup>9</sup> We now describe the detailed clinical and neuroradiological features of these two sisters. Parental consent has been given for publication of this case report.

## CASE REPORT

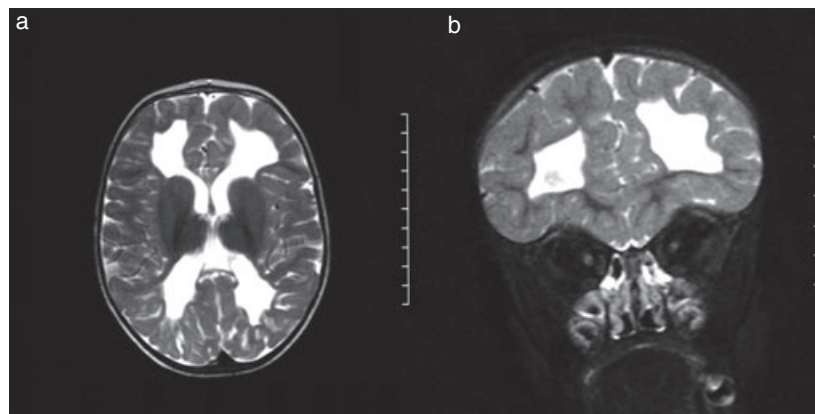
A 20-month-old female (Fig. 1, III 1,) presented with global developmental delay, cortical visual blindness, and spastic diplegia. She was born at term by spontaneous vaginal delivery. Her birthweight was 2.2kg with an Apgar score of 9 at 1 and 5 minutes. She had recurrent purpura fulminans from 16 months of age. Brain magnetic resonance imaging (MRI) at 22 months showed bilateral symmetrical extensive periventricular cystic porencephaly, characteristic of periventricular haemorrhagic infarction (PVHI) with no gliosis (Fig. 2a,b).



**Figure 1:** (a) Pedigree showing protein C (*PROC*) genotype in the affected siblings and their immediate family. (b) Shading reference for *PROC* genotype. *PROC* genotype numbering according to the *PROC* complementary DNA reference sequence NM\_000312.

Brain MRI changes in the elder sister were consistent with intrauterine bilateral cerebral intramedullary venous thrombosis at under 28 weeks' gestation.

A younger sister (Fig. 1, III, 2) was born at term 3½ years after her sister by spontaneous vaginal delivery. Her birth-weight was 2.6kg with an Apgar score of 9 at 1 and 5 minutes.



**Figure 2:** Brain magnetic resonance image of elder sister (Fig. 1, III.1). (a) T2-weighted axial image and (b) T2-weighted coronal image showing bilateral periventricular cystic porencephaly characteristic of periventricular haemorrhagic infarction with no gliosis.

### What this paper adds

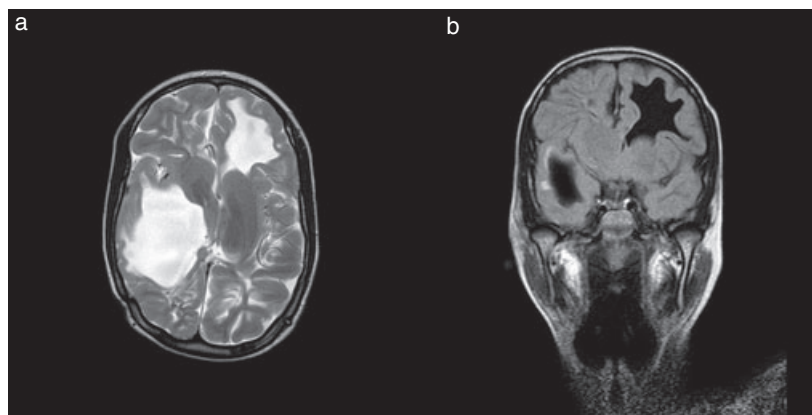
- Inherited thrombophilias can be a potential cause of CP.
- Detailed analysis of anticoagulant pathways should be considered in CP with either unexplained PVHI, especially in bilateral PVHI, familial CP, or in the presence of a family history of haemostatic disorders.

She presented at 3 days of age with apnoeas and multifocal seizures. Computed tomography of her brain showed extensive acute haemorrhagic infarction of deep white matter of the frontal, temporal, and parietal lobes bilaterally. Repeat computed tomography after 1 month showed progressive hydrocephalus with porencephaly bilaterally. She subsequently had a right ventricular–peritoneal shunt. At 2 years old she had global developmental delay, cortical visual blindness, spastic quadriplegia, epilepsy, and recurrent purpura fulminans. Follow-up brain MRI showed extensive bilateral PVHI (Fig. 3a,b). Some of the porencephaly was collapsed by ventricular–peritoneal shunt placement. Neuroimaging findings of this sibling were consistent with bilateral cerebral intramedullary venous thrombosis occurring around time of birth.

The parents of the affected sisters were non-consanguineous (Fig. 1). Their father (II.3) was asymptomatic but had a family history of adult-onset venous thromboembolic disease (I.2). Their mother (II.4) had no personal or family history of venous thromboembolic disease. Both pregnancies had no pregnancy-associated vascular complications and routine antenatal ultrasound was normal. Both sisters were small for gestational age at birth.

At presentation, both sisters had prolonged clotting times with consumptive coagulopathy typical of severe protein C pathway defect. Plasma protein C levels for both sisters at presentation showed reduced quantitative protein C level. As diagnosis of protein C deficiency was unknown during the acute phase, both sisters were managed with daily fresh frozen plasma infusion acutely until clinically stable. They were then anticoagulated with enoxaparin.

Plasma protein C assay levels were repeated for both sisters at 9 and 7 years old respectively during stable anticoagulation with enoxaparin. They both had partial reduction in quantita-



**Figure 3:** Brain magnetic resonance image of younger sister (III.2). (a) T2-weighted axial image and (b) T2-weighted fluid-attenuated inversion recovery coronal image showing bilateral periventricular cystic porencephaly characteristic of periventricular haemorrhagic infarction. Some of the porencephaly is collapsed by right ventricular–peritoneal shunt.

tive plasma protein C antigen but severe reduction in qualitative plasma protein C anticoagulant function consistent with a composite type I and type II protein C deficiency (Table I). The family study identified partial type I protein C deficiency in the father (II.3) and paternal relatives (Fig. 1). Partial type II protein C deficiency was identified in the mother (II.4).

Investigations for thrombophilia for all family members included plasma antithrombin activity, free protein S level, immunoglobulin-G and -M anticardiolipin antibodies, and lupus anticoagulant that were all normal. Genotyping for factor V Leiden and prothrombin G20210A polymorphisms showed wild-type sequence. Echocardiogram for both sisters was normal. Imaging studies of carotid arteries were not performed. The elder sister also had normal plasma homocysteine, autoimmune screen, immunoglobulins, complement levels, and urinary amino acid. Further metabolic investigations were not performed because a metabolic disorder was considered unlikely based on clinical and investigation findings.

Both sisters were heterozygous for missense nucleotide substitutions *PROC* c.131C>T and *PROC* c.669 C>A (National Center for Biotechnology Information reference sequence NM\_000312) predictive of Asn21Ile and Ser181Arg substitutions in the mature protein C protein respectively. The c.669

C>A substitution was identified in the father (II.3) and paternal relatives (Fig. 1). The c.131C>T substitution was identified in the mother (II.4) but in no other maternal relatives. Neither nucleotide variation was identified as polymorphic in the National Center for Biotechnology Information or ENSEMBL databases.

At latest follow-up, the elder sister (13y) has spastic diplegia at Gross Motor Function Classification System (GMFCS) level II, and the younger sister (10y) has spastic quadriplegia at GMFCS level IV.

## DISCUSSION

CP can be associated with the interaction of multiple risk factors; often there is no clear, single, causal factor.<sup>2</sup> Although CP rarely recurs in families, most affected children do not show clear patterns of monogenic inheritance. Prothrombotic abnormalities (including protein C deficiency) appear to be more common in perinatal stroke<sup>10–12</sup> than in childhood stroke,<sup>13,14</sup> which suggests inherited prothrombotic risk factors are more important in perinatal stroke. This can be attributed to the immature neonatal coagulation system, resulting in increased susceptibility to thrombus formation, particularly when concomitant inherited fetal thrombophilia is present.<sup>15</sup>

**Table I:** Clinical and laboratory characteristics of the study kindred

Individual	Clinical phenotype	Protein C antigen (units per decilitre) <sup>a</sup>	Protein C anticoagulant activity (units per decilitre) <sup>b</sup>
I.1	Asymptomatic	121	104
I.2	Adult onset venous thromboembolic disease	54	58
II.1	Asymptomatic	56	49
II.2	Asymptomatic	51	51
II.3	Asymptomatic	48	56
II.4	Asymptomatic	95	48
III.1	CP + purpura fulminans	42	9
III.2	CP + purpura fulminans	35	12

<sup>a</sup>Reference range for protein C antigen assay 70 to 140 units per decilitre. <sup>b</sup>Reference range for protein C anticoagulant function assay 70 to 130 units per decilitre.

Aetiological delineation of CP between stroke, non-stroke CP remains difficult, and there is insufficient evidence at present to suggest whether there is any difference in thrombophilic risk factors between these two subgroups.

We consider that the reported sisters demonstrate that inherited protein C dysfunction is a cause of CP and not merely a risk factor. In this kindred, CP segregated with a complex functional protein C defect and with compound heterozygous *PROC* mutations c.669C>A (paternal origin; predictive of Ser181Arg) and c.131C>T (maternal origin; predictive of Asn2Ile). The predicted Ser181Arg substitution segregated with partial type I protein C defect (Table I). Consistent with partial type I protein C deficiency, one paternal relative had adult-onset venous thromboembolic disease. The predicted Asn2Ile substitution segregated with type II protein C deficiency (Table I). In the affected sisters, co-inheritance of type I and type II protein C deficiency together caused a severe reduction in qualitative protein C anticoagulant activity similar to previous reported individuals with purpura fulminans.<sup>16,17</sup>

On brain MRI, both sisters showed bilateral periventricular cystic porencephaly with loss of almost full thickness of cerebral white matter. The imaging appearances are characteristic of bilateral PVHI (Figs 2 and 3). Acute PVHI has been shown to have an appearance consistent with a combination of intravascular thrombi and perivascular haemorrhage along the course of the medullary veins within the area of infarction.<sup>18</sup> PVHI imaging findings are typically seen in preterm infants with germinal matrix haemorrhage causing venous infarctions that are usually unilateral. The extensive bilateral distribution of white matter loss in the sisters is an unusual feature not typically seen in PVHI of preterm infants. The neuroimaging appearance of both sisters is, therefore, consistent with bilateral cerebral intramedullary venous thrombosis, and it is likely that the severe defect in protein C anticoagulant activity contributed significantly to this event.

Activated protein C also has important anti-inflammatory and cytoprotective effects in vivo.<sup>19</sup> This activity requires activated protein C binding to endothelial protein C receptor to enable proteolytic activation of the protease activated receptor-1 (PAR-1) on vascular endothelium and other cells. PAR-1 then mediates endothelial barrier stabilization, inhibition of inflammatory cytokine release, and anti-apoptotic pathways, particularly in the vasculature of the central nervous system. In these sisters, we have shown that the only circulating protein C in plasma is that containing the Asn2Ile substitution that has defective endothelial protein C receptor binding.<sup>9</sup> We speculate that the initiating event for the brain injury in the sisters is likely to have been cerebral intramedullary venous thrombosis, but that an additional defect in the activated protein C anti-inflammatory pathway further contributed to their cerebral injury.

## CONCLUSION

To our knowledge, this is the first family reported with co-inheritance of two independent *PROC* mutations as the likely genetic cause of familial CP in siblings. This adds to current evidence that inherited thrombophilias play a contributory role in the development of CP in some individuals, and that single gene disorders are a potential cause of CP. It is important to realize that both quantitative and qualitative tests are available for protein C testing and that both forms of protein C deficiencies may arise. Further population-based studies examining the association of CP with genetic variations in *PROC* are required. We suggest that detailed analysis of natural anticoagulant pathways should be considered in individuals with CP with unexplained PVHI, especially when this is bilateral, familial CP, or in the presence of a family history of haemostatic disorders.

## REFERENCES

- Rosenbaum P, Paneth N, Leviton A, Goldstein M, Bax M. A report: the definition and classification of cerebral palsy April 2006. *Dev Med Child Neurol* 2007; **49**: (Suppl. 109) 8–14.
- Stanley F, Blair E, Alberman E. Cerebral Palsies: Epidemiology and Causal Pathways. Clinics in Developmental Medicine No. 151. London: Mac Keith Press, 2000.
- Gibson CS, MacLennan A, Hague WM, et al. Associations between inherited thrombophilias, gestational age and cerebral palsy. *Am J Obstet Gynecol* 2005; **193**: 1437.
- Golomb MR, MacGregor DL, Domi T, et al. Presumed pre- and perinatal arterial ischaemic stroke: risk factors and outcomes. *Ann Neurol* 2001; **50**: 163–8.
- Debus O, Koch HG, Kurlmann G, et al. Factor V Leiden and genetic defects of thrombophilia in childhood porencephaly. *Arch Dis Child Fetal Neonatal Ed* 1998; **78**: 121–4.
- Dahlbäck B. Advances in understanding the pathogenic mechanisms of thrombophilic disorders. *Blood* 2008; **112**: 19–27.
- Reistma PH, Poort SR, Bernandi F, et al. Protein C deficiency: a database of mutations. For the Protein C & S Subcommittee of the Scientific and Standardization Committee of the International Society of Thrombosis and Haemostasis. *Thromb Haemost* 1993; **69**: 77–84.
- Reistma PH, Bernandi F, Doig RG, et al. Protein C deficiency: a database of mutations, 1995 update. On behalf of the Subcommittee on Plasma Coagulation inhibitors of the Scientific and Standardization Committee of the ISTH. *Thromb Haemost* 1995; **73**: 876–89.
- Preston RJS, Morse C, Murden SL, Brady KS, O'Donnell JS, Mumford AD. The protein C  $\omega$ -loop substitution Asn2Ile is associated with reduced protein C anticoagulant activity. *Br J Haematol* 2009; **144**: 946–53.
- Mercuri E, Cowan F, Gupta G, et al. Prothrombotic disorders and abnormal neurodevelopmental outcome in infants with neonatal cerebral infarction. *Pediatrics* 2001; **107**: 1400–4.
- Gunther G, Junker R, Strater R, et al. for the Childhood Stroke Study Group. Symptomatic ischaemic stroke in full-term neonates: role of acquired and genetic prothrombotic risk factors. *Stroke* 2000; **31**: 2437–41.
- Senbil N, Yuksel D, Yilmaz D, Gurer YKY. Prothrombotic risk factors in children with hemiplegic cerebral palsy. *Pediatr Int* 2007; **49**: 600–2.
- Ganesan V, McShane MA, Liesner R, Cookson J, Hann I, Kirkham FJ. Inherited prothrombotic states and ischaemic stroke in childhood. *J Neurol Neurosurg Psychiatry* 1998; **65**: 508–11.
- McCull MD, Chalmers EA, Thomas A, et al. Factor V Leiden, prothrombin 20210G → A and the MTHFR C677T mutations in childhood stroke. *Thromb Haemost* 1999; **81**: 690–4.
- Raju TNK, Nelson KB, Ferriero D, Lynch JK, NICHD-NINDS Perinatal Stroke Workshop Participants. Ischaemic perinatal stroke: summary of a workshop sponsored by the National Institute of Child Health and Human Development and the National Institute of Neurological Disorders and Stroke. *Pediatrics* 2007; **120**: 609–16.
- Marlar RA, Neumann A. Neonatal purpura fulminans due to homozygous protein C or protein S deficiencies. *Semin Thromb Hemost* 1990; **16**: 299–309.

17. Marlar RA, Montgomery RR, Broekmans AW. Diagnosis and treatment of homozygous protein C deficiency. Report of the working party on Homozygous Protein C deficiency of the Subcommittee on Protein C and Protein S, International Committee on Thrombosis and Haemostasis. *J Pediatr* 1989; **114**: 528–34.
18. Counsell SJ, Maalouf EF, Rutherford MA, Edwards AD. Periventricular haemorrhagic infarct in a preterm neonate. *Eur J Paediatr Neurol* 1999; **3**: 25–8.
19. Mosnier LO, Zlokovic BV, Griffin JH. The cytoprotective protein C pathway. *Blood* 2008; **109**: 3161–72.

## Book Review: Developmental Disability and Ageing

Edited by Gregory O'Brien and Lewis Rosenbloom  
 London: Mac Keith Press,  
 2009 £20.00 (Paperback), 131 pages  
 ISBN 978-1-898683-61-2

A book on ageing for people with developmental disability has been long awaited.

This book, edited by Professor Gregory O'Brien and Dr Lewis Rosenbloom, has addressed some of the unexplored areas of the ageing process in people with developmental disability. The emphasis is on helping the clinician to achieve a better understanding of the ageing process. The book gives clear practical suggestions on clinical practice with case examples and descriptions of the current evidence-base.

The well-written chapters cover a range of clinical topics in relation to the ageing process and developmental disorder, dementia, Down syndrome, cerebral palsy, and other genetic conditions. Chapters are also devoted to drug treatment of common problems and living with ageing and developmental disorder.

Chapter 1 provides an excellent overview of the ageing process in people with developmental disability. The second chapter concentrates on dementia (with case vignettes) and highlights difficulties in the assessment process owing to changing needs. Particular emphasis has been placed on the area of differential diagnosis and the challenges clinicians face in working through this range of possibilities.

Chapter 3 highlights the physical and cognitive changes in people with Down syndrome. I was particularly impressed with the efforts made to separate issues related to ageing in Down syndrome from those of dementia.

The issue of ageing in people with cerebral palsy, is discussed in Chapter 4. The impact on physical health and cognition is highlighted, along with neuromuscular and orthopaedic changes. The main attraction of this chapter is the description of intervention opportunities, with practical suggestions for everyday care as well as specific interventions useful for problems encountered.

Chapter 5 is devoted to the process of ageing in people with developmental disorders other than Down syndrome. This chapter attempts to bring valuable information from many areas together in one section and classifies the syndromes as progressive and non-progressive disorders. The focus of this chapter is on how the ageing process influences a person's behaviour and functioning over time.

The next chapter is devoted to general guidelines on the use of drugs in the ageing population, with a focus on the use of anti-dementia medication, whilst the last chapter concentrates on living with ageing with special emphasis on coordinated care and intervention. There is guidance on working with carers, improving general health, use of psychosocial interventions, and environmental considerations. This chapter provides good case examples and emphasis has been given to combining approaches that are generally used for older people and those with developmental disability.

Overall, I feel that this book is extremely useful to the clinician involved in providing care for the older population with developmental disabilities.

**Sabyasachi Bhaumik**

Faculty of Psychiatry of Learning Disability,  
 The Royal College of Psychiatrists, London, UK.

doi: 10.1111/j.1469-8749.2009.03524.x