

## Acoustic neuroma (schwannoma) surgery 1978-1990

J. E. M. DUTTON F.R.C.S., R. T. RAMSDEN F.R.C.S., R. H. LYE F.R.C.S., K. MORRIS F.R.C.S.,  
A. O. KEITH F.R.C.S., R. PAGE F.R.C.S., J VAFADIS F.R.C.S. (Manchester)

### Abstract

A series of 151 patients with 154 acoustic schwannomas have been operated upon in Manchester Royal Infirmary by a joint Otolological and Neurosurgical team, employing either the translabyrinthine or the sub-occipital approach. The perioperative mortality rate was 3 per cent. Anatomical preservation of the facial nerve was achieved in 89 per cent of tumour removals and a good to normal functional result in 79 per cent of cases. Attempts at hearing preservation have been unsuccessful, largely because of the small number of patients in the series in whom useful hearing was present preoperatively. Complications included major brain stem ischaemia (1.2 per cent), CSF fistula (5 per cent) and facial dysaesthesia (7 per cent). The incidence of mortality and morbidity is directly related to tumour size and to the experience of the surgeons. A number of patients experienced an unusual type of post-operative dreamlike state which appeared to be a form of hypnagogic hallucination, and the possible neurophysiological mechanism responsible for this phenomenon is discussed. The continuing failure to attain the ideal of early diagnosis is lamented, and the importance of a flexible bidisciplinary surgical approach emphasized.

### Introduction

The twentieth century has seen an evolving pattern in the management of acoustic neuromas. In the first two or three decades the picture was one of almost unmitigated gloom, with large tumours presenting late, and removed with such dreadful results that even to consider operating on a fit person with a small tumour was regarded as inappropriate. The first great advance came with Cushing's intracapsular operation in the thirties but total tumour removal with minimal mortality and morbidity only became a realistic goal much later with the advent of microsurgical techniques, improvements in neuroanaesthetic practice and advances in our understanding of the anatomy, physiology and pathophysiology of the brain stem and surrounding structures. The next quest was for preservation of the facial nerve, previously regarded as expendable, and in the last ten years, maintenance of useful hearing in certain cases has become possible. Sadly, however, early diagnosis, which has always appeared to be imminent with each new audiological or radiological advance, remains elusive.

One of the greatest advances in the management of these tumours has been the co-operation between the neurosurgeon and the otologist, leading to the emergence of the neuro-otologist or otoneurologist depending on one's point of view, and to the team approach to tumour surgery. During the last twelve years (March 1978-March 1990), the Departments of Otolaryngology and Neurosurgery at Manchester Royal Infirmary have collaborated in the management of a series of patients with acoustic neuromas. This article describes the results of these efforts.

### Material (Table 1)

One hundred and fifty one patients (89 females: 62 males. F: M ratio = 1.5:1) with 154 operated tumours have undergone a total of 161 operations for histologically proven acoustic schwannomas. Age at presentation ranged from 15 to 79 years; the distribution is shown in Figures 1 and 2. Total removal was achieved in 142 tumours, including six for which staged surgery was performed. Staging was not a premeditated philosophy in any instance but was decided upon during primary surgery if changes in vital signs led to concern on the part of the anaesthetist. This situation usually arose when dealing with the residual part of a large tumour firmly adherent to the brain stem. If the primary procedure had to be abandoned prematurely, at least three months were allowed to elapse before a second operation was performed. During this time, the distorted brain stem was found to resume its normal position and the tumour remnant to become less adherent to it, thus facilitating eventual removal (Figs. 3 a,b,c).

"Unplanned" subtotal removal was performed in six patients because of anaesthetic problems. Of these one died perioperatively (see below) and one two years later of unrelated disease. The remainder are under regular

TABLE I  
patient data

Acoustic neuromas March 1978-March 1990	
Total operated patients (Males = 62: Females = 89)	151
Total operated tumours	154
Operations (TL = 89: SO = 72)	161
No surgery patients	9

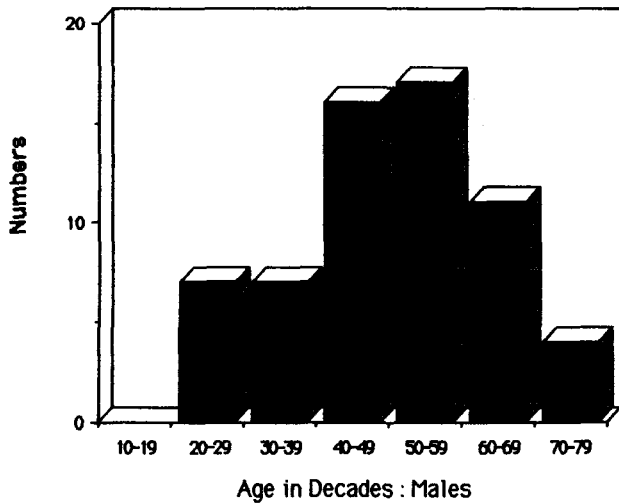


FIG. 1

Decade distribution of male patients.

review. *Planned* subtotal removal was carried out in a further six patients with large tumours, five because they were old or infirm, and one because it was hoped to preserve hearing in an only hearing ear. These patients continue to be kept under review with annual CT surveillance. Further surgery has not yet been necessary in any of these six patients although one has died of unrelated disease. The "total tumour removal" number of 142 includes 21 cases in whom it was necessary to leave on the brain stem or facial nerve a tiny portion of capsule manipulation of which caused major vital sign changes. These tumour rests were coagulated with the bipolar diathermy. These patients have been followed up with regular CT scans for periods up to 12 years without evidence of regrowth; however the significance of these cases, in the light of recent MR : Gd DTPA studies (Pace-Balzan *et al.* in preparation), will be discussed later in this paper. Of the 151 patients only one case (0.6 per cent) of true tumour *recurrence* has been observed, and that was not in one of the patients in whom such a tiny fragment was known to have been left behind. It is important to define what one means by the term "*recurrence*", and the authors regard it as the reappearance of tumour when in the opinion of the surgeons total re-

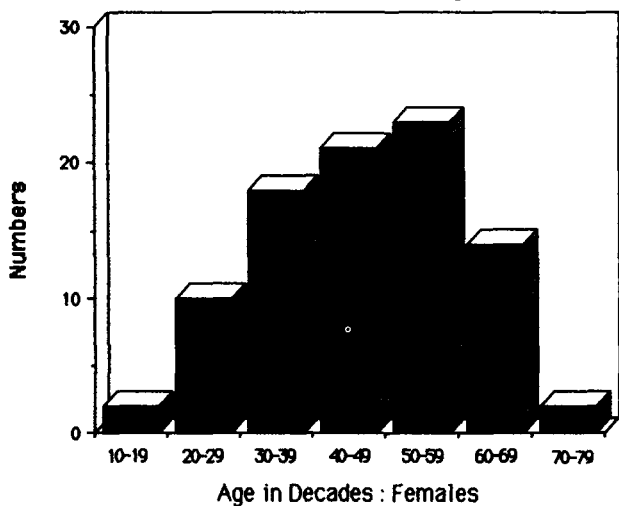


FIG. 2

Decade distribution of female patients.

moval had been achieved. Regrowth of tumour when a subtotal removal was knowingly performed should not be regarded as *recurrence*, but as "*regrowth*".

During this period we have seen an additional nine patients from whom surgery has been withheld. Six of these are elderly with very small lesions, and three are patients with tumours in their only hearing ears, *e.g.* the second side of a bilateral case. These patients have not been included in the analysis.

Eighty-nine translabyrinthine and 72 suboccipital approaches have been performed. In the early days of our collaboration there was a preponderance of suboccipital operations (26 out of the first 33) but as the neurosurgeons gained familiarity with the translabyrinthine approach the situation reversed. The translabyrinthine approach is at present employed for most tumours up to 4 cm in diameter, and the suboccipital approach larger lesions or if hearing preservation is to be attempted. The middle fossa approach has not been used.

*Preoperative tumour size* (Table II and Fig. 4): The 154 tumours were classified as intracanalicular (N = 9 : 5 per cent), up to and including 2.5 cm extracanalicular diameter (N = 72 : 46 per cent), 2.5 cm–4 cm (N = 48 : 31 per cent), and greater than 4 cm (N = 23 : 15 per cent). In addition there was one intravestibular schwannoma (Birzgalis and Ramsden, 1991) and one acoustic schwannoma with intrapetrous but no intracranial extension.

## Results

### Perioperative mortality

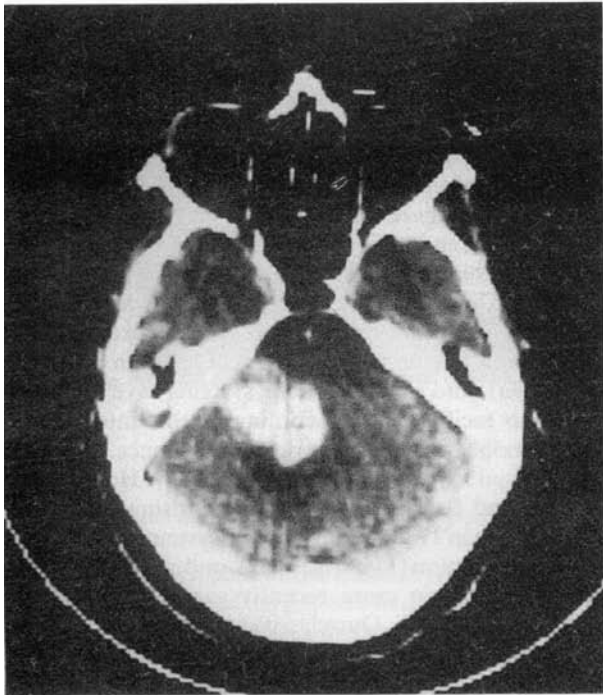
There have been five perioperative deaths in this series (3 per cent). Scrutiny of these individually may help to determine factors which might have been avoidable and so influence future practice.

*Patient 1* This 76-year-old man with a history of cardiovascular disease presented with a 5 cm tumour which was removed totally with preservation of the facial nerve via a suboccipital approach, the operation taking approximately 8 hours, at the end of which he died from a supratentorial subarachnoid haemorrhage without regaining consciousness. This case occurred early in the series. The management of this patient would now be a subtotal removal via a translabyrinthine approach.

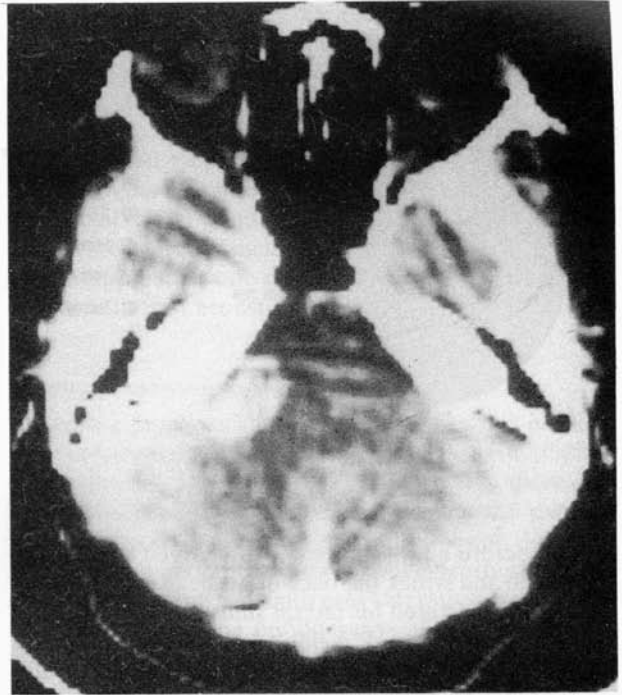
*Patient 2* This was a 54-year-old lady with hitherto well controlled bronchial asthma who died in the respiratory care unit in status asthmaticus ten days after the uneventful removal of a 3 cm tumour.

*Patient 3* This 65-year-old man developed bronchopneumonia and died approximately one week after the total removal of a 3.5 cm tumour. At the time of surgery some difficulty was experienced in separating the tumour from the lower cranial nerves, and vagal damage with aspiration could have predisposed to his pneumonia. Early tracheostomy might have provided protection for the airway.

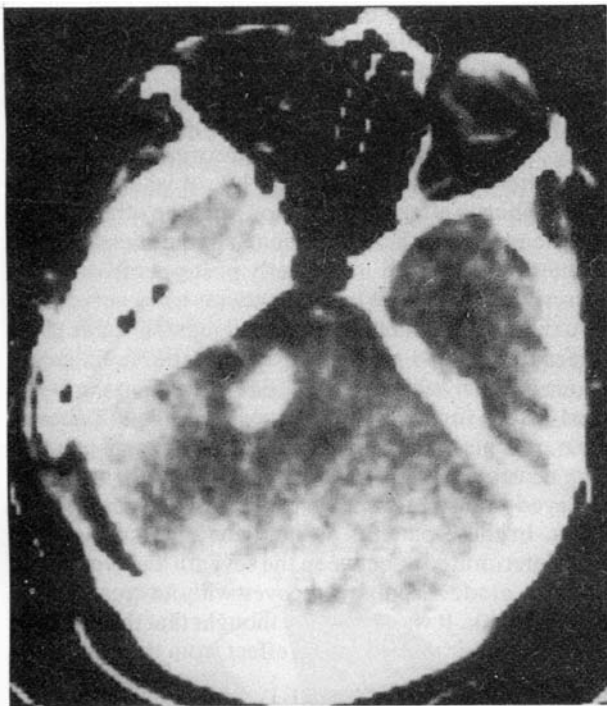
*Patient 4* This 24-year-old woman presented with a 4.5 cm acoustic schwannoma associated with an ipsilateral petrous ridge meningioma, a contralateral cerebel-



(a)



(c)



(b)

TABLE II  
tumour size data

Tumour size (N = 154)	
IC	9
≤2.5 cm	72
2.5-4 cm	48
>4 cm	23
Intravestibular	1
Intrapetrous	1

FIG. 3

Staged removal of large acoustic neuroma. The large tumour shown in (a) was partially removed via the suboccipital route and the residual fragment is seen on the brain stem (b). Three months later (c), the brain stem has shifted and the tumour remnant has come into contact with the petrous bone. It was subsequently removed by a translabyrinthine approach.

lopontine angle tumour and raised intracranial pressure when twenty-four weeks pregnant. Intracranial surgery was delayed until after the thirty-fourth week when her child was delivered by Caesarian section. Her acoustic schwannoma and meningioma were removed via a suboccipital approach. At the end of a prolonged but uneventful procedure she sustained a brain stem infarct and died without regaining consciousness.

*Patient 5* This 55-year-old man had an intrameatal tumour removed via the suboccipital approach with total preservation of his excellent pre-operative hearing.

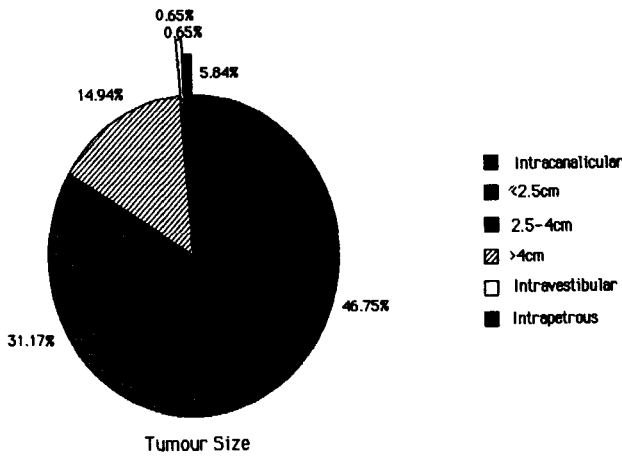


FIG. 4  
Tumour size at presentation.

Shortly before he was due to be discharged from hospital, he fell and struck the back of his head on the corner of his bed, lacerated his lateral sinus and died of intracranial haemorrhage. It is unlikely that this would have occurred if the tumour had been removed via the translabyrinthine route.

*Brain stem damage*

Major damage to the brain resulting from vascular compromise was seen in two patients, one of whom suffered a fatal infarction five months after surgery to remove a 5 cm tumour. A second patient with a 4 cm lesion suffered an immediate post-operative lateral medullary syndrome, from which he eventually made a reasonable recovery being left with increased spasticity in his limbs which prevented him from returning to work. Two further patients suffered some residual ataxia which prevented them from returning to their previous level of recreational activity (e.g. one was unable to dance).

*CSF fistula*

Eight patients developed a post-operative cerebrospinal fluid fistula requiring a further surgical procedure (5 per cent). Of these, six had had a translabyrinthine and two a suboccipital removal. Four further patients who had had a posterior fossa approach developed a pseudomeningocele requiring CSF diversion procedures. Meningitis occurred in four patients three of whom had had a CSF leak, and in two instances ventriculitis developed. In all cases the infection responded promptly to treatment with antibiotics and there was no residual deficit.

*Facial nerve function*

In our assessment of facial nerve function, no patient

TABLE III  
complications

Death	5	3%
Brain stem syndrome	2	1.2%
CSF fistula	8	5%
Meningitis	4	2.4%
Facial dysaesthesia	12	7%
Temporary neuropraxia	3	1.9%
Donor site infection	2	1.2%

has been included who was operated on after March 1989. This was to allow a period of one year for recovery in function in those nerves in which degeneration had occurred. It is our experience that little further improvement will occur in such a nerve after that interval. One hundred and thirty three tumours are therefore included in this part of the analysis. Many reports over the years have quoted figures for facial nerve preservation, by which has been implied anatomical preservation of the nerve. In this series 118 out of 133 facial nerves were thought to have been preserved in anatomical continuity (89 per cent). It is however much more meaningful to report facial nerve results in terms of function (Moffat *et al.*, 1989a), and several grading systems have been proposed to facilitate the recording of this information, though none has gained universal acceptance. The most widely used scheme is that suggested by the House group (House and Brackmann 1985), comprising six grades. Prior to that in 1982, we proposed a system based on five grades of function (Lye *et al.*, 1982), and a broadly similar scheme has been more recently suggested by Bentivoglio *et al.* (1988). Our classification is listed in Table IV. It differs from that of House and Brackmann in that those authors divide our Group 3 into two subgroups, defined as Moderate Dysfunction and Moderately Severe Dysfunction.

Figures 5 and 6 indicate the results in this series. It will be seen that the largest single group of patients fall into Grade 1, i.e. have normal facial function (N = 56:43 per cent), and that the majority of patients have facial function of Grade 3 or better, i.e. acceptable to normal (N = 104: 79 per cent). Five patients were unassessable; two were lost to follow-up (LTFU), of whom one emigrated shortly after her operation, and the other refused to attend for further outpatient appointments. Three further patients died in the early post-operative period (cases 1, 2 and 4 above). Eight patients had a nerve graft. Four had an immediate intracranial repair (2 cable graft, 1 rerouting, and 1 reimplantation into the brain stem). Three of them achieved Grade 3 function, but the fourth died before function could be assessed (case 2 above). Four patients underwent a delayed hypoglossal or accessory anastomosis and none attained better than grade 4. Delayed transient facial weakness was seen in nine cases. In these patients an immediate good to normal face deteriorated at between the seventh and tenth days, often to grade 4, only to recover without treatment in about a week. It was originally thought that this might be due to a physical or chemical effect from the abdominal

TABLE IV  
facial nerve grading  
(Lye *et al.* 1982)

Grade 1	Normal facial function.
Grade 2	Full facial movements but delayed blink, or crocodile tearing, or dry eye, or subjective taste disturbance. Full facial movements with minimal synkinesis. Minimal facial weakness.
Grade 3	Moderate facial weakness.
Grade 4	Moderate weakness but permanent tarsorrhaphy necessary. Severe weakness, but muscle tone present.
Grade 5	Total paralysis.

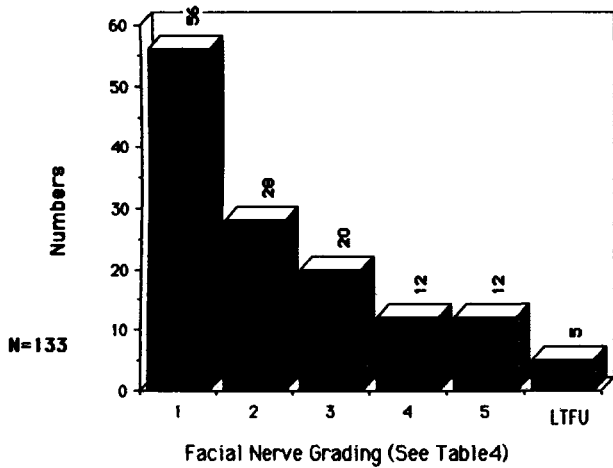


FIG. 5 Overall facial nerve function (FU > 1 year).

fat graft used in closure of the translabyrinthine defect, but the fact that two of the patients had been operated by the suboccipital route makes this suggestion untenable. One patient who achieved a Grade 3 result displayed marked wasting of the temporalis muscle which failed to recover, suggesting an anomalous innervation of that muscle by the facial rather than the trigeminal nerve.

If facial nerve function is analysed in relation to tumour size, it is clear that the smaller tumours are associated with a more favourable outcome. (Fig 7). In patients with tumours of 2.5 cm or smaller, facial nerve function was Grade 1 in 60 per cent, Grade 1 or 2 in 89 per cent and Grade 3 or better in 96 per cent of cases. When the tumour was larger than 2.5 cm these figures fell to 24 per cent, 44 per cent and 66 per cent respectively.

*Facial dysaesthesia*

Twelve patients (7 per cent) had a demonstrable but slight alteration in facial sensation following tumour removal. Ten had had pre-operative evidence of trigeminal involvement with tumours of 2.5 cm-6 cm diameter. Two patients with small tumours (<2.5cm) and no pre-operative signs of trigeminal involvement have slight

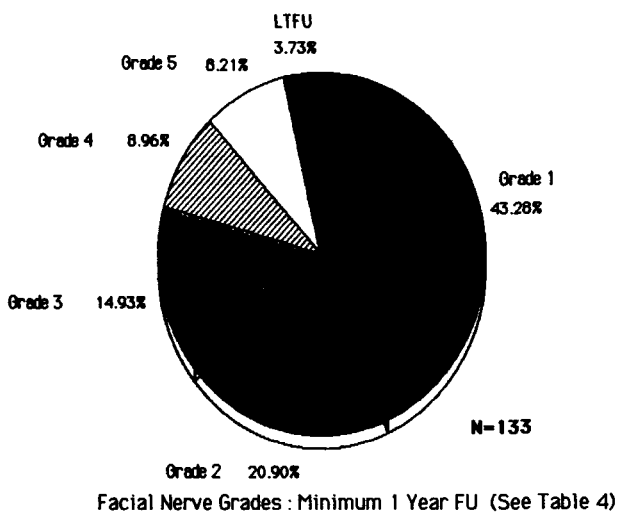


FIG. 6 Overall facial nerve function as percentage. (FU > 1 year).

residual sensory changes. Of the twelve patients, five continue to experience troublesome symptoms: two have anaesthesia dolorosa with a coexisting total facial paralysis, and three patients with Grade 4 or Grade 5 facial nerve function have markedly reduced corneal sensation and trophic changes in the cornea. One of these patients also has a tendency to trophic changes in the skin of the face and nasal vestibule. The coexistence of a severe degree of facial paralysis and reduced corneal sensation presents one of the most serious and difficult complications of acoustic neuroma surgery.

*Hearing preservation*

Hearing preservation was attempted in five patients with intrameatal tumours. In three there was immediate post-operative loss of hearing. In two cases there was immediate preservation of hearing so that the patients were able to converse on the telephone using the operated ear. In one of these, however, the hearing was suddenly lost on about the tenth post-operative day, and the other was one of the perioperative deaths (see case 5 above). In a sixth patient with a large second side tumour and good hearing, a portion of the tumour capsule was left in the hope of retaining useful hearing. Some perception of low frequency sound did remain but speech discrimination was lost.

*Problems related to operative positioning*

Two patients operated upon in the parkbench position developed temporary lateral popliteal nerve damage with weakness of dorsiflexion of the foot, and one patient sustained transient neuropraxia of the ulnar nerve which also recovered fully. One patient suffered a small area of scarring on the forehead related to the three pin headrest. The translabyrinthine approach was associated with a small area of pressure necrosis on the contralateral side of the scalp in a few patients. This was related to the use of the rather firm neurosurgical horse-shoe headrest, and has not been seen since the introduction of a softer foam support.

*Miscellaneous*

There were two instances of delayed healing of the leg incision during the first year of the series when muscle

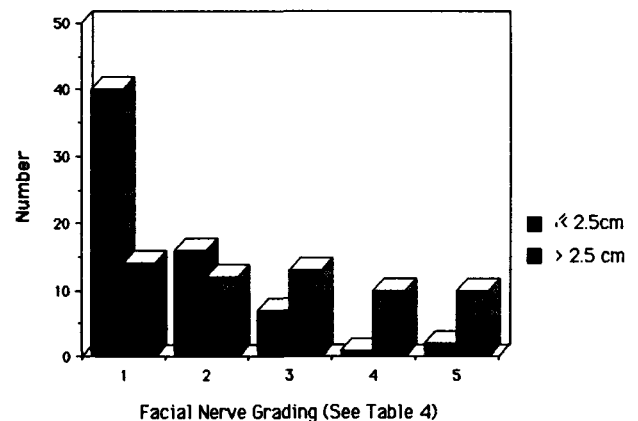


FIG. 7 Facial nerve grading as function of tumour size. (FU > 1 year).

from the vastus lateralis was used to obliterate the trans-labyrinthine defect. Another patient developed a haematoma in the abdominal fat donor wound but required no treatment. One patient temporarily developed the syndrome of inappropriate ADH secretion, and another had his latent diabetes mellitus unmasked.

### *Dreams*

We have noted that several of the patients in this series have experienced vivid, frightening and recurrent illusions which appear to be hypnagogic hallucinations, both before and more frequently for a period of several days following surgery. These often took the form of brightly coloured and changing abstract shapes which strangely might convey to the patient a tactile sensation of texture, or of threatening anthropomorphic forms. Unlike normal dreams they were usually readily recalled even weeks after they had ceased to occur. The frequency of these experiences was studied by comparing a small group of thirty-two acoustic neuroma patients, most of whom had had a suboccipital operation with eleven patients undergoing posterior fossa exploration for other reasons (nearly all for removal of other tumours). There was no obvious difference between the groups with respect to age, sex distribution, duration of surgery or anaesthetic agents used. Seventeen of the acoustic neuroma group (53 per cent) experienced hallucinations compared with two patients in the non-acoustic group (18 per cent). The possible mechanism of this phenomenon is explored later.

## **Discussion**

### **Population characteristics**

#### *Age and sex distribution*

In this series of 151 patients there is a female:male ratio of approximately 1.5:1, which corresponds with many other published series. The age distribution by decades indicates that the greatest incidence is between the age of 40 and 60. If however the decade distributions are analysed by sex it will be seen that there are differences and that whereas only 11 per cent of males present under the age of 40, the figure is 33 per cent for females (Figs. 1 & 2). These figures, together, with the observation that tumour growth in females seems to be influenced by pregnancy and puberty (Wiet *et al.*, 1989) raise the possibility that acoustic schwannomas may be hormone dependent. Siglock *et al.* (1990) found a higher incidence of oestrogen receptors in tumours removed from women than from men. A further study (Curley *et al.*, 1990) did not reveal a significant incidence of hormone receptors in such tumour specimens.

#### *Tumour size*

Accurate estimation of tumour size is a remarkably difficult exercise and there often seems to be a difference of opinion between the neuroradiologist, measuring from a CT image and the surgeon at the time of the operation. For that reason any attempt to define tumour size more accurately than we have seems fruitless. 2.5 cm was suggested by King and Morrison (1980) as a cut off between medium and large tumours, and has some prac-

tical value in that a tumour of that diameter is beginning to involve the trigeminal nerve and to make contact with the brain stem (May, 1986). To date all tumours larger than 4 cm diameter have been removed by the suboccipital route. It will be seen (Fig. 4) that although just over half the tumours are 2.5 cm or less, the number of wholly intracanalicular lesions is still small and is considerably exceeded by the very large tumours (>4 cm). Little can be done to overcome the delay between the onset of symptoms and the patients' seeking professional advice, but even when they do it is still too often a case of delayed referral to hospital and sadly missed diagnosis by otolaryngologists. Thomsen and Tos (1990) highlight the magnitude of the problem of diagnostic delay, and quote a mean delay of seven years in 233 out of a series of 300 patients. The reason why this should be so is discussed elsewhere but owes much to undue dependence on traditional but insufficiently reliable audiometric techniques (Ramsden *et al.* in preparation). It is to be hoped that as MR imaging becomes more widely available and surgeons are prepared to refer patients at an early stage for this investigation, the ideal of prompt diagnosis may be attainable (Stack *et al.*, 1988). The economic as well as human sense of such a policy has been highlighted recently by Moffat *et al.* (1989b).

#### *Tumour removal*

'Total' tumour removal was achieved in 142 instances, but as pointed out above this figure includes 21 cases in which a tiny fragment of tumour capsule was left on the brain stem, because manipulation and attempted removal brought about dramatic alterations in pulse or blood pressure. These vestiges were never larger than 1–5 mm and were vigorously diathermized. These patients have been regularly followed up for up to 12 years, and no clinical or convincing CT evidence of recurrence has been detected. The single tumour recurrence in the series as a whole was not one of the cases in which a fragment was knowingly left behind. A recent MR:Gd DTPA study by Pace-Balzan *et al.* (in preparation), however, indicates that although approximately 50% of such remnants do disappear, some do persist and may be capable of slow regrowth. Despite the paucity of references to this problem in the literature, we cannot believe that we are the only workers to have encountered it. Our experience suggests that these cases can usually be regarded as having had total tumour removal, but regular follow-up with MR:Gd DTPA is advisable.

Total removal is the usual aim but there have been occasions in which subtotal excision has seemed the safer alternative. Such instances have almost always involved elderly or medically unfit patients in whom there was a pressing neurosurgical indication for surgery. Such patients had trans-labyrinthine subtotal excisions, in the interests of speed, with tumour residue left on both the facial nerve and on the brain stem. The behaviour of the tumour remnant has been monitored by annual CT scan and as yet no significant enlargement of the residual portions have been observed.

As in most series, there are a number of elderly patients with small (<1 cm) tumours from whom surgery

has been withheld. In only one of the nine has the tumour grown significantly (doubled in size in two years), and that patient is now scheduled for surgery. Three young patients with small tumours in only hearing ears are also under annual review.

The factors which influence growth in acoustic tumours are poorly understood. Wiet *et al.* (1989) could identify no factor, clinical (including age), audiological or histological that predicts tumour growth. Valvassori and Guzman (1989) in a radiological follow-up study of 35 patients aged 16-81 who for a variety of reasons did not have their acoustic tumours removed, were unable to establish a correlation between rate of tumour growth and either age or clinical findings. They were able to conclude that the growth rate though unpredictable was usually minimal to moderate, and felt that if the patient is over 50 and the tumour small (1 cm or less) surgery should not be performed but the patient should be scanned by MRI every two years. The present authors feel that 65 is a more realistic age for such a "wait and scan" policy. The rate of growth of tumour fragments left behind at primary surgery may well be different from that of the original tumour (Pace-Balzan *et al.*, in preparation). Beatty *et al.* (1987) point out that unless one adopts a policy of routine CT scanning in all patients for up to seven years after primary surgery, recurrences may be missed, and in the absence of a functioning eighth nerve, clinical clues to recurrence will remain absent until the tumour makes contact with the brain stem.

#### Mortality and morbidity

The findings of this study confirm those of other authors that the death and complication rate following acoustic neuroma surgery is higher with large tumours (>2.5 cm) than small, the only exception being CSF fistula which is related to surgical approach. Of the five perioperative deaths and two major brain stem syndromes in this series, all but one (case 5 above) were associated with tumours of 3 cm or greater. It is also significant that of these seven cases, six were seen during the first 100 and only one subsequently. It is certain that increasing experience leads to better results, and this strengthens the argument that acoustic neuroma surgery is best performed in centres specializing in such work, by an otologist and a neurosurgeon working as a team. This has certainly been the philosophy in this series. As regards the choice of surgical approach we have tended not to be rigidly committed to one route, but have developed a flexibility which has allowed us to acquire equal familiarity both with the translabyrinthine and the suboccipital operations. Obviously as experience is gained with the translabyrinthine route so the surgeons, and in particular the neurosurgeons for whom it is a less familiar approach, become happier with the size of tumour that they feel they can remove through it. It is to be hoped that the experience gained in the removal of large tumours through the suboccipital route will pay dividends with small lesions in which hearing preservation is attempted. The advantages and disadvantages of both techniques are objectively reviewed by King (1988), and we subscribe strongly to the view expressed by him that the ideal is to have both methods available, and to tailor the approach to the demands of the individual case. The

middle fossa approach has not been employed because we feel it does not provide sufficient flexibility of access in the event of the unpredictable being encountered, for example a tumour larger than anticipated, or bleeding in the posterior cranial fossa. Furthermore the facial nerve is more likely to be damaged because it is situated between the surgeon and the tumour.

Functional preservation of the facial nerve is now one of the surgeon's main objectives when removing an acoustic tumour, and we suggest that reports which refer only to anatomical preservation of the nerve are worthless. Microsurgical technique, confident identification of the facial nerve in the internal meatus and at the brain stem, and adherence to the correct surgical plane between tumour and arachnoid all contribute, but the most important factor in preservation of the facial nerve is the single minded desire to do so, and to take as long over doing so as is necessary. In this respect the anaesthetic techniques which free the surgeon from the tyranny of the clock must be acknowledged. As yet we have been reluctant to place too much reliance on per-operative monitoring of facial nerve function, and support the view expressed by Luetje (1989) that the surgeon should rely more on skill, experience and clinical judgement than "bells, beeps and whistles" to keep him out of trouble. The grading system which we have used has one fewer category than that of House and Brackmann. The problems with any system is that it seeks to impose a finite number of groups on a continuum from total paralysis to normality. Nevertheless it does allow one to make comparisons and it is quite clear that tumours of 2.5 cm and smaller carry a very much better prognosis than those greater than 2.5 cm (Fig. 7). Apart from tumour size, the other important factor in post-operative facial nerve function is the presence or absence of weakness on presentation. Although no patient in this series had a major degree of pre-operative weakness there were nevertheless a number with minor degrees of facial asymmetry, usually of blink. Those tended to have a less favourable outcome (Lye *et al.*, 1982). The assignment of a grade to a facial nerve is not however immutable. In an admittedly small study of a group of our patients Vafadis *et al.* (1987) found that a number of patients with grade 1 face at one year, subsequently slipped back into grade 2 at between two and five years, usually by developing slight synkinesis or a minor degree of dryness of the eye. Our small numbers of patients who underwent facial nerve grafting procedures suggest that in every case a better functional result may be expected from a primary facial nerve graft (cable, rerouting with end to end anastomosis or direct reimplantation into the brain stem) than from facio-hypoglossal or facio-accessory anastomosis (grade 3 as against grade 4).

One of the main criticisms of the translabyrinthine operation has been the high incidence of CSF fistula, and it is certainly true that the technique of closure is of great importance if problems are to be minimized. The middle ear is packed with small pieces of muscle in order to occlude the opening of the Eustachian tube. To do this adequately the incus is removed, but in doing so great care must be taken not to displace the stapes from the oval window. In the most recalcitrant of the fistulae in this series, the source of the leak was eventually identified as the oval window after two re-explorations. In the

early cases the cavity in the temporal bone was filled with a free muscle graft, but in the last six years strips of abdominal fat have been used. A flap of periosteum from the mastoid process, based superiorly on the temporalis muscle, is sutured back over the fat graft. We feel that a firm pressure dressing, maintained in position for four days is of the greatest importance. CSF leakage after a posterior fossa exploration results from entry of fluid into the mastoid through air cells that have been opened at the time of surgery. These are closed with bone wax and muscle. If a leak persists, it may be sealed by re-exploring the posterior fossa and identifying and sealing the fistula, or by performing a mastoidectomy and inserting a fat graft in the manner outlined above. Robson *et al.* (1989) have suggested a technique using a pedicled sternomastoid flap but we have not employed it as yet. There have been no donor site problems since the introduction of abdominal fat, but there were two cases of infection of the thigh wound in the early part of the series when muscle was used.

### Hearing preservation

Our enthusiasm for hearing preservation has been tempered by the realization that there were very few patients in the series in whom the hearing on presentation was good enough to justify the attempt. It is essential to differentiate between hearing which is preserved at its pre-operative level, a result which may satisfy the surgeon, and hearing which is preserved at a level which satisfies the patient. In his analysis of the differences between the patients' and surgeons' view of "successful" tympanoplastic surgery, Gatehouse (1990) states that it is necessary to bring the hearing level in the operated ear to within at worst 40 dB and preferably to within 20 dB of the good side for the patient to appreciate the improvement. With these predominantly conductive hearing losses the deafness is purely a result of attenuation. If the same criteria are applied to acoustic schwannoma patients in whom there is often the additional consideration of impaired speech discrimination, it will be realized that there are in fact a very small number in whom useful hearing can be preserved. Nevertheless, we have encountered a few patients in whom we have attempted hearing preservation, but as yet we have failed to achieve a result that satisfied the patient. The patients for whom hearing preservation would of course be of crucial importance, are those with bilateral tumours and useful pre-operative thresholds, and it is in the hope of being able to help those patients that surgeons should attempt to perfect the necessary techniques.

### Dreams

The realization that a number of our patients experienced bizarre disturbances of visual imagery in the first few days following surgery came slowly because it was not a complaint about which one would necessarily think of questioning the patient. Once it had been drawn to our attention that such phenomena were occurring, then direct questioning revealed it with remarkable frequency. Certain features seemed to recur regularly. The imagery was always vivid, almost luminous, and seemed

to convey a strong sense of texture. There were frequently strange anthropomorphic and geometric forms and surreal conversion of everyday objects. The effect on the patients was of disproportionate terror considering the innocuous subject matter. These episodes which lasted for no more than a minute or two, occurred at any time of the night or day, and in some subjects could be activated almost at will by closing the eyes. Indeed one subject, an artist, was able to reproduce the images on paper by doing so. All of these features suggest that the phenomena were similar to hypnagogic hallucinations, the "sensory errors of half sleep" (Parkes, 1985). They are described in normal subjects on sudden waking from REM sleep, and in between 20 per cent and 50 per cent of narcoleptics. Benzodiazepines may cause hypnagogic hallucinations at sleep onset but the patients in our series were not on these or indeed any psychotropic drugs. The phenomenon has also been described in sleep apnoea.

Experiments in cats have revealed the existence of phasic potentials in the pons which are conducted rapidly via the lateral geniculate body to the occipital cortex. These PGO waves (pons-geniculate body-occipital cortex) have been seen to coincide with the onset of REM sleep. They appear to originate at the level of the dorsal pontine tegmentum, and they seem to have certain features in common with the cortical K complex recordable in humans (Parkes, 1985). It would seem possible that the initiating factors in the genesis of these hallucinations might be minor degrees of vascular embarrassment in that very discrete part of the brain stem, supplied by branches of the anterior inferior cerebellar artery, or perhaps more plausibly by congestion in the local veins which drain into the vein of the lateral recess or the lateral medullary vein.

### Conclusion

The results of over a decade of close collaboration between otologist and neurosurgeon in the management of acoustic neuromas indicate that the factors that influence the successful outcome of surgery both in terms of mortality and of morbidity are tumour size and surgical experience. These observations are particularly germane in respect of facial nerve function. Tumours of 2.5 cm or less carry a very much better prognosis for facial function than larger lesions. Tumour size is a reflection of tumour diagnosis. It is still sadly true that almost half the tumours in this series measured more than 2.5 cm in diameter at diagnosis. MRI with gadolinium enhancement will allow the smallest of tumours to be diagnosed, and should be the investigation of choice of all patients suspected of harbouring an acoustic schwannoma. If the facial nerve is known to have been sacrificed, immediate grafting is to be preferred to facio-hypoglossal or facio-accessory anastomosis.

The incidence of other serious complications is low and these too are usually related to tumour size. The coexistence of a total facial palsy and trigeminal dysaesthesia is to be regarded as potentially grave, with important implications for the health of the eye. CSF fistula, whilst always to be taken seriously, has not presented any major problems in this series.

We have developed a surgical philosophy which has



allowed both members of the team to become familiar with both the translabyrinthine and suboccipital approaches, and feel that the results of the surgery have less to do with the approach than with the experience of the surgeons. Hearing preservation has remained an elusive goal, because of the small numbers who appear to justify the attempt. Nevertheless it does seem probable that early diagnosis will become a more readily attainable ideal in the next decade, and so the numbers of patients for whom hearing preservation will be attempted must increase. At the same time surgeons must not lose sight of the concept of "useful" hearing preservation.

Whilst total tumour removal has been our objective, there are occasions on which a subtotal removal may be one's deliberate choice, or may be forced upon one by circumstances. Such patients should be followed up with regular CT scanning or MRI. There is also a group of patients in whom a tiny fragment of capsule firmly adherent to the brain stem, may be diathermized and left *in situ*. Although in none of the 21 patients in this group has there been any convincing evidence of regrowth either clinically or on CT imaging, it may be that MR: Gd DTPA studies will indicate that some of these small fragments are capable of survival and indeed regrowth.

Finally, attention is drawn to the occurrence of hypnagogic hallucinations an unusual manifestation of transient post-operative brain stem dysfunction, not as far as we can establish previously described.

#### Acknowledgements

The authors have been supported in this work by the Brenda and Geoffrey Thornley Foundation (B and GT Foundation), and gratefully acknowledge its continuing help in the clinical, educational and research aspects of acoustic neuroma and related conditions.

The senior authors, JEMD and RTR were TWJ travelling fellows to North America in 1978, and recognize with gratitude the value of the foundation's contribution to the establishment of the otoneurological programme in Manchester.

#### References

- Beatty, C. W., Ebersold, M. J., Harmer, S. G. (1987) Residual and recurrent acoustic neuromas. *Laryngoscope*, **97**: 1168-1171.
- Bentivoglio, P., Cheesman, A. D., Symon, L. (1988) Surgical management of acoustic neuromas during the last five years. Part II: Results for facial and cochlear nerve function. *Surgical Neurology*, **29**: 205-209.
- Birzgalis, A., Ramsden, R. T. (1991) Intravestibular schwannoma *Journal of Laryngology and Otology* (in press).

#### Key words: Acoustic schwannoma

- Curley, J. W. A., Ramsden, R. T., Lye, R. H., Howell, A., Healey, K. (1990) Oestrogen and progesterone receptors in acoustic neuromas. *Journal of Laryngology and Otology*, **104**: 865-867.
- Gatehouse, S. (1990) Modelling of disability in unilateral hearing loss. *Audiology*. In press.
- House, J. W., Brackmann, D. E. (1985) Facial nerve grading system. *Otolaryngology—Head and Neck Surgery*, **93**: 146-147.
- King, T. T. (1988) Surgical approaches to acoustic tumours. *British Journal of Neurosurgery*, **2**: 433-438.
- King, T. T., Morrison, A. W. (1980) Translabyrinthine and trans-tentorial removal of acoustic tumours. Results in 150 cases. *Journal of Neurosurgery*, **52**: 210-216.
- Luetje, C. M. (1989) Intraoperative monitoring: hardware addiction is no substitute for clinical judgement. Editorial. *American Journal of Otology* **10**(5).
- Lye, R. H., Dutton, J., Ramsden, R. T., Occleshaw, J. V., Ferguson, I. T., Taylor, I. (1982) Facial nerve preservation during surgery for removal of acoustic nerve tumours. *Journal of Neurosurgery*, **57**: 739-746.
- May, M. (1986) In *The Facial Nerve* (May M., ed), Thieme Inc; New York. p 33.
- Moffat, D. A., Croxson, G. R., Baguley, D. M., Hardy, D. G. (1989a) Facial nerve recovery after acoustic neuroma tumour removal. *Journal of Laryngology and Otology*, **103**: 169-172.
- Moffat, D. A., Hardy, D. G., Baguley, D. (1989b) Strategy and benefits of acoustic neuroma searching. *Journal of Laryngology and Otology*, **103**: 51-59.
- Parkes, J. D. (1985) In *Sleep and its disorders*, W. B. Saunders & Co; London. p 23-24.
- Robson, A. K., Clarke, P., Dilkes, M., Maw, A. R. (1989) Trans-mastoid extracranial repair of CSF leaks following acoustic neuroma resection. *Journal of Laryngology and Otology*, **103**: 842-844.
- Siglock, T. J., Rosenblatt, S. S., Finck, F., House, W. F., Hitzelberger, W. E. (1990) Sex Hormone Receptors in Acoustic Neuromas. *American Journal of Otology*, **11**: 237-239.
- Stack, J. P., Ramsden, R. T., Antoun, N. M., Lye, R. H., Isherwood, I., Jenkins, J. P. R. (1988) Magnetic resonance imaging of acoustic neuromas: the role of gadolinium-DTPA. *British Journal of Radiology* **61**: 800-805.
- Thomsen, J., Tos M. (1990) Acoustic neuroma: clinical aspects, audiovestibular assessment, diagnostic delay and growth rate. *American Journal of Otology*, **11**: 12-19.
- Vafadis, J. A., Page, R. D., Keith, A., Lye, R. H., Dutton, J., Ramsden, R. T. (1987). Diagnosis and management of acoustic neuroma: a ten year experience. Scientific Exhibit. The Eighth European Association of Neurological Surgeons Congress. Barcelona. September 1987.
- Valvassori, G. E., Guzman, M. (1989) Growth rate of acoustic neuromas. *American Journal of Otology*, **10**: 174-176.
- Wiet, R. J., Young, N. M., Monsell, E. M., O'Connor, C. A., Kazan, R. (1989) Age considerations in acoustic neuroma surgery: the horns of a dilemma. *American Journal of Otology*, **10**: 177-180.

Address for correspondence:  
Mr Richard T. Ramsden F.R.C.S.,  
Department of Otolaryngology,  
Manchester Royal Infirmary,  
Oxford Road,  
Manchester M13 9WL.