

SHORT REPORT

Recovery from hemianopsia after surgical removal of spontaneous occipital haemorrhage

ANDREA TALACCHI, MARIO GANAU & MASSIMO GEROSA

Section of Neurosurgery, Department of Neurological Sciences and Vision, University of Verona, Italy

Abstract

In cases of spontaneous haemorrhage without severe impairment of consciousness, indications for surgical treatment remain controversial and the effect of surgery on focal deficits is unclear. We report the case of a young man operated for left occipital spontaneous haemorrhage (28 cm³) who had presented with right lateral hemianopsia without impaired consciousness. The visual field defect improved soon after the operation and resolved over the following months. The rationale for this approach is discussed.

Key words: Spontaneous haemorrhage, hemianopsia, surgical treatment.

Introduction

The management of intracerebral haemorrhage (ICH) in selected cases continues to arouse debate as do the criteria for approach (conservative or surgical), surgical technique (craniotomy, endoscopy or stereotaxis), treatment modality (early or at deterioration, decompression or near total clot removal) and outcome analysis: broad categories miss small clinical changes, while detailed scales fail

to describe functional performance. Accordingly, the aim of treatment will vary depending on the clinical situation, and results will be properly interpreted based on adequate outcome scales. Visual field defects are peculiar in that they can be objectively measured yet carry a poor prognosis.

In addition, research into the pathogenesis of the mechanisms underlying oedema and penumbra, and ultimately the progression of primary injury, has

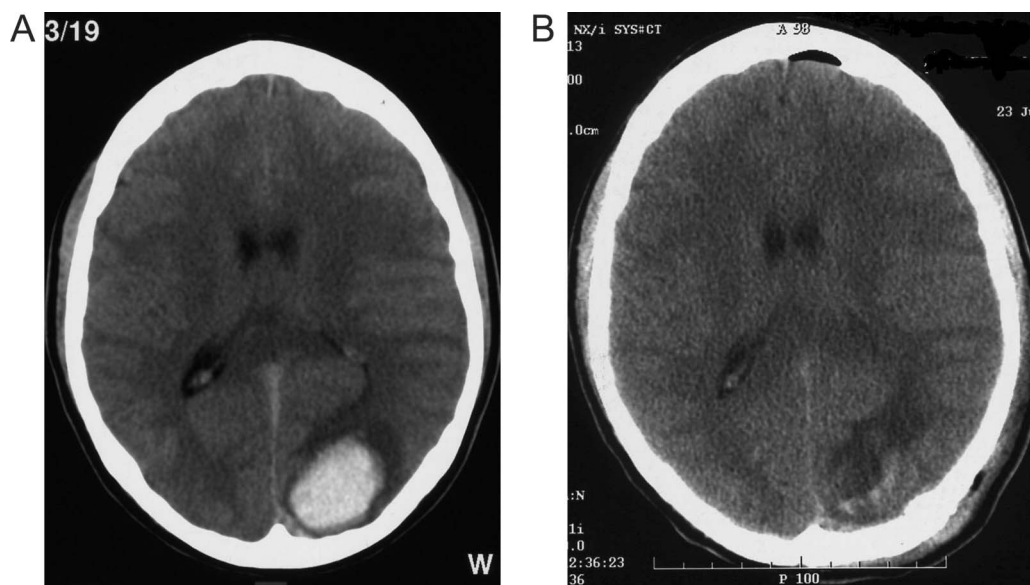


FIG. 1. Preoperative CT scan showing left occipital haemorrhage (28 cm³) (Panel A); Postoperative CT scan showing the operative cavity (Panel B).

Correspondence: Andrea Talacchi M.D., Section of Neurosurgery, Department of Neurological Sciences and Vision, P. Stefani 1, 37126 Verona, Italy. Tel. +39-45 - 8122695/3485, Fax +39 - 45 - 916790. E-mail: andrea.talacchi@univr.it

Received for publication 3 July 2009. Accepted 24 November 2009.

ISSN 0268-8697 print/ISSN 1360-046X online © The Neurosurgical Foundation
DOI: 10.3109/02688690903513404

helped to optimize treatment and encourage new trials. Early improvement of primary injury of a visual field defect after surgical clot removal has not been reported so far.

Case presentation

A 21-year-old right-handed man was admitted to the Department of Neurosurgery, University of Verona, because of a persistent headache that had suddenly arisen two days earlier. On admission, he was alert (GCS = 14); right lateral hemianopsia was observed. Computed tomography (CT) scans revealed an occipital haemorrhage (28 cm³) surrounded by a thin oedematous ring (Fig. 1). Angiography demonstrated no vascular malformations. Right lateral hemianopsia was confirmed on computerized exam-

ination (Fig. 2). Blood chemistry was normal (PT, PTT, fibrinogen, antithrombin III, von Willebrandt's factor, factor VII, factor IX, transferrin, platelet aggregation). The patient referred not having taken any drugs.

Given the superficial location of the haemorrhage, the low risk of additional surgical deficits, and the patient's stated wish to be treated for fear of permanent visual deficit, he was operated the fourth day after onset in an attempt to resolve hemianopsia by clot removal. The cortex was intact, the gyri flattened by the mass. The approach was made through a small area measuring a few millimetres where the cortex was violated by the haematoma, which was carefully aspirated so as not to damage the adjacent brain tissue. Histological examination of the clots was negative for vascular malformations. Five

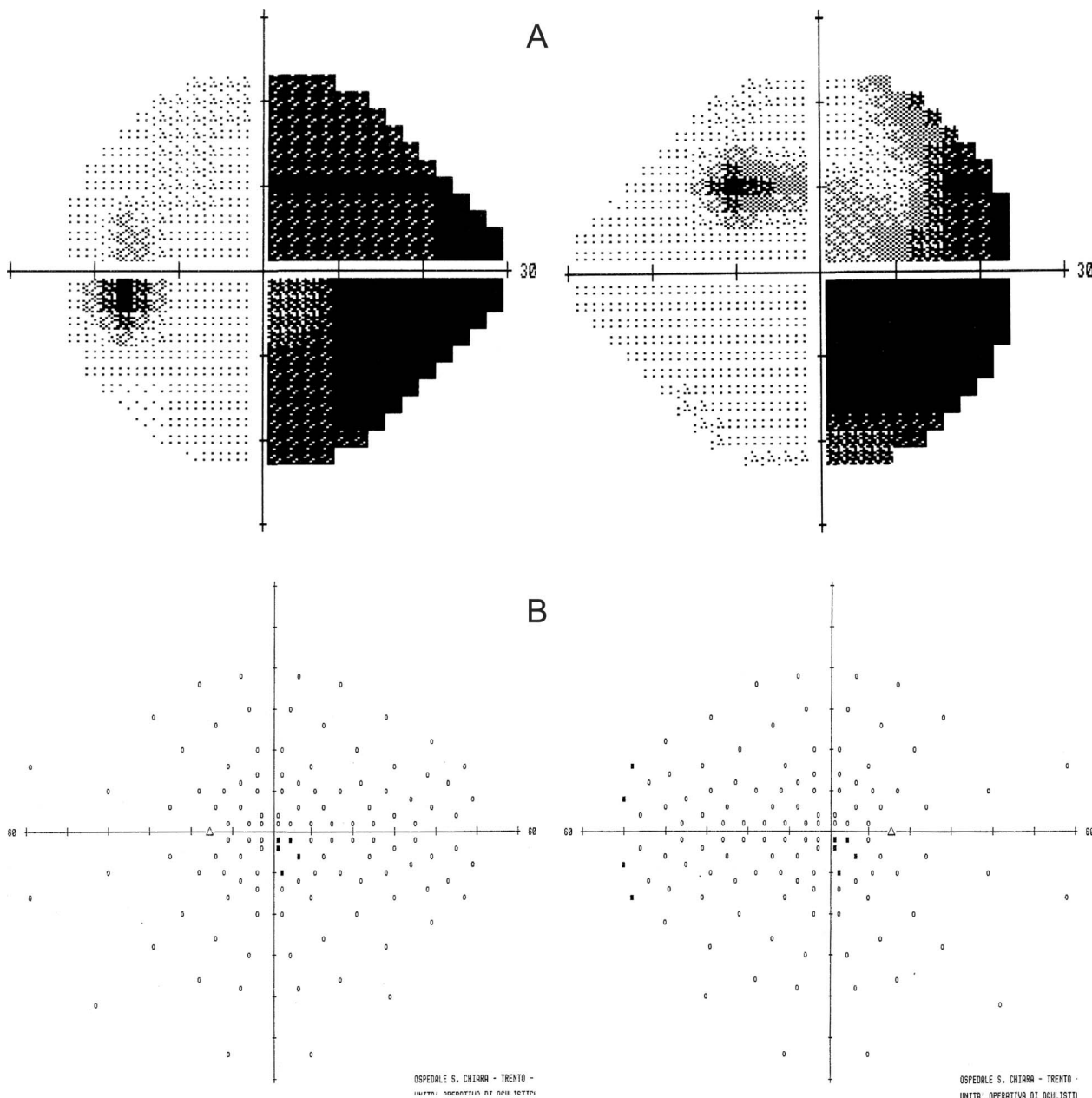


FIG. 2. Computerized visual field analysis showing right lateral hemianopsia (Panel A1 left, Panel A2 right); Normal computerized visual field analysis 1 month postoperative (Panel B1 left; B2 right).

days later, the patient was discharged after a CT scan and a computer-based campimetric examination showed only inferolateral quadrantopsia (Fig. 1). Repeat visual field testing 1 month later showed complete recovery, and this finding remained stable over time (Fig. 2). Six months later, convalescent magnetic resonance imaging (MRI) revealed no underlying lesion.

Discussion

Early and accurate surgery to decrease intracranial pressure and related complications can be considered as a life-saving procedure. Less certain are the surgical indications in non comatose patients. Pantazis et al.¹ compared early surgery with conservative treatment for spontaneous supratentorial ICH in comatose and non-comatose patients and found that while the number of poor outcomes was the same for both groups, more patients obtained good functional outcome after early surgery.

Little is known about the effect of surgery on focal deficits in patients with higher GCS scores. In critical areas (e.g., motor area, Broca and Wernicke areas and the occipital calcarine area), even medium-sized haemorrhage (<30 cm³) can cause impairment. Partial or later impairment due to haemorrhage at sites adjacent to functional structures which are distorted but not destroyed is more likely to be reversed by clot removal. This has been observed for motor strength and for language in cases of deep brain haemorrhage, but may only be inferred for vision about which reports are lacking.²

Homonymous hemianopsia is a powerful negative predictor for patient outcome for two main reasons: infrequent recovery despite rehabilitation and adverse impact on activities of daily living.³ With conservative management, the initial impairment may remain stable or worsen due to increasing oedema, interstitial pressure, and reduced perfusion

pressure at the clot periphery where functional structures lie, resulting in a loss of residual function of vital structures, with the likelihood that the deficit will become permanent. Furthermore, since recovery from hemianopsia is more likely to occur during the first 3 post-stroke months, a direct or an indirect effect of haemorrhage may remain for at least 1 month, with the risk of permanent brain damage and reduced chances for recovery.³

In this case, we performed surgical evacuation by means of a fine surgical technique and a safe surgical access so as to lower the risk of permanent deficit and to increase the patient's chances of recovery. Our decision was based on the balance of risks between accurate surgery and the natural history of haemorrhage anticipated in this patient.

In conclusion, careful clinical and radiological evaluation can select for patients who may benefit from clot removal with appropriate surgical techniques, thus increasing their chance of early and complete focal recovery. Patients with hemianopsia and superficial haemorrhage may be eligible for this surgical treatment.

Declaration of interest: The authors report no conflicts of interest. The authors alone are responsible for the content and writing of the paper.

References

- 1 Pantazis G, Tsitsopoulos P, Mihas C, Katsiva V, Stavrianos V, Zymaris S. Early surgical treatment vs. conservative management for spontaneous supratentorial intracerebral hematomas: a prospective randomized study. *Surg Neurol* 2006;66:492–502.
- 2 Vespa P, McArthur D, Miller C, O'Phelan K, Frazee J, Kidwell C, et al. Frameless stereotactic aspiration and thrombolysis of deep intracerebral hemorrhage in association with reduction of hemorrhage volume and neurological improvement. *Neurocritical Care* 2005;2:274–81.
- 3 Schofield TM, Leff AP: Rehabilitation of hemianopia. *Curr Opin Neurol* 2009;22:36–40.