

# Thrombocytopenia as an Adverse Effect of Levetiracetam Therapy in a Child

## Authors

B. Peer Mohamed, P. Prabhakar

## Affiliation

Department of Paediatric Neurology, Great Ormond Street Hospital, London, UK

## Key words

- levetiracetam
- thrombocytopenia
- adverse effect
- epilepsy
- children

## Abstract

Levetiracetam is one of the newer anti-epileptic medications, which is now widely used in the treatment of childhood epilepsy. Thrombocytopenia is not a well-known adverse effect of this medication. There have only been two adult case reports describing this feature as an adverse effect of levetiracetam. We describe this feature in a child. A six and half-year-old boy developed symptomatic epilepsy secondary to cerebral

venous sinus thrombosis. He was treated with levetiracetam. He made a good recovery from his primary illness, but five weeks after he started taking levetiracetam, he presented with thrombocytopenia requiring platelet transfusion. Extensive investigations for known causes of thrombocytopenia were negative. Withdrawal of levetiracetam led to the resolution of thrombocytopenia. Levetiracetam-induced thrombocytopenia is a rare, but significant adverse effect.

## Case Report

A previously healthy six and half year-old-boy was admitted with cerebral venous sinus thrombosis in Kuwait and subsequently transferred to the UK for ongoing medical care. He had headache and vomiting for two days followed by generalised seizures. Neuroimaging demonstrated thrombosis of the left transverse and sigmoid sinuses with haemorrhagic infarction of the left temporoparietal region. In addition, on the magnetic resonance imaging scan there was evidence of mastoiditis on the left side, which was treated with intravenous antibiotics. The seizures were successfully treated with a loading dose of intravenous phenytoin and subsequently given maintenance dose of phenytoin. Oral levetiracetam was started at a dose of 500 mg twice a day as long-term maintenance anti-convulsant therapy after 72 hours. Anti-coagulation therapy with heparin was started 3 weeks after initial presentation on arrival in the UK, on the basis of extending venous sinus thrombus on review of neuro-imaging. Heparin was subsequently replaced with warfarin 2 days later. Phenytoin was weaned and withdrawn. Screening for pro-thrombotic states was negative and therefore, the probable cause for the sinus thrombosis was mastoiditis augmented by dehydration from

vomiting. He made a good recovery and was discharged home. Five weeks after commencing treatment with levetiracetam, he presented with petechiae on his skin and mucosa. Laboratory investigations revealed thrombocytopenia ( $99 \times 10^9/L$ ) with otherwise normal full blood count. Investigations to elucidate the cause for the thrombocytopenia included negative virology studies for Herpes, cytomegalovirus, Epstein-Barr virus and enteroviruses. Bone marrow aspiration demonstrated normocellular marrow with increased megakaryocytes indicating peripheral destruction of platelets. No abnormal auto-immune antibodies were detected. During the course of this illness, the lowest platelet count was  $12 \times 10^9/L$  and this was associated with mucosal haemorrhage for which the patient was given a platelet transfusion.

In the absence of other known causes, drug-induced thrombocytopenia was considered. Thrombocytopenia is not a known adverse effect of warfarin and therefore levetiracetam was withdrawn as a trial. A few days later, there was progressive improvement in the platelet count which normalised four weeks after cessation of treatment with levetiracetam (○ Fig. 1).

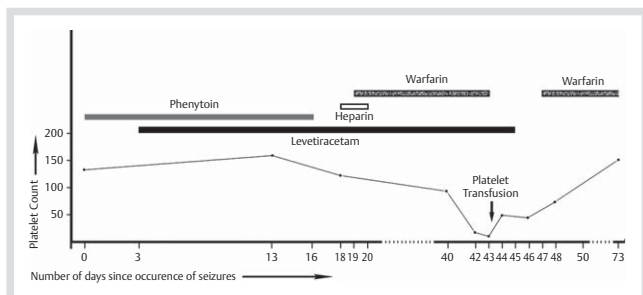
received 26.08.2009  
accepted 05.01.2009

## Bibliography

DOI <http://dx.doi.org/10.1055/s-0030-1247524>  
Neuropediatrics 2009;  
40: 243–244  
© Georg Thieme Verlag KG  
Stuttgart · New York  
ISSN 0174-304X

## Correspondence

**Prab Prabhakar**  
Department of Paediatric  
Neurology  
Great Ormond Street Hospital  
Great Ormond Street  
London WC1N 3JH  
United Kingdom  
Tel.: +44/2078138308  
Fax: +44/2078138279  
prabhp@gosh.nhs.uk



**Fig. 1** Graph showing the relationship between platelet count and levetiracetam therapy.

## Discussion

Levetiracetam is a novel anti-epileptic drug with well-established efficacy and tolerability. It is now widely used in childhood epilepsy either as monotherapy or as adjunctive therapy. In an open-label study in adults, the commonest adverse effects found were fatigue, somnolence, headache, dizziness, nausea and lethargy while in paediatric trials, behavioural/psychiatric adverse effects were seen much more commonly [1,2]. To the best of our knowledge, there have been no reports on the incidence of thrombocytopenia with levetiracetam use in any major trials. However, there have been a few case reports in the literature in the last few years, which strongly suggest this possibility. Kimland et al. reported thrombocytopenia occurring after 20 days of treatment with levetiracetam in a 49-year-old with oligoastrocytoma [4]. The patient had been receiving treatment with multiple anti-epileptic drugs for a long period and the last cycle of chemotherapy for the tumour was administered 5 months earlier. The other new medication that was started just prior to the onset of thrombocytopenia was sertraline. It was therefore deduced that the thrombocytopenia was the result of treatment with either levetiracetam or sertraline. On analysis of a blood sample from the patient, irregular anti-platelet antibodies were observed only in the presence of levetiracetam and not of sertraline, thus raising the possibility of levetiracetam-induced immune-mediated thrombocytopenia. The platelet count increased to  $94 \times 10^9/L$ , five weeks after discontinuation of levetiracetam. Meschede et al. [5] described the occurrence of thrombocytopenia, 3 days after starting levetiracetam in a 64-year-old patient with symptomatic epilepsy. Discontinuation of sodium valproate which was started 3 weeks before the onset of thrombocytopenia did not have any impact on the platelet count. However, the platelet count returned to normal level within 2 days of discontinuation of levetiracetam. In our case, however, the temporal relationship between the onset of thrombocytopenia and levetiracetam therapy was much more evident, since the patient was receiving no other medication with the potential to cause thrombocytopenia immediately prior to the onset of thrombocytopenia.

## Notice

This article was changed according to the following erratum on: 10.09.2010

## Erratum

Some of the authors' names of this article were incorrect. The names of the authors should be as follows:  
B. Peer Mohamed, P. Prabhakar

These reports demonstrate the association between levetiracetam and thrombocytopenia. Although it is difficult to hypothesise the potential underlying mechanism based on the case reports cited above, immune-mediated peripheral destruction seems to be most likely. Drug-induced thrombocytopenia is a well known phenomenon which occurs either due to bone marrow suppression as seen with cytotoxic agents or due to immune-mediated peripheral destruction [3]. Most commonly, immune-mediated destruction is initiated by the modification of platelet membrane glycoprotein by the offending drug. This may lead to the formation of a neoepitope or a non-covalently bound drug-glycoprotein complex that is recognised by antibodies. It often takes a few weeks for primary alloimmunisation to take effect, while occasionally thrombocytopenia may result within 24 h following sensitisation of pre-existing antibodies. Heparin-induced thrombocytopenia is unique in that the drug forms an immune complex with platelet factor 4 which, in turn, binds to the platelets, leading to platelet activation and thrombosis. Very rarely, drugs such as gold salts and procainamide can induce the formation of anti-platelet antibodies that react with platelets even in the absence of the drug. Recovery of the platelet count usually takes place within a few weeks of discontinuation of the offending drug.

## Conclusion

Thrombocytopenia is not a well-known adverse effect of levetiracetam. However, recent case reports on adult patients have highlighted this possibility and, in this case report, we have shown that thrombocytopenia can occur in association with the use of levetiracetam in children. Discontinuation of levetiracetam seems to lead to recovery of platelet count within a few days to a few weeks. More research will be needed to understand the mechanism underlying this adverse effect. It is important that clinicians are aware of this possibility. We recommend that carers be warned of this potential adverse effect in addition to the other well known adverse effects and they are advised to seek medical attention should the child develop a non-blanching rash, especially within a few weeks of starting treatment.

## References

- 1 Abou-Khalil B. Levetiracetam in the treatment of epilepsy. *Neuropsychiatr Dis Treat* 2008; 4: 507–523
- 2 Beran RG, Berkovic SF, Black AB et al. Efficacy and safety of levetiracetam 1000–3000 mg/day in patients with refractory partial-onset seizures: a multicenter, open-label single-arm study. *Epilepsy Res* 2005; 63: 1–9
- 3 Kenney B, Stack G. Drug-induced thrombocytopenia. *Arch Pathol Lab Med* 2009; 133: 309–314
- 4 Kimland E, Höjberg B, von Euler M. Levetiracetam-induced thrombocytopenia. *Epilepsia* 2004; 45: 877–878
- 5 Meschede A, Runge U, Sabolek M. Thrombocytopenia during levetiracetam therapy. *Epilepsy Res* 2008; 80: 91–92