

Hyper-acute Stroke Patients Associated with Aortic Dissection

Yasuyuki Iguchi, Kazumi Kimura, Kenichiro Sakai, Noriko Matsumoto, Junya Aoki, Shinji Yamashita and Kensaku Shibazaki

Abstract

Backgrounds and propose Intravenous thrombolysis using tissue plasminogen activator (tPA) can improve patient outcomes in acute stroke if administered within 3 hours of onset. However, patients with aortic dissection should avoid tPA therapy due to the possibility of tPA administration inducing rupture of the aortic dissection. We studied the frequency and clinical characteristics of stroke patients presenting with aortic dissection within 3 hours of onset.

Methods Among stroke patients admitted to our hospital within 3 hours of onset, we examined the frequency of patients presenting with aortic dissection. Next, we examined the clinical characteristics of such patients, including cases published on PubMed.

Results Among 208 stroke patients presenting within 3 hours of onset, 2 patients (1%) displayed aortic dissection. Carotid duplex ultrasonography could exclude them from tPA therapy. For 19 patients, including 17 published cases from PubMed, median age was 61.0 years, 47% were women, right pulse weakness was seen in 70%, chest pain in 22%, and lone left hemiparesis in 72%. In 6 patients, carotid ultrasonography showed arterial dissection due to aortic dissection.

Conclusion Aortic dissection may not be a rare complication in acute stroke within 3 hours of onset. Right pulse weakness and left hemiparesis are often present. Carotid ultrasonography may be useful in diagnosing aortic dissection before tPA infusion.

Key words: acute stroke, aortic dissection, carotid duplex ultrasonography, tPA

(*Inter Med* 49: 543-547, 2010)

(DOI: 10.2169/internalmedicine.49.3026)

Introduction

Recombinant tissue plasminogen activator (tPA) for the treatment of acute ischemic stroke within 3 hours of onset requires precise inclusion and exclusion criteria. In particular, patients with a high risk of hemorrhagic complications should be excluded as candidates for intravenous thrombolysis using tPA (IV-tPA). This is because hemorrhagic complications such as intracerebral hemorrhage and gastrointestinal bleeding can induce poor outcomes and high mortality rates.

Stanford type A dissection causes ischemic stroke in up to 5-10% of patients by extension of the dissection into the common carotid arteries, thromboembolism or cerebral hypoperfusion (1). Although both aortic dissection and acute

ischemic stroke are medical emergencies, we occasionally experience difficulty in diagnosing aortic dissection for patients with acute stroke displaying atypical symptoms and signs, particularly in those without pain (2). After stroke physicians have identified aortic dissection as a major contraindication against IV-tPA in the emergency room, urgent repair of the thoracic aorta should be performed. Indeed, IV-tPA should be avoided for stroke patients in the setting of aortic dissection, given the high risk of aortic rupture. However, especially in the clinical setting, the importance of rapid and accurate diagnosis for aortic dissection prior to IV-tPA has still been underestimated and overlooked. The aim of this study was thus to estimate the frequency of acute ischemic stroke associated with aortic dissection within 3 hours of onset in our institute, and to investigate

the clinical characteristics of acute stroke with aortic dissection based on published articles in the literature.

Methods

Consecutive patients presenting with acute ischemic stroke within 3 hours of stroke onset between October 2005 and August 2008 were studied. Inclusion and exclusion criteria for IV-tPA were applied in accordance with the Japan Alteplase Clinical Trial (3). Magnetic resonance imaging and magnetic resonance angiography were performed in stroke patients to diagnose cerebral ischemia. Carotid duplex ultrasonography was performed immediately after hospital arrival to detect the presence of carotid arterial lesions. Stroke neurologists determined the National Institutes of Health Stroke Scale (NIHSS) score on admission.

Concerning a diagnosis of aortic dissection, when stroke neurologists found 1) hypotension, 2) asymmetrical peripheral pulses in upper and lower extremities, 3) complaint about chest or back pain, 4) mediastinal widening in chest roentgenography, and/or 5) intramural hematoma, intimal flap, false lumen, and/or intra-arterial floating sign on carotid duplex ultrasonography, indicating the presence of carotid arterial dissection, chest CT was performed immediately before IV-tPA.

In addition, all available published case reports on aortic dissection in acute ischemic stroke patients presenting within 3 hours of onset and appearing eligible for IV-tPA were identified in the PubMed database using the search terms "aortic dissection", "dissecting aneurysm", "ischemic stroke" and "cerebral infarction". We then investigated the clinical characteristics of previously published cases and those cases identified in our series. To be included in this review, the following findings had to be reported: 1) duration from onset to admission, 2) neurological symptoms at presentation, 3) clinical findings suspecting aortic dissection (back pain, pulse laterality, and hypotension), 4) chest roentgenography and carotid ultrasonography, 5) administration of IV-tPA and surgery, and 6) in-hospital mortality. This study was conducted in accordance with the Declaration of Helsinki.

Results

In our institute, 208 consecutive ischemic stroke patients presenting within 3 hours of onset (median age, 73.0 years; 125 men, 83 women) were enrolled. The interval from onset to hospital was 1.6 hours (range, 1.1-2.2 hours) and median NIHSS score was 9. Aortic dissection was found in 2 (1%, 95% confident interval; 0.1-3%) of the 208 cases. IV-tPA was administered for 87 patients (41%).

Case 1

A 72-year-old woman with a history of hypertension felt disability of the left arm. She was admitted to our emergency room 0.8 hours after onset. Although consciousness was slightly disturbed, she did not complain of any chest

discomfort or pain. On examination, blood pressure was 83/34 mmHg. Heart sounds were regular without murmurs and peripheral arterial pulsations were asymmetrical. Left hemineglect was identified, and her eyes deviated to the right. Left hemiparesis was seen, with NIHSS score of 18 on admission. Diffusion-weighted magnetic resonance imaging showed a moderate hyper-intense lesion in the right hemisphere. Chest roentgenography showed no pulmonary edema or mediastinal widening suggestive of aortic dissection. Carotid ultrasonography revealed an intimal flap in the right common carotid artery (Fig. 1A). Urgent chest CT showed type A thoracic aortic dissection (Fig. 1B). As a result, we completely excluded this patient as a candidate for IV-tPA. Emergent surgical repair of the dissection was performed, but she died on hospital day 8.

Case 2

A 72-year-old woman with a history of hypertension was seen due to the inability to move her left side. She was admitted to our hospital 1.9 hours after onset. In the emergency room, she did not complain of chest pain. Blood pressure was 150/64 mmHg. Left hemiparesis was identified on admission, with an NIHSS score of 8. Diffusion-weighted magnetic resonance imaging showed a moderate hyper-intense lesion on the right hemisphere. Chest roentgenography showed no pulmonary edema or mediastinal widening. Verbal communication was lost with loss of consciousness during transportation from the emergency room to the stroke care unit. Peripheral arterial pulsations were asymmetrical and hypotension status was sustained. Carotid ultrasonography revealed the presence of right carotid arterial dissection with an intimal flap (Fig. 1C). Urgent chest CT showed type A thoracic aortic dissection (Fig. 1D). The patient was thus excluded as a candidate for IV-tPA. Although cardiopulmonary resuscitation was performed, she was unable to recover from cardiac arrest due to shock status and died before going into surgery.

In a literature search using the PubMed database, regarding the review of acute stroke with aortic dissection, we identified another 17 cases (median age, 61.0 years; 7 women, 10 men). Table 1 shows the clinical features of acute stroke with aortic dissection including both the present and published cases (2, 4-15). Nineteen patients (10 men; median age, 61 years; age range 56 to 72 years) were admitted to hospital within 3 hours of onset (median duration, 0.5 hours; range, 0.45 to 0.8 hours). Of them, 15 (79%) patients showed loss of consciousness. Interestingly, pain was found in only 4 patients. Diminished pulsation in the right arm was documented as a distinctive physical finding in 7 of 10 patients (70%). Right hemiparesis alone was observed in only 3 of 19 patients (16%) and most (74%) showed left-side weakness. Concerning chest roentgenography, 5 of 12 patients (42%) exhibited enlargement of the mediastinal or cardiac silhouette. All 6 cases who underwent duplex ultrasonography showed positive findings for presence of carotid arterial dissection, such as intimal flap in cases 1, 2, 13, and

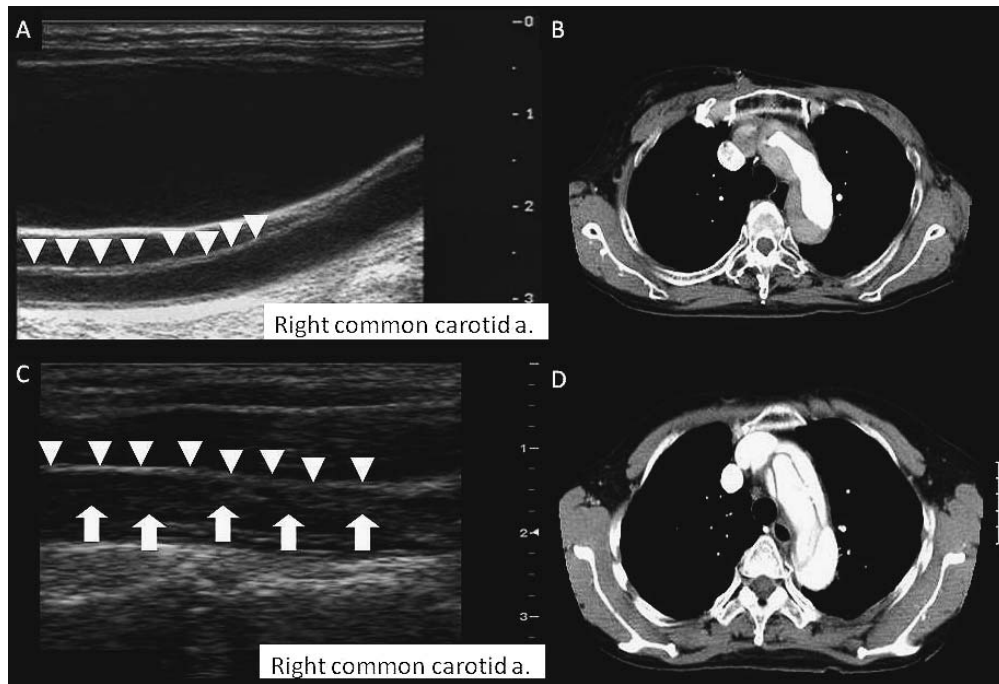


Figure 1. Case 1; (A) Carotid duplex ultrasonography of the transverse plane shows an intimal flap (white arrowhead) in the visible segment of the right common carotid artery. (B) Chest CT detected type A thoracic aortic dissection. Case 2; (C) Carotid duplex ultrasonography of the transverse plane shows an intimal flap (white arrowhead) and far wall of true lumen (white arrow) in the visible segment of the right common carotid artery. (D) Chest CT revealed type A thoracic aortic dissection.

19, diffuse luminal narrowing of left common carotid artery in case 3, and proximal right carotid arterial occlusion in case 10. Surgical retraction and replacement of aortic dissection were done in 11 (58%) patients. IV-tPA was administered in 3 (16%) patients (cases 6, 9, 10). Case 6 became comatose after IV-tPA. His neurological examination did not improve and he died 6 days after admission. In case 9, with an initial NIHSS score of 18, during IV-tPA he complained of severe back pain. Urgent chest CT showed the type A aortic dissection, and then emergency operation was performed. After the operation, he regained neurological improvement. One month of postoperatively, he was discharged. Case 10, with an initial NIHSS score of 16, received IV-tPA 150 minutes after onset. As the standard protocol of neurosonological examination, duplex ultrasonography showed the proximal common carotid arterial occlusion which was unusual finding of atherosclerosis and cardioembolism. Immediately after stopping IV-tPA, urgent CT revealed type A aortic dissection. Emergency operation was performed, but her stroke symptoms did not improve much 3 months after onset. Overall, the inhospital mortality of 19 cases was 33% of patients treated by IV-tPA and 63% without IV-tPA.

Discussion

In our series, 1% of hyper-acute ischemic stroke patients

suffered aortic dissection on admission. Considering the present cases together with the previous reports, 4 major findings for stroke with aortic dissection are apparent: 1) presentation without pain; 2) left hemiparesis; 3) negative findings on chest roentgenography; and 4) utility of carotid duplex ultrasonography.

Chest or back pain is one of the most common and important complaints for aortic dissection. Around 80% of patients with aortic dissection present with initial chest pain (16, 17). However, when patients have some neurological manifestation at onset, only two-thirds complain to physicians about chest or back problems (17). Painless dissection should be associated with increased mortality, and is accompanied by syncope and neurological manifestations due to cerebral ischemia (18). The present results are partially in line with the report by Gaul et al (17). The reason for this may be that stroke patients with neurological deficit already experience a loss of consciousness or syncope at onset. When a patient is already unconscious on admission, recognition of precise complaints will obviously be difficult.

Neurological deficit on aortic dissection is mainly attributable to ischemia of the nervous system, such as the brain, spine and peripheral nerves. Neurological involvement was found in 30% of patients with aortic dissection (17). When we referred to post-marketing reports of stroke cases with aortic dissection treated by IV-tPA, all 9 cases showed left hemiparesis (19). The mechanism of cerebral ischemia fol-

Table 1. Backgrounds of acute stroke patients with aortic dissection

No	Year	First author	Age	Gender	Door to onset, h	LOC	Pain	Pulse	Hypotension	Paresis	XP	CDU	Territory	tPA	Surgery	Inhospital mortality
1	2008	Our cases	72	F	0.8	+	+	Rt.	+	L	NF	+	R MCA	-	-	+
2			72	F	1.9	+	-	Rt.	+	L	NF	+	R MCA	-	+	+
3	1996	Kimura	61	M	0.5	+	-	NA	-	R	NF	+	NF	-	+	-
4	1999	Flemming	72	F	0.3	+	NA	Rt.	-	L	Enl.	NA	R MCA	-	+	+
5	2000	Kubota	45	M	0.5	+	-	NA	-	L	NA	NA	R MCA	-	+	-
6	2000	Fessler	54	M	<3	+	-	Sym.	+	R	NF	NA	LMCA	+	-	+
7	2003	Wright	64	M	0.5	+	+	Rt.	+	-	NA	NA	LMCA	-	+	+
8	2003	Villa	60	M	0.5	+	-	NA	-	R	NF	NA	LMCA	-	-	+
9	2005	Chua	44	M	0.3	+	-	NA	NA	L	NA	NA	R MCA	+	+	-
10	2005	Uchino	56	F	0.8	-	+	Sym.	-	L	NF	+	R MCA	+	+	-
11	2006	Kawarabuki	79	F	0.5	+	-	NA	+	L	NA	NA	NF	-	-	+
12			60	M	0.6	+	-	NA	+	Bil	NA	NA	Bil MCA	-	-	+
13			64	F	0.5	-	-	Rt.	-	L	NA	+	R MCA	-	+	-
14	2006	Baydin	62	M	3	+	-	Sym.	+	L	Enl.	NA	NF	-	+	+
15	2006	Morita	86	F	0.3	+	-	NA	+	L	NA	NA	NF	-	-	+
16			59	M	0.6	-	-	NA	-	L	Enl.	NA	NF	-	+	-
17			56	M	0.3	-	-	Rt.	-	L	Enl.	NA	NF	-	+	-
18	2007	Stanley	68	F	2	+	-	Rt.	+	L	Enl.	NA	Bil MCA	-	-	+
19	2008	Yeh	56	F	0.5	+	+	NA	-	L	NF	+	R MCA	-	-	-

F.; female, M.; male, LOC; loss of consciousness, XP; chest roentgenography, CDU; carotid duplex ultrasonography, tPA; tissue plasminogen activator, Lt.; left side diminished, Rt.; right side diminished, NA; not available, Sym; Symmetrical, Bil; bilateral, Enl.; Enlargement, NF; no finding, MCA; middle cerebral artery

lowing aortic dissection may be considered as follows. In most Stanford type A dissections, the aortic wall seems to be laid open from the end of the aortic valve (2). First, when the pseudo-lumen of the aorta does not involve the innominate artery, major neurological deficits due to cerebral ischemia are rare. The arterial walls of the innominate and right common carotid arteries are separate, and neurological manifestations of the right hemisphere are found, such as left hemiparesis and spatial neglect. Finally, when aortic dissection spreads to other arteries that have branched from the aorta, right hemiparesis may be observed (2). With regard to this hypothesis, laterality of pulsation is an important component for initial diagnosis, as the innominate and right carotid arteries should be completely or partially occluded. Indeed, in previous reports including the present 2 cases, 6 of 7 patients with asymmetrical pulsation displayed left hemiparesis. We thus consider both asymmetric radial pulsation and left hemiparesis as warning signs for acute stroke with aortic dissection.

Concerning vascular ultrasound, duplex ultrasonography offers a sensitive and non-invasive tool for diagnosis of ca-

rotid arterial dissection when specific findings are identified (14). Established findings of arterial dissection on duplex ultrasonography are intramural hematoma, intimal flap, false lumen, and intra-arterial floating sign in the common carotid artery (4, 6, 14). Indeed, all 6 cases who underwent duplex ultrasonography had positive findings in common carotid artery. Where applicable, we recommend duplex ultrasonography for acute stroke patients with eligibility for IV-tPA immediately after admission.

In conclusion, 1% of hyper-acute ischemic stroke patients admitted to our facility seem to have aortic dissection. We urge caution for the possible presence of aortic dissection if asymmetrical pulses, hypotension and/or left hemiparesis are evident. Urgent estimation by duplex ultrasonography may play an important role in diagnosing cerebral malperfusion due to aortic dissection.

Acknowledgement

We have no conflict of interest disclosure. This manuscript has not been supported by any grant and we do not have a financial disclosure.

References

1. Khan IA, Nair CK. Clinical, diagnostic, and management perspectives of aortic dissection. *Chest* **122**: 311-328, 2002.
2. Morita S, Shibata M, Nakagawa Y, Yamamoto I, Inokuchi S. Painless acute aortic dissection with a left hemiparesis [online]. Available at: http://www.ncbi.nlm.nih.gov/entrez/query.fcgi?cmd=Retrieve&db=PubMed&dopt=Citation&list_uids=16757829 Accessed 3.
3. Yamaguchi T, Mori E, Minematsu K, et al. Alteplase at 0.6 mg/kg for acute ischemic stroke within 3 hours of onset: Japan Alteplase Clinical Trial (J-ACT). *Stroke* **37**: 1810-1815, 2006.
4. Kawarabuki K, Sakakibara T, Hirai M, et al. Acute aortic dissection presenting as a neurologic disorder. *J Stroke Cerebrovasc Dis* **15**: 26-29, 2006.
5. Stanley I, Sharma VK, Tsvigoulis G, Lao AY, Alexandrov AV. Painless aortic dissection with unusual extension into intracranial internal carotid arteries. *Cerebrovasc Dis* **24**: 314-315, 2007.
6. Yeh JF, Po H, Chien CY. Ischaemic infarction masking aortic dissection: a pitfall to be avoided before thrombolysis. *Emerg Med J*

- 24:** 594-595, 2007.
- 7.** Baydin A, Nargis C, Nural MS, Aygun D, Karatas AD, Bahcivan M. Painless, acute aortic dissection presenting as an acute stroke. *Mt Sinai J Med* **73:** 1129-1131, 2006.
 - 8.** Chua CH, Lien LM, Lin CH, Hung CR. Emergency surgical intervention in a patient with delayed diagnosis of aortic dissection presenting with acute ischemic stroke and undergoing thrombolytic therapy. *J Thorac Cardiovasc Surg* **130:** 1222-1224, 2005.
 - 9.** Uchino K, Estrera A, Calleja S, Alexandrov AV, Garami Z. Aortic dissection presenting as an acute ischemic stroke for thrombolysis. *J Neuroimaging* **15:** 281-283, 2005.
 - 10.** Wright V, Horvath R, Baird AE. Aortic dissection presenting as acute ischemic stroke. *Neurology* **61:** 581-582, 2003.
 - 11.** Villa A, Molgora M, Licari S, Omboni E. Acute ischemic stroke, aortic dissection, and thrombolytic therapy. *Am J Emerg Med* **21:** 159-160, 2003.
 - 12.** Flemming KD, Brown RD Jr. Acute cerebral infarction caused by aortic dissection: caution in the thrombolytic era. *Stroke* **30:** 477-478, 1999.
 - 13.** Kubota T, Niwa J, Chiba M, Mikami T, Oka S. Common carotid artery dissection propagated from acute aortic dissection: a case successfully treated by PTA. *No Shinkei Geka* **28:** 1015-1021, 2000.
 - 14.** Kimura K, Hashimoto Y, Dosaka A, Terasaki T, Uchino M. A case report of thoracic aortic and common carotid artery dissecting aneurysm diagnosed by duplex ultrasound examination. *Rinsho Shinkeigaku* **36:** 348-351, 1996.
 - 15.** Fessler AJ, Alberts MJ. Stroke treatment with tissue plasminogen activator in the setting of aortic dissection. *Neurology* **54:** 1010, 2000.
 - 16.** Hagan PG, Nienaber CA, Isselbacher EM, et al. The International Registry of Acute Aortic Dissection (IRAD): new insights into an old disease. *Jama* **283:** 897-903, 2000.
 - 17.** Gaul C, Dietrich W, Friedrich I, Sirch J, Erbguth FJ. Neurological symptoms in type A aortic dissections. *Stroke* **38:** 292-297, 2007.
 - 18.** Park SW, Hutchison S, Mehta RH, et al. Association of painless acute aortic dissection with increased mortality. *Mayo Clin Proc* **79:** 1252-1257, 2004.
 - 19.** Nakagawara J. A discussion on reported 10 cases given alteplase and author's series of acute ischemic stroke with acute aortic dissection. *Jpn J Stroke* **30:** 452-454, 2008.