

Symptomatic Cerebral Vasospasm of Unusually Late Onset After Aneurysm Rupture

K. Ohno¹, H. Masaoka¹, R. Suzuki¹, S. Monma², and Y. Matsushima¹

¹Department of Neurosurgery, Tokyo Medical and Dental University, Tokyo, and ²Department of Neurosurgery, Fujiyoshida City Hospital, Yamanashi, Japan

Summary

An unusually late occurrence of symptomatic cerebral vasospasm is reported. The case involves a 50-year-old male who was uneventfully operated on for a ruptured anterior communicating artery aneurysm, with no symptom of cerebral vasospasm, 17 days after sustaining the subarachnoid haemorrhage. Two days after surgery, a right hemiparesis developed and angiography disclosed severe cerebral vasospasm. This case history and the aetiological factors of symptomatic vasospasm are discussed.

Keywords: Symptomatic vasospasm; delayed operation; late onset.

Introduction

Cerebral vasospasm that follows aneurysm rupture usually occurs within two weeks after subarachnoid haemorrhage (SAH), and the subsequent ischaemic neurological symptoms are reported to develop immediately or at most a day later when they occur¹⁷. Thus, in several series of patients examined, the latest dates on which symptomatic vasospasm appeared were the 14th and 15th day after the SAH (the day of the SAH has been standardized as Day 0 for this article)^{1, 5, 13, 17, 23}.

However, five cases involving a delayed onset of symptomatic vasospasm which developed 16 days or more after SAH were presented in Japan at a meeting that centered on unusual vasospasm¹¹. In this article, we add a further case of unusual symptomatic vasospasm. This case involved delayed surgery and the symptoms developed on the 19th day after the SAH from an anterior communicating artery aneurysm.

Case Report

A 50-year-old boatman suddenly developed a headache on November 12, 1982. He was admitted to our hospital the next morning,

at which time the patient's grade (Hunt and Kosnik³) was determined as being IV. The patient was stuporous and had a stiff neck. There was no apparent paralysis of the extremities and his blood pressure was 170/120 mm Hg. A computerized tomography (CT) scan revealed high density areas in the basal cisterns and Sylvian fissures, indicating severe SAH (group 3, according to Fisher²); a moderate communicating hydrocephalus also was noticed (Fig. 1). Carotid angiograms, uneventfully performed soon after admission, disclosed an aneurysm of the anterior communicating artery and fenestration at the M1 portion of the left middle cerebral artery (Fig. 2, upper). External ventricular drainage of the cerebrospinal fluid (CSF) was performed for treatment of the hydrocephalus on the day of admission. The CSF was markedly bloody and its pressure was 250 mm H₂O. The drainage gradient was set at 15 cm H₂O.

After this procedure, the patient's consciousness gradually improved to the level of simple verbal responses, and no sign of cerebral vasospasm was detected. Direct surgery to treat the ruptured aneurysm was postponed in accordance with our policy at that time, which required us to delay such an operation. A left carotid angiogram, repeated on the 9th day after the SAH, demonstrated slight vasospasm in the main cerebral arteries (Fig. 2, center), but there was no sign of rebleeding. Fluid therapy was maintained to keep an

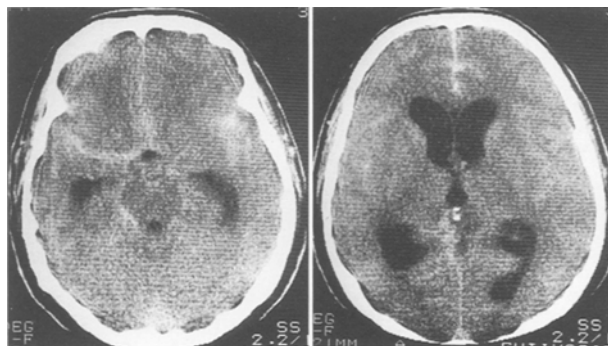


Fig. 1. Plain computerized tomography scans obtained on admission showing thick high density areas in the Sylvian and interhemispheric fissures, and the dilated third and lateral ventricles

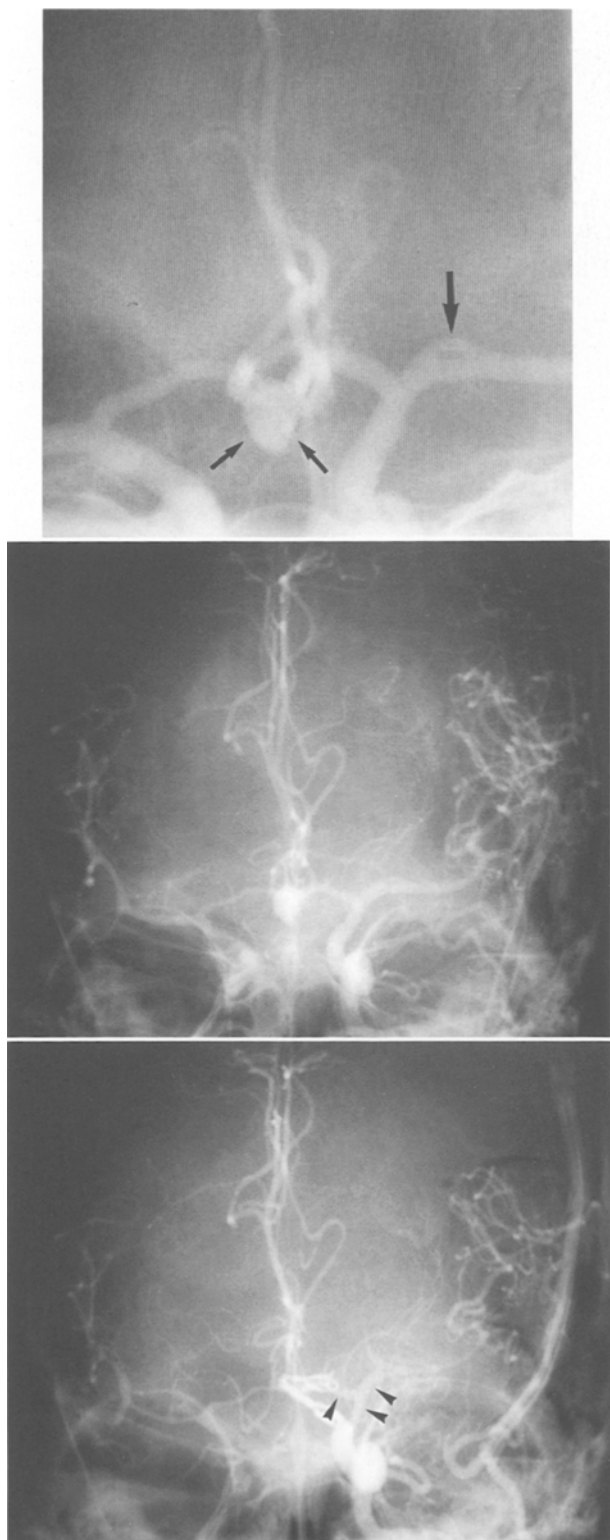


Fig. 2. Upper: Left carotid angiogram obtained on admission (on the 1st day after SAH). Antero-posterior view demonstrating an anterior communicating artery aneurysm (small arrows) and fenestration at the M1 portion of the left middle cerebral artery (large arrow). Center: Left carotid angiogram performed on the 9th day after SAH. Antero-posterior view showing slight but diffuse vaso-

adequate fluid balance, which occasionally tended to become negative.

On the 17th day after the SAH, there was no evidence of any ischaemic symptoms and a left frontotemporal craniotomy was performed for clipping of the neck of the aneurysm. On dural opening, old clots were seen scattered in the subarachnoid space. The cisterns around the left internal carotid and anterior cerebral arteries were packed with degenerated blood clots, and these clots were removed. These procedure, however, caused no release of CSF. Furthermore, there was not apparent vasoconstriction seen in either the left internal or the anterior cerebral arteries, and the aneurysm was obliterated with two Yasargil's clips. During the dissection of the neck of the aneurysm, a flow of CSF from the interhemispheric fissure was seen. The external ventricular drainage was changed to a ventriculo-peritoneal shunt. After recovering from the anaesthesia, the patient returned to his preoperative neurological state.

Two days later (on the 19th day after the SAH), the patient developed a right hemiparesis and manifested a slightly lowered level of consciousness. Carotid angiograms disclosed severe vasospasm of the right anterior cerebral and the middle cerebral arteries, as well as of the left middle cerebral artery (Fig. 2, lower). Most areas of the arteries, from which clots had been removed during the operation, remained free from the progress of the vasospasm, though the left internal carotid artery was seen to be slightly more constricted than it had appeared on the preoperative angiogram. On a CT scan performed on the same day, the Sylvian fissures were not yet delineated (Fig. 3, A and B). Fluid balance was transiently negative by approximately 1200 ml during the postoperative period until the development of symptoms, though his systolic blood pressure ranged from 120 mm Hg to 160 mm Hg. Hypervolaemic and hypertensive therapy thus was applied soon after angiography. However, a CT scan taken the next day showed a left parietal low density area (Fig. 3, C).

Paresis of the patient's right leg vanished completely within a month, but paresis of the right upper extremity and mild dysarthria persisted. A year later, he returned to his previous occupation, though he still displayed a moderate disability in his right forearm and fingers.

Discussion

Cerebral vasospasm usually occurs with or without ischaemic symptoms from 4 to 14 days after SAH and then begins to subside^{20, 23}. Although Kwak *et al.*⁶ have reported that angiographic vasospasm is still seen later than 18 days after SAH in 9% of cases with ruptured cerebral aneurysms, based on our clinical experiences and several studies^{1, 5, 11, 13, 16, 23}, it is extremely rare that ischaemic neurological symptoms due to vasospasm first appear later than at two weeks. According to the 7 studies that have been reported, which include our

spasm in the main cerebral arteries. Lower: Left carotid angiogram performed two days after operation (on the 19th day after SAH). Antero-posterior view demonstrating aggravation of vasospasm. Note that the degree of constriction of the left anterior and middle cerebral arteries where clots were removed is less severe (arrow heads)

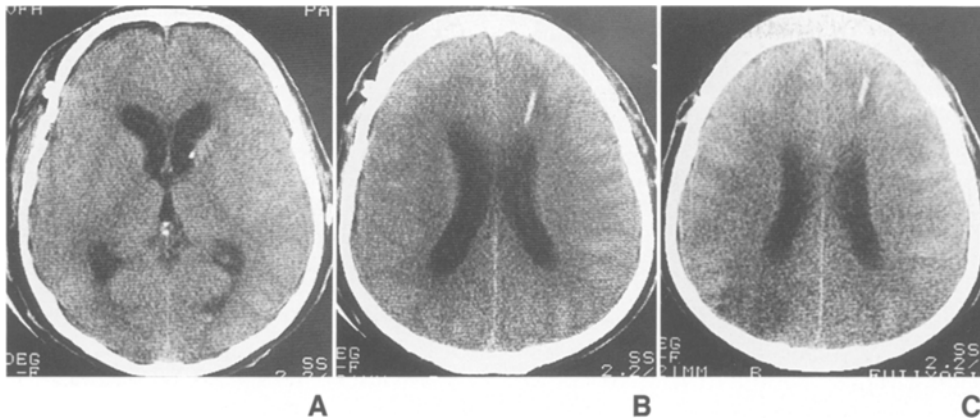


Fig. 3. Plain computerized tomography scans (A, B) performed because of the development of neurological symptoms two days after surgery showing that the size of the lateral ventricles was reduced, but that Sylvian fissures were not yet delineated. The next day a low density area appeared in the left parietal lobe (C)

own¹⁰, in which the interval from the SAH to the onset of the ischaemic symptoms was investigated, out of a total of 499 patients who had symptomatic vasospasm, only three (0.6%) had symptoms which developed later than 16 days after the SAH (Table 1). These reports also show that the incidence of symptomatic vasospasm ranges from 18% to 50% as a whole.

The aetiology of cerebral vasospasm is believed to be chemical or neurogenic in origin, and a hypothalamic dysfunction or excitation^{15,24}, the breakdown products of subarachnoid clots^{9,12,18,21}, and/or mechanical actions, such as arterial manipulation¹⁵, are regarded as the causative mechanisms. More recently, the role of inflammation in response to subarachnoid blood¹⁴ or endothelin⁸, which is a novel endothelium-derived vasoconstrictor peptide, in the mechanism of vasospasm has been noted. However, additional factors would seem to be necessary to account for why symptomatic vasospasm develops so late after the SAH.

In the five reported cases involving a delayed onset of symptomatic vasospasm, a hypothalamic dysfunction, hypovolaemia, spasmogenic substances or an abrupt cessation of hypertensive and hypervolaemic therapy have been postulated as being the possible causes for such unusually delayed vasospasm¹¹. Accordingly, Abiko *et al.*¹¹ have suggested that preventive treatment against vasospasm should be gradually withdrawn in patients with severe SAH.

It has been noted that the onset of postoperative vasospasm is not related to the timing of the operation but as to when the SAH has occurred¹⁷, and it also has been commonly believed that vasospasm is not aggravated by surgical intervention beyond two weeks after the SAH. However, since the symptoms due to vasospasm in our patient developed two days after delayed surgery, it seems that the occurrence of the symptoms was associated with surgical intervention.

Table 1. Interval from SAH to the Onset of Symptomatic Vasospasm in Reported Series

Authors (year)	No. of patients with symptomatic vasospasm	Days after SAH
Fisher <i>et al.</i> (1977) ¹	25 (50)*	3–15
Saito <i>et al.</i> (1977) ¹⁶	96 (428)	4–15
Weir (1980) ²³	19 (100)	4–14
Kodama <i>et al.</i> (1980) ⁵	151 (827)	4–15
Pasqualin <i>et al.</i> (1984) ¹³	83 (242)	3–15
Abiko <i>et al.</i> (1988) ¹¹	102 (451)	3–15, 17#, 18#
Ohno <i>et al.</i> (1990) ¹⁰	23 (92)	5–13, 19#

* Total patients with ruptured intracranial aneurysms in parentheses.

Only one case in each.

One of the more probable factors that make vasospasm symptomatic may be the systemic condition of a patient which includes hypotension and hypovolaemia due to the lowered homeostasis^{4,7,22}. Maroon and Nelson⁷, and Solomon *et al.*¹⁹ have pointed out that systemic hypovolaemia commonly occurs after SAH and this may play a critical role in the pathophysiology of ischaemia in patients with ruptured intracranial aneurysms. Furthermore, Voldby *et al.*²² have observed that cerebral autoregulation was found to be impaired in patients with cerebral vasospasm. Thus, there is the possibility that an artificial fluid administration resulted in an insidious circulatory imbalance in our patient, though our intended treatment had been to keep the same fluid balance for 19 days. A further change in the circulatory volume during the peri-operative period may have made the vasospasm symptomatic.

Next, from our observations during surgery, it appears that the role of the fixed subarachnoid clots found in our patient may have been of special importance.

Experimental studies^{9,18} have indicated that a mixture of aged whole blood and the CSF, and aged whole blood alone both produce a vascular contraction, and that the vaso-activity of the former is greater than that of the latter. In our patient, who had suffered severe SAH, external ventricular CSF drainage was performed to treat the hydrocephalus, due to a blockage of the CSF pathway, and the thick subarachnoid clots that were seen fixed about the main cerebral vessels had received no dilution or washing by the CSF. Thus, the breakdown products of these blood clots also may have remained in these regions for a longer period than usual. Given this scenario, it seems possible that CSF contact with the breakdown products of the clots by our surgical intervention augmented vasospasm in the high concentration areas of the thick clots.

Arterial manipulation during the operation also may have played a role in the development of the symptomatic vasospasm. However, it is unlikely that aggravation of the vasospasm was due to some mechanical action in our patient, because changes in the manipulated clot-free portions of the cerebral vessels were not severe on angiographic assessment.

Although these attempts to explain the pathophysiology which may have caused the delayed onset of symptomatic vasospasm in our patient are all speculative, we think that such unusual cases are worth describing even though they are rare, because the causative mechanism of cerebral vasospasm itself has yet to be fully elucidated. Furthermore, it also should be kept in mind in clinical practice that potential cerebral vasospasm which can turn symptomatic due to some additional factors, may persist for a longer period than usual in some patients with a ruptured aneurysm.

Acknowledgement

The authors wish to thank Dr. Kimiyoshi Hirakawa (Professor, Department of Neurosurgery, Tokyo Medical and Dental University) for his helpful comments.

References

- Fisher CM, Roberson GH, Ojemann RG (1977) Cerebral vasospasm with ruptured saccular aneurysm – The clinical manifestations. *Neurosurgery* 1: 245–248
- Fisher CM, Kistler JP, Davis JM (1980) Relation of cerebral vasospasm to subarachnoid hemorrhage visualized by computerized tomographic scanning. *Neurosurgery* 6: 1–9
- Hunt WE, Kosnik EJ (1974) Timing and perioperative care in intracranial aneurysm surgery. *Clin Neurosurg* 11: 79–89
- Kindt GW, McGillicuddy J, Pritz M, Giannota S (1980) Hypertension and hypervolemia as therapy for patients with vasospasm. In: Wilkins RH (ed) *Cerebral arterial spasm*. Williams & Wilkins, Baltimore, pp 659–664
- Kodama N, Mizoi K, Sakurai Y, Suzuki J (1980) Incidence and onset of vasospasm. In: Wilkins RH (ed) *Cerebral arterial spasm*. Williams & Wilkins, Baltimore, pp 361–365
- Kwak R, Niizuma H, Ohi T, Suzuki J (1979) Angiographic study of cerebral vasospasm following rupture of intracranial aneurysms: Part I. Time of the appearance. *Surg Neurol* 11: 257–262
- Maroon JC, Nelson PB (1979) Hypovolemia in patients with subarachnoid hemorrhage: Therapeutic implications. *Neurosurgery* 4: 223–226
- Masaoka H, Suzuki R, Hirata Y, Emori T, Marumo F, Hirakawa K (1989) Raised plasma endothelin in aneurysmal subarachnoid haemorrhage. *Lancet* 8676: 1402
- Miyaoka M, Nonaka R, Watanabe H, Chigasaki H, Ishii S (1976) Etiology and treatment of prolonged vasospasm. – Experimental and clinical studies. *Neurol Med Chir* 16: 103–114
- Ohno K, Suzuki R, Masaoka H, Monma S, Matsushima Y, Inaba Y (1988) A review of 102 consecutive patients with intracranial aneurysms in a community hospital in Japan. *Acta Neurochir (Wien)* 94: 23–27
- Ohta T, Kikuchi H, Takakura K (eds) (1988) *Cerebral vasospasm*, Vol 3. Chugaiigakusha, Tokyo
- Osaka K (1977) Prolonged vasospasm produced by the breakdown products of erythrocytes. *J Neurosurg* 47: 403–411
- Pasqualin A, Rosta L, Da Pian R, Cavazzani P, Scienza R (1984) Role of computed tomography in the management of vasospasm after subarachnoid hemorrhage. *Neurosurgery* 15: 344–353
- Peterson JW, Roussos L, Kwun B, Hackett JD, Owen CJ, Zervas NT (1990) Evidence of the role of hemolysis in experimental cerebral vasospasm. *J Neurosurg* 72: 775–781
- Raynor RB, Messer HD (1980) Severe vasospasm with an unruptured aneurysm: Case report. *Neurosurgery* 6: 92–95
- Saito I, Ueda Y, Sano K (1977) Significance of vasospasm in the treatment of ruptured intracranial aneurysms. *J Neurosurg* 47: 412–429
- Saito I, Sano K (1980) Vasospasm after aneurysm rupture: Incidence, onset, and course. In: Wilkins RH (ed) *Cerebral arterial spasm*. Williams & Wilkins, Baltimore, pp 294–301
- Shimizu T, Kito K, Hoshi T, Yamazaki N, Takahashi K, Takahashi M, Yamane K, Sim Ch, Kitamura K, Senda Sh (1982) Immunological study of late cerebral vasospasm in subarachnoid hemorrhage. *Neurol Med Chir* 22: 613–619
- Solomon RA, Post KD, McMurtry III JG (1984) Depression of circulating blood volume in patients after subarachnoid hemorrhage: Implications for the management of symptomatic vasospasm. *Neurosurgery* 15: 354–361
- Suzuki J, Hori S (1975) Prediction of reattacks following rupture of intracranial aneurysms. *Neurol Med Chir* 15: 35–39
- Suzuki J, Yoshimoto T (1982) Ultra-early surgery of intracranial aneurysm. *Neurol Surg (Tokyo)* 10: 1139–1149
- Volby B, Enevoldsen EM, Jensen FT (1985) Cerebrovascular reactivity in patients with ruptured intracranial aneurysms. *J Neurosurg* 62: 59–67
- Weir BA (1980) The incidence and onset of vasospasm after subarachnoid hemorrhage from ruptured aneurysm. In: Wilkins RH (ed) *Cerebral arterial spasm*. Williams & Wilkins, Baltimore, pp 302–305
- Wilkins RH (1975) Hypothalamic dysfunction and intracranial arterial spasms. *Surg Neurol* 4: 472–480

Correspondence and Reprints: Kikuo Ohno, M.D., Department of Neurosurgery, Tokyo Medical and Dental University, 1-5-45 Yushima, Bunkyo-ku, Tokyo 113, Japan.