



**University of
Zurich**^{UZH}

**Zurich Open Repository and
Archive**

University of Zurich
University Library
Strickhofstrasse 39
CH-8057 Zurich
www.zora.uzh.ch

Year: 2010

Wolff-Parkinson-White syndrome in a child with recurrent seizures

Poretti, A ; Balmer, C

DOI: <https://doi.org/10.1017/S1047951109991004>

Posted at the Zurich Open Repository and Archive, University of Zurich

ZORA URL: <https://doi.org/10.5167/uzh-44441>

Journal Article

Published Version

Originally published at:

Poretti, A; Balmer, C (2010). Wolff-Parkinson-White syndrome in a child with recurrent seizures. *Cardiology in the Young*, 20(1):78-79.

DOI: <https://doi.org/10.1017/S1047951109991004>

Images in Congenital Cardiac Disease

Wolff-Parkinson-White syndrome in a child with recurrent seizures

Andrea Poretti,¹ Christian Balmer²

¹Department of Neurology; ²Department of Cardiology, University Children's Hospital of Zurich, Switzerland

Keywords: MELAS; ventricular hypertrophy; epilepsy

Received: 11 November 2008; Accepted: 9 August 2009; First published online 17 February 2010

A 7-YEAR-OLD BOY WAS OBSERVED TO HAVE A short PR interval on monitoring during anaesthesia for tonsillectomy. Subsequent twelve-lead electrocardiograms (Fig 1) showed Wolff-Parkinson-White syndrome with delta waves seen best in leads I, II, and V3–V5, and a broad QRS complex. This was confirmed by electrophysiologic study, during which a left lateral accessory pathway with rapid antegrade conduction, down to a cycle length of 170 milliseconds, was successfully catheter ablated (arrow).

At the age of 12 years, the patient experienced the onset of headache, vomiting, impaired visual acuity, and recurrent focal seizures. Blood and cerebrospinal fluid lactate were increased at 5.6 millimoles per litres with a reference unit of 1.0–2.6 millimoles per litres and 3.7 millimoles per litres with a reference unit of 0.9–2.2 millimoles per litres, respectively. Electroencephalogram showed epileptic discharges on the left occipital region, while magnetic resonance imaging of the brain revealed localised T2-hyperintensity of the left occipital cortex and cerebellar atrophy. The echocardiogram (Fig 2) in the parasternal long (a) and short (b) axis views demonstrated, for the first time, concentric left ventricular hypertrophy (arrows). The left ventricular posterior wall measured 11 millimetres – the upper limit of normal was 8 millimetres – and the ventricular function was normal, without outflow obstruction. MELAS syndrome

(mitochondrial myopathy, encephalopathy, lactic acidosis, and stroke-like episodes) was suspected, and the diagnostic A3243G mutation in mitochondrial

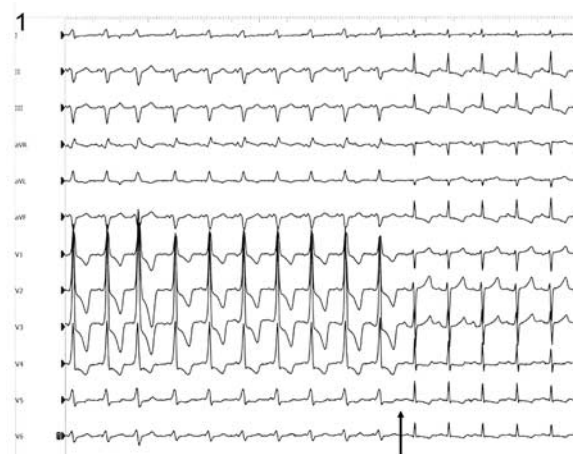

Figure 1.

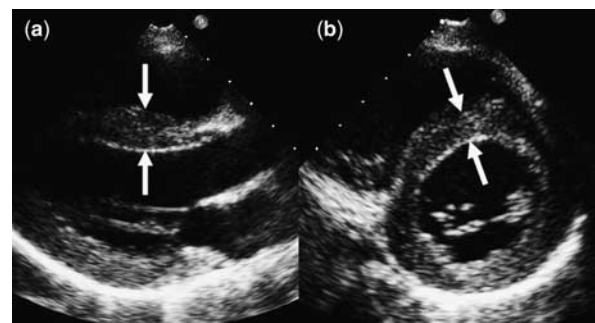


Figure 2.

tRNA was identified with a mutation load of 57% in blood lymphocytes.

MELAS syndrome is known to be associated with both hypertrophic cardiomyopathy and conduction abnormalities, presumably as the consequence of impairment of oxidative phosphorylation in tissues with high energy demands.¹ Wolff-Parkinson-White Syndrome occurs at least four times more frequently in patients with MELAS syndrome than in the normal population that is, 13% versus 1.5 to 3.1%. Moreover, as illustrated by our case, cardiac arrhythmias may precede neurological manifestations by many months or years, and patients who experience conduction abnormalities may have an earlier onset of neurological

symptoms. In patients with Wolff-Parkinson-White Syndrome and neurological symptoms, the presence of a MELAS syndrome should be considered.

Acknowledgements

We thank Prof. Sabina Gallati, Division of Human Genetics, University Children's Hospital of Berne, Switzerland, for performing mutation analysis.

Reference

1. Sproule DM, Kaufmann P, Engelstad K, Starc TJ, Hordof AJ, De Vivo DC. Wolff-Parkinson-White syndrome in Patients with MELAS. *Arch Neurol* 2007; 64: 1625–1627.