



Published in final edited form as:

J Child Neurol. 2010 June ; 25(6): 776–779. doi:10.1177/0883073809346349.

Hyperperfusion on Magnetic Resonance Imaging in Acute Chemotherapy-Related Leukoencephalopathy

Lisa Michael El-Hakam, MD¹, Melissa Beth Ramocki, MD, PhD¹, James John Riviello, MD¹, and Anna Illner, MD²

¹Department of Pediatrics, Section of Pediatric Neurology and Developmental Neuroscience, Baylor College of Medicine, Texas Children's Hospital, Houston, Texas

²Department of Radiology, Baylor College of Medicine, Texas Children's Hospital, Houston, Texas

Abstract

Acute chemotherapy-related leukoencephalopathy can present similar to acute stroke with symptoms including aphasia, dysarthria, and hemiplegia. Differentiation based on clinical appearance is challenging, and physicians must distinguish between the 2 conditions rapidly to institute appropriate therapies. An 8-year-old male with acute lymphoblastic leukemia receiving chemotherapy, including intrathecal methotrexate, presented to our emergency center with 2 hours of expressive aphasia and flaccid right hemiplegia. Emergent magnetic resonance imaging (MRI) was obtained, demonstrating diffusion restriction within bilateral corona radiata and centrum semiovale. Magnetic resonance perfusion revealed mildly increased perfusion, a finding inconsistent with ischemic stroke and previously unreported in acute chemotherapy-related leukoencephalopathy without necrosis. This increased perfusion conclusively eliminated stroke from the clinical differential. Magnetic resonance perfusion imaging proved valuable to rapidly distinguish acute chemotherapy-related leukoencephalopathy from ischemia, and the evaluation of perfusion alterations in this disorder may provide further insight into the pathophysiology of this entity.

Keywords

magnetic resonance perfusion; leukoencephalopathy; chemotherapy; magnetic resonance imaging; methotrexate

Acute chemotherapy-related leukoencephalopathy can present with dramatic neurological deficits that mimic devastating, large territory strokes, such as aphasia, hemiplegia, and altered mental status in children and adults,¹ presenting a significant diagnostic challenge to clinicians. This form of chemotherapy-related neurotoxicity is associated with hypodensity of white matter on computed tomography (CT) of the brain and areas of diffusion restriction and high T2 signal intensity with magnetic resonance imaging (MRI).^{2–4} Methotrexate is the most commonly implicated chemotherapeutic drug, occurring with intrathecal, intravenous, and oral routes of administration.^{1,5} Other chemotherapeutic agents, including 5-fluorouracil, carmofur, and capecitabine, can cause similar neurotoxicity.¹

© The Author(s) 2010

Corresponding Author: Lisa Michael El-Hakam, MD, Department of Pediatric Neurology, Baylor College of Medicine, Texas Children's Hospital, 6621 Fannin St CC 1250, Houston, TX 77030, hakam@bcm.edu.

Reprints and permission: <http://www.sagepub.com/journalsPermissions.nav>

Declaration of Conflicting Interests

The authors declared no potential conflicts of interests with respect to the authorship and/or publication of this article.

Patients with cancer have an increased risk of stroke and can develop acute small vessel ischemia or venous infarction with imaging abnormalities centered in the deep white matter.^{6,7} This could radiographically appear similar to acute chemotherapy-related leukoencephalopathy, particularly if imaged less than 6 hours after ictus onset or if the imaging findings are unilateral in distribution. This case demonstrates the use of magnetic resonance perfusion imaging, allowing for the rapid distinction between acute chemotherapy-related leukoencephalopathy and stroke in a young child with dramatic neurological deficits during his presentation to our hospital.

Case Report

An 8-year-old boy with acute lymphoblastic leukemia, treated with intravenous cytarabine, vincristine, pegasparginase, and intrathecal methotrexate, presented with sudden onset of 2 hours of difficulty speaking and right-side weakness. On neurological examination, he had a severe expressive aphasia, moderate dysarthria, mild facial weakness, and right-side hemiplegia with no effort against gravity in the arm and leg. These findings yielded a score of 10 points (2 for language, 1 for dysarthria, 1 for facial weakness, and 6 for right-side arm and leg weakness) on the National Institutes of Stroke Scale, a scale validated for the rapid neurological examination of adults with suspected stroke, examining the level of consciousness, vision and gaze, facial palsy, extremity weakness, limb ataxia, sensory loss, language, dysarthria, and neglect (0 = *no deficit*, 42 = *maximum recordable score*). This child's score of 10 indicated that his deficits were moderate in severity. Symptoms occurred 5 days after receiving intrathecal methotrexate and initiating a 4-day course of intravenous cytarabine. Pegasparginase was last received 1 month prior to the onset of his neurological change. Noncontrast CT of the head was normal. He underwent emergent MRI and magnetic resonance perfusion imaging of the brain. Diffusion-weighted imaging (Figure 1A) and apparent diffusion coefficient mapping (Figure 1B) demonstrated diffusion restriction within bilateral corona radiata and centrum semiovale. The lesions were minimally perceptible on T2 (Figure 1C) and fluid-attenuated inversion recovery images. Magnetic resonance perfusion imaging showed increased perfusion in the left corona radiata and centrum semiovale (Figure 1D, arrow), with an increased negative enhancement integral, indicating increased blood flow within the left-side lesion (Figure 1F). Based on the MRI and perfusion findings, a diagnosis of acute chemotherapy-related leukoencephalopathy was made. The patient's symptoms completely resolved within 48 hours.

Discussion

Our young patient presented to the emergency department with an acute onset of hemiplegia and aphasia. Abrupt onset of focal neurological signs in a patient with malignancy leads to a broad differential, including ischemic stroke, intracerebral hemorrhage, infection, tumor expansion, and chemotherapy-related complications, requiring neuroimaging to aid in the diagnosis. Typical MRI findings of acute chemotherapy-related leukoencephalopathy include patchy areas of diffusion restriction in the corona radiata and centrum semiovale.^{4,8,9} T2-weighted sequences typically appear normal or show very faint prolongation in the areas of diffusion restriction.^{4,8,9} Baehring and Fulbright described 27 cases of acute leukoencephalopathy with stroke-like symptoms and diffusion restriction in patients treated with methotrexate (intrathecal or systemic), 5-fluorouracil, carmofur, or capecitabine.¹ While diffusion restriction within a vascular territory is typical for acute embolic stroke, the diffusion restriction observed with acute chemotherapy-related leukoencephalopathy is often not confined to a distinct vascular territory.^{1,8} Patients with cancer, however, can develop acute small vessel ischemia or venous infarction with imaging abnormalities centered in the deep white matter.^{6,7} This can appear similar to acute chemotherapy-related leukoencephalopathy, particularly if imaged less than 6 hours after ictus onset.

Rapid distinction between these 2 entities affects treatment and prognosis. While acute chemotherapy-related leukoencephalopathy may have a dramatic stroke-like presentation with severe deficits, including altered mental status, hemiplegia, and aphasia, symptoms generally resolve.¹ Treatment may consist of observation and supportive care alone, or therapies such as dextromethorphan, aminophylline, intravenous immunoglobulin, and folinic acid.^{1,10} In contrast, stroke in the setting of cancer, such as leukemia, warrants a thorough evaluation of the etiology, which can be tumor, coagulation abnormalities, chemotherapy, radiotherapy, infection, or paraneoplastic syndromes,^{6,7} and may require emergent leukopheresis or anticoagulation.¹¹

Perfusion imaging is often used in conjunction with diffusion-weighted imaging in the evaluation of acute stroke to assess penumbral size and distribution. Areas of acute ischemia are hypoperfused on magnetic resonance perfusion imaging.¹² The use of magnetic resonance perfusion has been rarely described in acute chemotherapy-related leukoencephalopathy. Raghavendra et al reported decreased perfusion within the perilesional edema with increased lesional perfusion associated with a case of acute necrotizing leukoencephalopathy following oral methotrexate.⁵ Eichler et al reported absence of a perfusion deficit in a patient with leukoencephalopathy, following high-dose intravenous methotrexate.⁹ A study of magnetic resonance perfusion in swine brain showed no change in brain perfusion after methotrexate exposure.¹³

The pathophysiological mechanism underlying acute chemotherapy-related leukoencephalopathy is unknown. Metabolic changes with myelin swelling, granulation, and myelin loss have been documented in vitro.^{1,14} The observation of hyperperfusion in the setting of acute chemotherapy-related leukoencephalopathy further suggests that there is no ischemic etiology to the areas of diffusion restriction. Further studies are necessary to delineate the pathophysiology of this disorder.

Hypoperfusion has never been reported with acute chemotherapy-related leukoencephalopathy, as would be expected with an acute stroke. In our case, the additional finding of hyperperfusion rather than hypoperfusion on magnetic resonance perfusion confidently excluded the diagnosis of stroke. Magnetic resonance perfusion imaging was thus a useful tool in the radiological distinction between stroke and acute chemotherapy-related leukoencephalopathy. Large-scale prospective studies are warranted to evaluate the use of magnetic resonance perfusion imaging to distinguish between acute stroke and acute chemotherapy-related leukoencephalopathy.

Acknowledgments

The authors would like to acknowledge Robert McNeil, Texas Children's Hospital, Pediatric Neurology Research Coordinator, for his technical assistance.

Funding

The authors disclosed receipt of the following financial support for the research and/or authorship of this article: MBR acknowledges the support of NIH/NINDS grant 5K08NS062711-02. The content is solely the responsibility of the authors and does not necessarily represent the official views of NINDS or the National Institutes of Health.

References

1. Baehring JM, Fulbright RK. Delayed leukoencephalopathy with stroke-like presentation in chemotherapy recipients. *J Neurol Neurosurg Psychiatry* 2008;79(5):535–539. [PubMed: 17682013]
2. Mahoney DH Jr, Shuster JJ, Nitschke R, et al. Acute neurotoxicity in children with B-precursor acute lymphoid leukemia: an association with intermediate-dose intravenous methotrexate and intrathecal

- triple therapy—a Pediatric Oncology Group study. *J Clin Oncol* 1998;16(5):1712–1722. [PubMed: 9586883]
3. Packer RJ, Zimmerman RA, Bilaniuk LT. Magnetic resonance imaging in the evaluation of treatment-related central nervous system damage. *Cancer* 1986;58(3):635–640. [PubMed: 3731021]
 4. Inaba H, Khan RB, Laningham FH, Crews KR, Pui CH, Daw NC. Clinical and radiological characteristics of methotrexate-induced acute encephalopathy in pediatric patients with cancer. *Ann Oncol* 2008;19(1):178–184. [PubMed: 17947226]
 5. Raghavendra S, Nair MD, Chemmanam T, Krishnamoorthy T, Radhakrishnan VV, Kuruvilla A. Disseminated necrotizing leukoencephalopathy following low-dose oral methotrexate. *Eur J Neurol* 2007;14(3):309–314. [PubMed: 17355553]
 6. Grisold W, Oberndorfer S, Struhal W. Stroke and cancer: a review. *Acta Neurol Scand* 2009;119(1):1–16. [PubMed: 18616624]
 7. Cestari DM, Weine DM, Panageas KS, Segal AZ, DeAngelis LM. Stroke in patients with cancer: incidence and etiology. *Neurology* 2004;62(11):2025–2030. [PubMed: 15184609]
 8. Haykin ME, Gorman M, van Hoff J, Fulbright RK, Baehring JM. Diffusion-weighted MRI correlates of subacute methotrexate-related neurotoxicity. *J Neurooncol* 2006;76(2):153–157.
 9. Eichler AF, Batchelor TT, Henson JW. Diffusion and perfusion imaging in subacute neurotoxicity following high-dose intravenous methotrexate. *Neuro Oncol* 2007;9(3):373–377. [PubMed: 17522329]
 10. Drachtman RA, Cole PD, Golden CB, et al. Dextromethorphan is effective in the treatment of subacute methotrexate neurotoxicity. *Pediatr Hematol Oncol* 2002;19(5):319–327. [PubMed: 12078863]
 11. Hsu WH, Chu SJ, Tsai WC, Tsao YT. Acute myeloid leukemia presenting as one-and-a-half syndrome. *Am J Emerg Med* 2008;26(4) 513 e1-2.
 12. Olivot JM, Mlynash M, Thijs VN, et al. Relationships between infarct growth, clinical outcome, and early recanalization in diffusion and perfusion imaging for understanding stroke evolution (DEFUSE). *Stroke* 2008;39(8):2257–2263. [PubMed: 18566302]
 13. Makiranta MJ, Lehtinen S, Jauhiainen JP, Oikarinen JT, Pyhtinen J, Tervonen O. MR perfusion, diffusion and BOLD imaging of methotrexate-exposed swine brain. *J Magn Reson Imaging* 2002;15(5):511–519. [PubMed: 11997891]
 14. Akiba T, Okeda R, Tajima T. Metabolites of 5-fluorouracil, alpha-fluoro-beta-alanine and fluoroacetic acid, directly injure myelinated fibers in tissue culture. *Acta Neuropathol* 1996;92(1):8–13. [PubMed: 8811119]

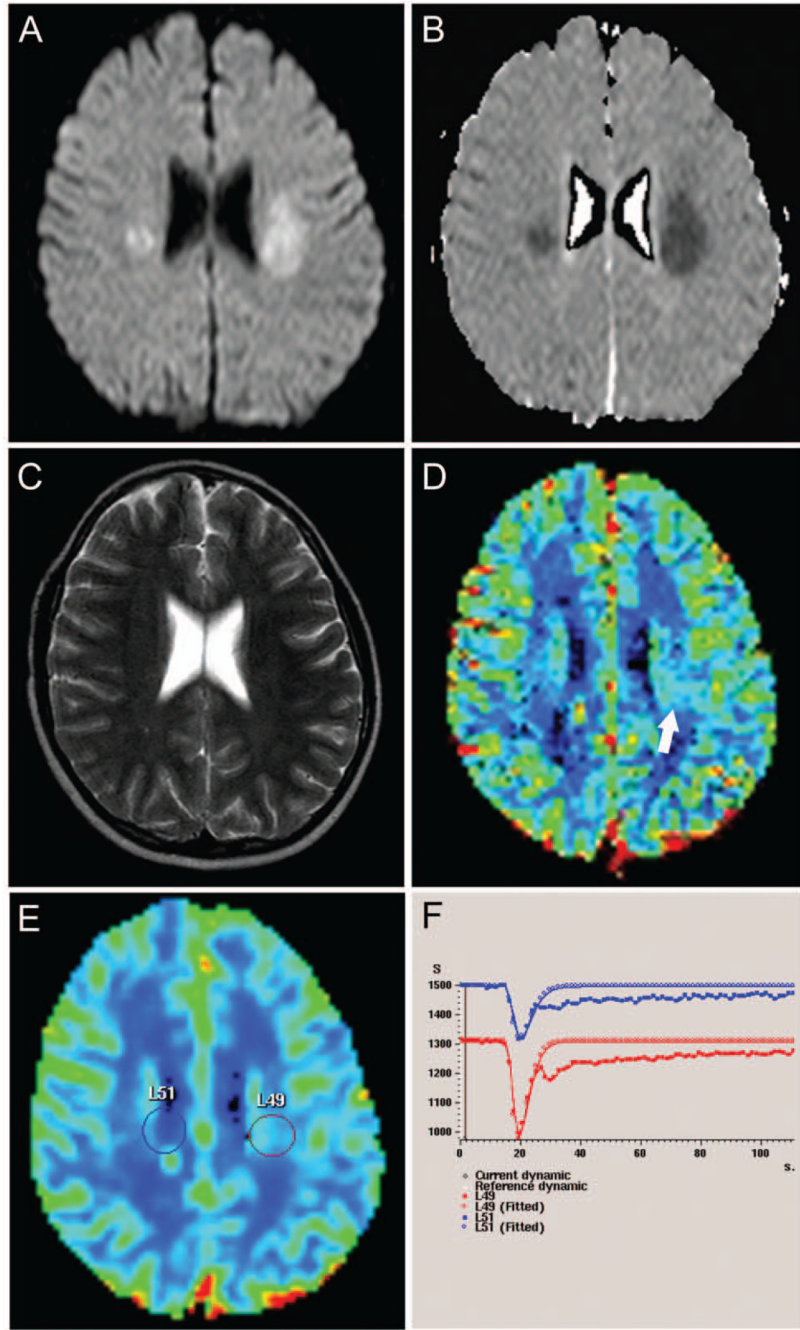


Figure 1. Axial diffusion-weighted image (A) and apparent diffusion coefficient map (B) show round foci of diffusion restriction in the corona radiata bilaterally. There is no visible abnormality on the T2-weighted image (C). Magnetic resonance perfusion index map (D) shows focal increased cerebral blood flow in the left-side lesion (arrow). No perfusion change was noted in the right-side lesion. The left-side centrum semiovale, marked by the circle as the lesion of interest (E), is depicted graphically by the red curve of the negative enhancement integral (F). The depth of the peak representing the left-side lesion (red curve, F) is significantly greater than the peak of the right-side area (blue curve, F), indicating an increase in cerebral blood volume and perfusion in the left-side lesion.