

Transient Global Amnesia

Concordant Hippocampal Abnormalities on Positron Emission Tomography and Magnetic Resonance Imaging

A 60-YEAR-OLD WOMAN was admitted 90 minutes after the onset of a typical transient global amnesia (TGA) episode, shortly after sexual intercourse. Anterograde amnesia was isolated and lasted less than 12 hours, with acute onset and progressive recovery. This patient had been referred 6 years before for a typical TGA, also postcoital. She regularly had moderate-intensity postcoital headaches.

Immediate fluorodeoxyglucose positron emission tomography (PET) scan (**Figure 1A**) revealed a pronounced left hippocampal hypometabolism (radiotracer was injected 2 hours after the onset of the symptoms). Magnetic resonance imaging (MRI) was performed 48 hours after TGA onset and showed a small nodular hyperintensity on diffusion-weighted imaging, with reduction of the apparent diffusion coefficient, in the left hippocampus (**Figure 2**). Fluid-attenuated inversion recovery and T2-weighted sequences were normal.

An ultrasonography study of the internal jugular veins, at rest and under Valsalva maneuver, was normal. A complete neuropsychological study 2 months after the TGA episode disclosed normal episodic memory performances. Brain MRI and fluorodeoxyglucose PET scans (Figure 1B) repeated 1 year later were completely normal.

COMMENT

To our knowledge, this is the first TGA case where acute hippocam-

pal dysfunction could be demonstrated both by metabolic and diffusion-weighted imaging. Along with stress or physical exertion, sexual intercourse is a common precipitant, possibly through venous congestion.¹ Several single-photon emission computed tomography studies disclose hypoperfusion in the medial temporal lobes, pointing to ischemic mechanisms.² Per critic PET scan studies are scarce; in the published reports,^{3,4} delay from amnesia onset varies between 3 and 10 hours, which may explain some discrepancies. Results suggesting cortical spreading depression were interpreted in keeping with the migraine hypothesis of TGA³; the second report⁴ discloses mild significant changes on the amygdala (right or left) associated with left posterior hippocampal hypometabolism in 2 other patients.

Numerous diffusion-weighted imaging MRI studies have repeatedly, but not constantly, demonstrated hippocampal abnormalities, detectable on a delayed window extending from 24 to 72 hours after the event and lasting up to 14 days, the CA-1 area seeming particularly vulnerable.¹ Taken together, the present PET and MRI data clearly suggest reversible unilateral hippocampal dysfunction, presumably ischemic, as the mechanism of TGA.

Victoria Gonzalez-Martinez, MD
Frédéric Comte, MD
Delphine de Verbizier, MD
Bertrand Carlander, MD

Author Affiliations: Departments of Neurology (Drs Gonzalez-Mar-

tinez and Carlander) and Nuclear Medicine (Drs Comte and de Verbizier), Montpellier University Hospital, Montpellier, France.

Correspondence: Dr Carlander, Department of Neurology, Montpellier University Hospital, 80, avenue Fliche, 34295 Montpellier, France (b-carlander@chu-montpellier.fr).

Author Contributions: *Study concept and design:* Gonzalez-Martinez and Carlander. *Acquisition of data:* Comte, de Verbizier, and Carlander. *Analysis and interpretation of data:* Gonzalez-Martinez, de Verbizier, and Carlander. *Drafting of the manuscript:* Gonzalez-Martinez and Carlander. *Critical revision of the manuscript for important intellectual content:* Gonzalez-Martinez, Comte, de Verbizier, and Carlander. *Administrative, technical, and material support:* Comte.

Financial Disclosure: None reported.

REFERENCES

1. Sander K, Sander D. New insights into transient global amnesia: recent imaging and clinical findings. *Lancet Neurol.* 2005;4(7):437-444.
2. Evans J, Wilson B, Wraight EP, Hodges JR. Neuropsychological and SPECT scan findings during and after transient global amnesia: evidence for the differential impairment of remote episodic memory. *J Neurol Neurosurg Psychiatry.* 1993;56(11):1227-1230.
3. Baron JC, Petit-Taboué MC, Le Doze F, Desgranges B, Ravenel N, Marchal G. Right frontal cortex hypometabolism in transient global amnesia: a PET study. *Brain.* 1994;117(pt 3):545-552.
4. Guillery B, Desgranges B, de la Sayette V, Landeau B, Eustache F, Baron JC. Transient global amnesia: concomitant episodic memory and positron emission tomography assessment in two additional patients. *Neurosci Lett.* 2002;325(1):62-66.

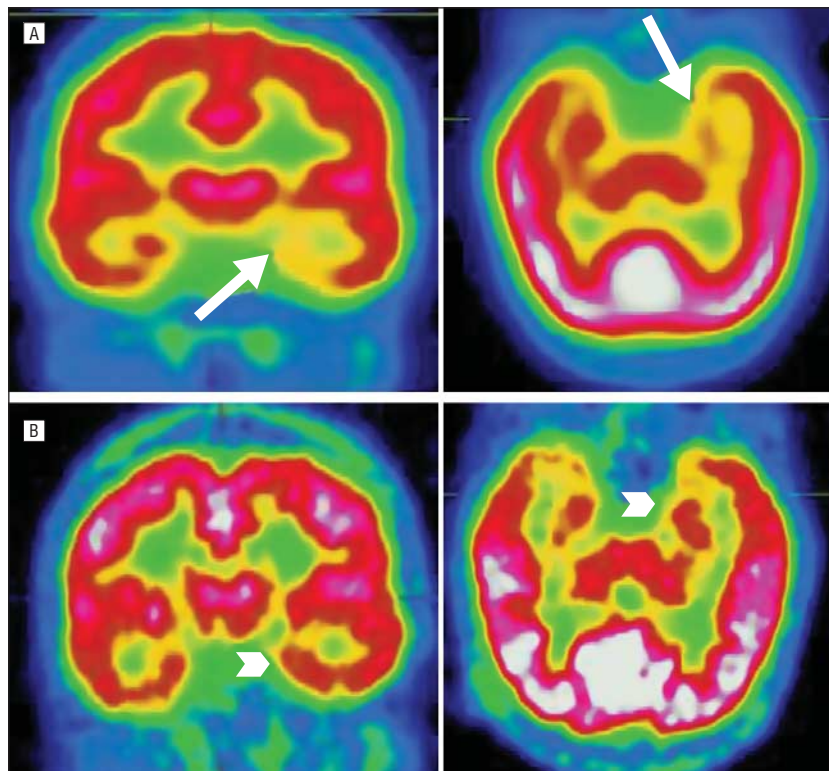


Figure 1. Positron emission tomography images. A, The axial and coronal planes, from left to right, obtained 2 hours after transient global amnesia onset, showing hypometabolism in the left hippocampal region (arrows). B, Control images obtained 1 year later (arrowheads, same location).

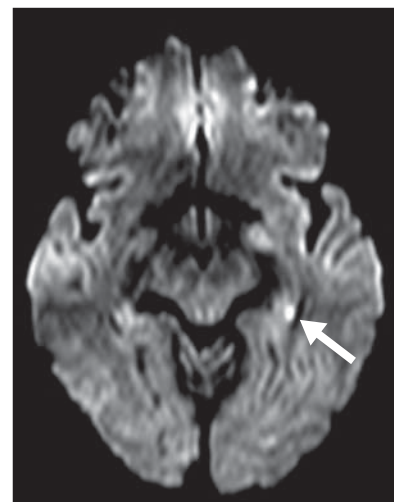


Figure 2. Diffusion-weighted magnetic resonance image, obtained 48 hours after onset, revealing a small diffusion restriction in the posterior left hippocampus (arrow).

Announcement

Topic Collections. *Archives* offers collections of articles in specific topic areas to make it easier for physicians to find the most recent publications in a field. These are available by subspecialty, study type, disease, or problem. In addition, you can sign up to receive a Collection E-Mail Alert when new articles on specific topics are published. Go to <http://archneur.ama-assn.org/collections> to see these collections of articles.