



Teaching cases

Occult gastric signet ring cell carcinoma presenting as spermatic cord and testicular metastases: “Krukenberg tumor” in a male patient

Inga-Marie Schaefer^a, Ulfert Sauer^b, Michael Liwocha^c, Heribert Schorn^d, Hagen Loertzer^e, László Füzesi^{a,*}

^a Department of Pathology, University Medicine, Robert-Koch-Straße 40, D-37099 Göttingen, Germany

^b Surgeon, Waldweg 1, D-37073 Göttingen, Germany

^c Department of Internal Medicine, Protestant Hospital Göttingen-Weende e.V., An der Lutter 24, D-37075 Göttingen, Germany

^d Urologist, Kornmarkt 9, D-37073, Göttingen, Germany

^e Department of Urology, University Medicine, Göttingen, Germany

ARTICLE INFO

Article history:

Received 22 August 2009

Received in revised form

20 January 2010

Accepted 15 February 2010

Keywords:

Signet ring cell carcinoma
Spermatic cord metastases
Krukenberg tumor
Cryptorchidism
Hypogonadism

ABSTRACT

Krukenberg tumor is a well-known ovarian metastasis, usually of gastric signet ring cell carcinoma in female patients. Although gastric carcinoma is more frequent in men, to our knowledge, only few cases of counterpart testicular metastases have been described as yet. We report a 64-year-old patient who complained of right testicular pain. Right-sided orchiectomy was performed, and metastatic signet ring cell carcinoma of spermatic cord and testis was diagnosed through histological examination and immunohistochemistry. The following stomach biopsy confirmed the primary signet ring cell carcinoma in the stomach. This extremely rare form of metastatic dissemination resembles the Krukenberg tumor of ovaries. Immunohistochemical staining plays an important role in the differential diagnosis of spermatic cord enlargement.

© 2010 Elsevier GmbH. All rights reserved.

Introduction

According to the classification of Lauren, gastric adenocarcinoma can be subtyped into two major groups. The intestinal type is mainly derived from precursor lesions along the lesser curvature of the stomach, showing exophytic growth with central ulceration and a glandular pattern on microscopic examination. The diffuse type, on the other hand, develops without any precursor and in different parts of the stomach, leading to an ill-defined thickening of mucosa and gastric wall. Histologically, the latter is frequently composed of signet ring cells, which typically lack cell cohesion and therefore expand in an infiltrative fashion. Metastatic dissemination of gastric signet ring cell carcinoma to the ovaries is referred to as Krukenberg tumor. Friedrich Ernst Krukenberg first described this phenomenon as “Fibrosarcoma ovarii mucocellulare carcinomatodes” in 1896. The counterpart in male organs derived from the sex cord is, however, a very rare observation [1,2,4,5,8–10,12–14].

We present here an unusual case of occult gastric signet ring cell carcinoma that metastasized to the right spermatic cord and

testicular tissue of a patient with hypogonadism and contralateral cryptorchidism. The differential diagnosis of diffuse spermatic cord thickening of unknown origin and the interesting association of male Krukenberg tumor with testicular atrophy and hydrocele will be discussed.

Clinical summary and pathological findings

A 64-year-old male patient underwent orchidopexy for left-sided cryptorchidism years before. In 2000, gonadal hormone level measurement revealed markedly elevated basal FSH of 30 IU/L (reference range 2–9 IU/L), decreased levels of total testosterone of 1.84 ng/mL (reference range 2.8–8.8 ng/mL), and a decreased androgen index of 35 (reference range > 45), indicating hypergonadotropic hypogonadism. Both testes were atrophic, the left measuring 2.8 mL and the right 6.5 mL, respectively. In 2001, excisions from the right vocal cord revealed an invasive, moderately differentiated squamous cell carcinoma (pT1), which was locally excised and cured. Furthermore, the patient suffered from a depression and anxiety disorder, as well as coronary artery disease, arterial hypertension, cerebrovascular insufficiency, diabetes mellitus type II, obesity, steatosis hepatis, cholecystolithiasis, and prostatic hyperplasia with a prostatic adenoma.

In April 2008, the patient complained of right lower quadrant abdominal pain, constipation, and a painful mass in right groin and

Abbreviations: PAS, periodic acid Schiff; FSH, follicle stimulating hormone; CEA, carcinoembryonic antigen; AFP, alpha-fetoprotein; PLAP, placenta-like alkaline phosphatase.

* Corresponding author. Tel.: +49 551 396858, fax: +49 551 398627.

E-mail address: fuezesi@med.uni-goettingen.de (L. Füzesi).

scrotum. Colonoscopy and biopsy revealed non-specific colitis. The right spermatic cord, epididymis, and testis, which were retracted almost to the external inguinal ring, exhibited a diffusely indurated enlargement. Ultrasound imaging showed a 3 × 1.3 cm hydrocele testis and a 0.5 cm circumscribed cystic lesion within the testicle parenchyma. In May 2008, right-sided inguinal exploration with resection of the spermatic cord and orchiectomy was performed to clarify the nature of the painful mass.

The specimen from right-sided orchiectomy included testis and epididymis (3.5 × 3 × 2.5 cm) attached spermatic cord (8.5 cm long) and part of tunica vaginalis testis. The spermatic cord

adjacent to the testis appeared to be enlarged in diameter (2 cm) compared to the distant end (1.5 cm). Spermatic cord and testis were of hard consistency. Hydrocele testis and a 0.5 cm spermatocele within the rete testis were also present. Histomorphologically, paratesticular tissue (i.e., rete testis, epididymis, efferent ductules, spermatic duct, and testicular tunics) and testis showed diffuse infiltration by single or clustered large round cells with pale eosinophilic cytoplasm (Fig. 1A). The infiltration mainly involved lymphatics, fascial spaces along the spermatic duct, and tissues between testis and epididymis. Intracellular PAS-positive mucin showed signet ring cells, with the nucleus displaced to the

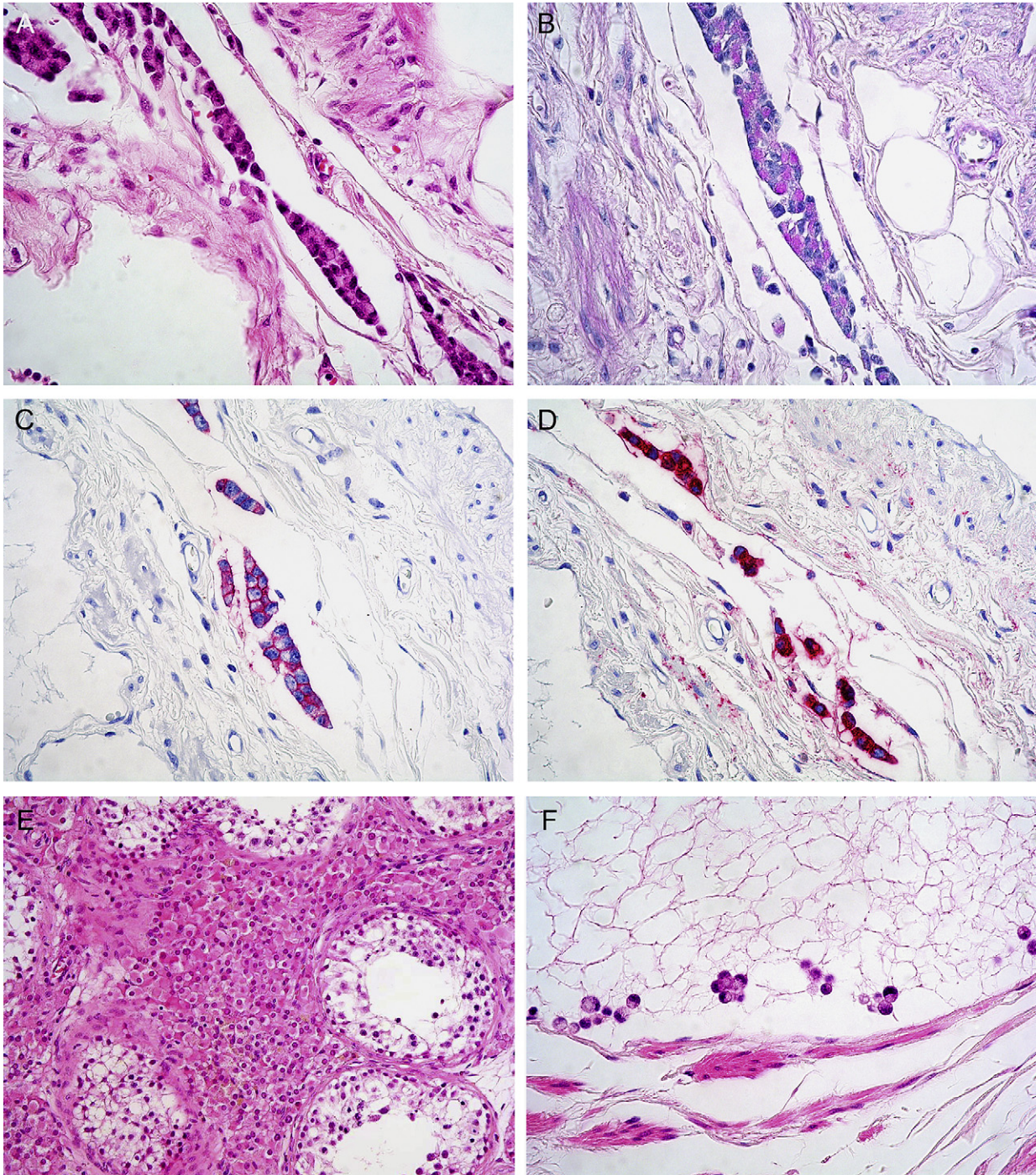


Fig. 1. Photomicrographs showing infiltration of the paratesticular tissue by metastatic signet ring cell carcinoma: HE staining (A), intracytoplasmic PAS-positivity (B) and immunohistochemical reaction of tumor cells to BerEp4 (C) and CEA (D) ($\times 40$). Testicular atrophy of the right testis: Leydig cell hyperplasia and seminiferous tubules with decreased spermatogenesis (E) (HE, $\times 20$). Infiltration of testicular tissue by single signet ring cells (F) (HE, $\times 40$).

cell membrane (Fig. 1B). Immunohistochemically, the tumor cells were found to express pankeratin, BerEp4, and CEA (Fig. 1C, D). Nuclear Ki67 positivity of 30–50% indicated high proliferative activity. Markers for mesothelial differentiation (calretinin and D2-40) and primary germinal cell tumors (AFP, PLAP, Oct3/4 and D2-40) were negative. On the basis of tumor cell morphology, positive cytoplasmic PAS-stain, and expression of epithelial markers, the diagnosis of an occult metastatic signet ring cell carcinoma most likely located in the stomach was made. Besides the metastatic infiltration of the testicle, reduced spermatogenesis with tubular hyalinization and extensive Leydig cell hyperplasia were also observed (Fig. 1E), indicating hypogonadism with testicular atrophy.

Gastroscopy samples taken from the corpus revealed diffuse infiltration by a signet ring cell carcinoma and abundant extracellular mucinous precipitates. Helicobacter pylori-associated chronic erosive gastritis was present.

When the diagnosis of metastatic gastric cancer was established in June 2008, the patient developed malignant ascites, pleural effusion, and peritoneal carcinosis. He received palliative chemotherapy with paclitaxel, leucovorin, and 5-FU (PLF regimen) for two cycles, followed by seven cycles of epirubicin, oxaliplatin, and capecitabine (EOX regimen). The patient died of respiratory failure in April 2009.

Discussion

Sex cord, such as spermatic duct, epididymides or testes, with occult gastric carcinoma metastasis has been reported recently [1,2,4,5,8–10,12–14], with only five cases in Europe [1,2,9,10,12]. Characteristic for these cases are signet ring cell [4,8,10,12], poor [1,14] or tubular [5] differentiation. Complaints of unilateral testicular swelling with or without pain are frequent. In three of seven cases, association with hydrocele was previously reported [5,12,14]. Patient age at the onset of symptoms ranged from 21 to 68 years [1,4]. Although Wai et al. [14] proposed bilateral involvement of male Krukenberg tumor in 15% of cases, the case reports mentioned above all described unilateral involvement, with five cases on the left and three cases on the right side. Except for one case of mucinous adenocarcinoma of the coecum [4], the primary origin was typically located in the stomach [1,5,8,10,12,14].

Because they lack cell cohesion, signet ring cells are able to metastasize as small clusters or single cells (Fig. 1F), sometimes even to extra-intestinal sites, such as internal auditory meatus or calf muscle [14]. The ovaries are mostly infiltrated by retrograde spread along lymphatics following the course of the ovarian artery [3,11]. In women, Krukenberg tumor accounts for 1–2% of all ovarian tumors, and patients typically present in their 5th decade with complaints of abdominal pain, distension, virilization, ascites, or Pseudo-Meigs syndrome [15]. Bilateral involvement is observed in 80% of cases [15]. Although the most common primary site of origin is the stomach, accounting for 70–76% of female Krukenberg tumors, carcinomas arising in colon, appendix, breast, gallbladder, ampulla of Vater, and urinary tract may also spread to the ovary [15,16]. The designation “Krukenberg tumor” should be reserved for tumors consisting of more than 10% signet ring cells, although the term is sometimes misleadingly used to describe any metastatic ovarian tumor [16].

Cavitary dissemination seems unlikely, since peritoneal carcinosis is not necessarily observed in female Krukenberg tumor. The mechanism of tumor dissemination to testes has been widely debated. Possible routes may be blood vessels and lymphatics along the testicular artery [1,4,10,14], following the structure of the former fetal caudal gonadal ligament, similar to the Krukenberg tumor in women, and retrograde spread through the lumen of the

spermatic duct [10,12]. In the case presented here, distinct lymphangiosis carcinomatosa was observed, suggesting a retrograde lymphatic tumor spread. Furthermore, a patent processus vaginalis testis might subserve metastatic spread along the aforementioned structures [1,12,14]. In children, testicular maldescent may lead to an insufficient obliteration of the peritoneal gap in the abdominal inguinal ring and generate a temporarily patent processus vaginalis testis, whereas in adulthood, regressive obliteration of the structures makes tumor spread through a patent processus vaginalis unlikely. Alvarez Perez et al. [2] described a rare case of colonic carcinoma with metastases to cryptorchid testis. In our case, only the non-cryptorchid right testis was affected, possibly because previous operative obliteration of the left inguinal canal prevented metastatic spread to this side. Association of Krukenberg tumor with either inborn or acquired hydrocele of the spermatic cord, or hydrocele communicans with fluid in the serous cavum of testis due to a patent processus vaginalis, has been described in three cases [5,12,14]. Whether these findings were pre-existing or developed secondary to tumor infiltration remains unclear. If pre-existing, they may indicate an open connection to the abdominal cavity. If secondary to tumor infiltration, retrograde lymphatic spread to the testis seems likely, as lymphatic drainage could be impaired and hydrocele may develop from congestion. Interestingly, Hunter et al., [4] London et al., [8] and Qazi et al. [12] noted testicular atrophy in their orchiectomy specimens, leading to the hypothesis that cryptorchidism and/or hypogonadism may predispose men to develop Krukenberg tumors. Whether high levels of FSH and low levels of testosterone somehow facilitate the spread of tumor cells through the inguinal canal, through association with indirect inguinal hernia, hormone receptor dysfunctions, or other structural changes in this region, requires further investigation.

Competing interests

The authors declare that they have no competing interests.

References

- [1] M. Alois, P. Valentina, G. Andreas, The “Krukenberg” tumor in male, *Arch. Esp. Urol.* 58 (9) (2005) 971–973.
- [2] J.A. Alvarez Perez, V.L. Vazquez, J.J. Gonzalez Gonzalez, M.F. Fresno Forcelledo, [Metastasis of carcinoma of the colon to cryptorchid testis. An infrequent finding], *Rev. Esp. Enferm Apar. Dig.* 75 (2) (1989) 213–214.
- [3] T.C. Chang, C.C. Changchien, C.W. Tseng, C.H. Lai, C.J. Tseng, S.E. Lin, et al., Retrograde lymphatic spread: a likely route for metastatic ovarian cancers of gastrointestinal origin, *Gynecol. Oncol.* 66 (3) (1997) 372–377.
- [4] D.T. Hunter Jr., J.B. Hutcheson, Krukenberg tumor of the testicle, report of a second case, *J. Urol.* 81 (2) (1959) 305–308.
- [5] Y. Kageyama, S. Kawakami, G. Li, K. Kihara, H. Oshima, K. Teramoto, [Metastatic tumor of spermatic cord and tunica vaginalis testis from gastric cancer: a case report], *Hinyokika Kiyo* 43 (6) (1997) 429–431.
- [8] M.Z. London, S.N. Grossman, Secondary testicular tumor resembling Krukenberg tumor, a case report, *J. Urol.* 62 (5) (1949) 713–716.
- [9] G.H. Muir, C. Fisher, Gastric carcinoma presenting with testicular metastasis, *Br. J. Urol.* 73 (6) (1994) 713–714.
- [10] O.L. Ozdal, Y.K. Yakupoglu, A. Cicek, O. Erdem, L. Memis, A. Memis, Epididymal metastasis from gastric signet ring cell adenocarcinoma, *Can. J. Urol.* 9 (2) (2002) 1498–1499.
- [11] V. Praz, P. Nordback, A. Billing, M. Merlini, Krukenberg’s tumor, three years after a colic carcinoma, *Swiss. Surg.* 8 (5) (2002) 237–239.
- [12] H.A. Qazi, R. Manikandan, C.S. Foster, M.V. Fordham, Testicular metastasis from gastric carcinoma, *Urology* 68 (4) (2006) 890–898.
- [13] M.R. Shetty, Krukenberg tumor of testis, *Urology* 33 (4) (1989) 351.
- [14] H.P. Wai, T.K. Yau, W.M. Sze, M.W. Yeung, F. Hioe, A.W. Lee, Metastatic tumour of the tunica vaginalis testis from carcinoma of the stomach, *Int. J. Clin. Pract.* 54 (2000) 685–686.
- [15] S.V. Sakpal, N. Babel, R. Pulinthanathu, T.R. Denehy, R.S. Chamberlain, Krukenberg tumor: metastasis of Meckel’s diverticular adenocarcinoma to ovaries, *J. Nippon Med. Sch.* 76 (2009) 96–102.
- [16] R.H. Young, From krukenberg to today: the ever present problems posed by metastatic tumors in the ovary: part I. Historical perspective, general principles, mucinous tumors including the krukenberg tumor, *Adv. Anat. Pathol.* 13 (2006) 205–227.