

Cerebral Vasculitis Associated With Amyloid Angiopathy

—Case Report—

Masaki MORISHIGE, Tatsuya ABE, Tohru KAMIDA, Takamitsu HIKAWA, Minoru FUJIKI, Hidenori KOBAYASHI, Toshiro OKAZAKI*, Noriyuki KIMURA*, Toshihide KUMAMOTO*, Akira YAMADA**, and Yoshihisa KAWANO**

Departments of Neurosurgery and *Neurology, Oita University School of Medicine, Yufu, Oita;

**Kawano Neurosurgical Hospital, Oita

Abstract

A 78-year-old female presented with coexisting primary angiitis of the central nervous system (CNS) and cerebral amyloid angiopathy (CAA) manifesting as motor aphasia caused by a left frontal lobe lesion. Magnetic resonance imaging revealed an enhanced lesion with moderate surrounding edema. Technetium-99m propylene amine oxime single-photon emission computed tomography showed decreased cerebral blood flow (CBF) in the lesions, and high serum soluble-interleukin-2 level was detected, suggesting intravascular lymphoma of the CNS. Cerebral biopsy revealed CAA with secondary florid vasculitic appearance. The CBF and neurological symptoms, such as aphasia and dementia, recovered following steroid treatment. Cerebral vasculitis associated with CAA should be included in the differential diagnosis of an unusually enhanced lesion, because timely diagnosis and aggressive treatment are critical to successful recovery in such elderly patients.

Key words: brain tumor, vasculitis, cerebral amyloid angiopathy

Introduction

Cerebral amyloid angiopathy (CAA) occasionally coexists with cerebral vasculitis, including granulomatous angiitis (giant cell arteritis) of the brain. Such angiitis may cause amyloid deposition or vascular amyloid deposition may secondarily induce granulomatous (giant cell) reaction.¹¹⁾ Primary angiitis of the central nervous system (CNS) is a serious type of inflammatory angiitis that only affects the CNS vessels in the absence of an overt systemic inflammatory process.¹⁾ Early aggressive immunosuppressive therapy substantially improves the outcome but may also result in significant complications, so cerebral biopsy is indicated to rule out other conditions that mimic or cause CNS vasculitis.³⁾ We treated a patient with CAA mimicking a brain tumor.

Case Report

A 78-year-old female was admitted due to symptoms of motor aphasia and dementia. Magnetic resonance (MR) imaging demonstrated large confluent hyperintense areas predominantly in the white matter on T₂-weighted or fluid-attenuated inversion recovery images (Fig. 1A). T₁-weighted MR imaging with contrast medium showed decreased intensity with mild parenchymal enhancement in the left frontal lobe (Fig. 1B–D), consistent with either

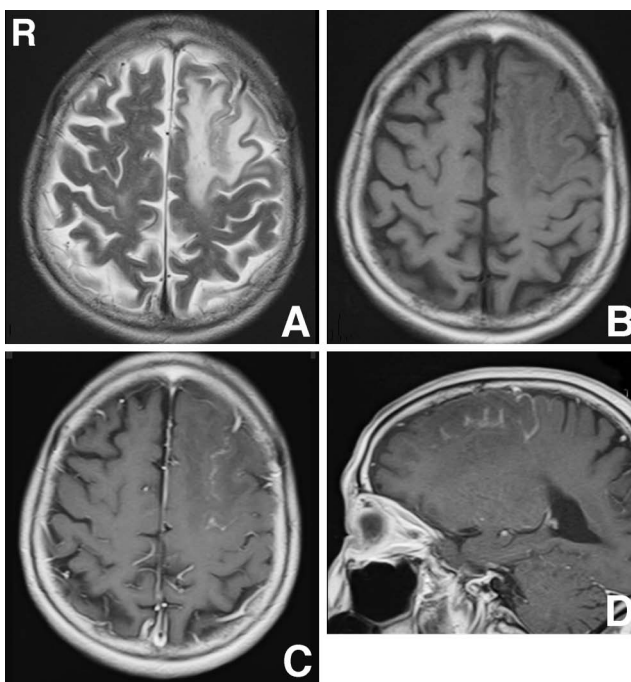


Fig. 1 (A) Preoperative T₂-weighted magnetic resonance (MR) image demonstrating a high intensity lesion in the left frontal lobe. (B) Preoperative T₁-weighted MR image demonstrating a low intensity lesion. (C, D) T₁-weighted MR images with gadolinium showing mildly enhanced lesions.

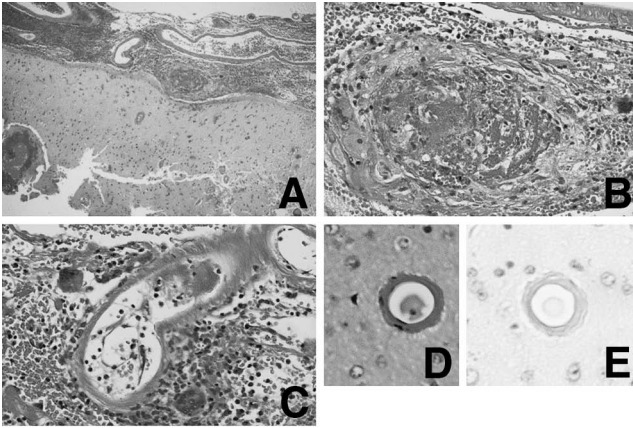


Fig. 2 Photomicrographs showing leptomeningeal infiltration of lymphocytes (A: hematoxylin and eosin [HE] stain, $\times 40$), angitis with transmural inflammation and fibrinoid necrosis (B: HE stain, $\times 400$), angitis with large multinucleated giant cells (C: HE stain, $\times 400$), thickened blood vessel (D: HE stain, $\times 400$), and presence of amyloid angiopathy (E: Dylon stain, $\times 400$).

tumor enhancement or infection/inflammation (encephalitis). Cerebral angiography revealed neither eccentric narrowing of medium-sized vessels nor concentric narrowing, which are characteristic findings of vasculitis. Technetium-99m propylene amine oxime single photon emission computed tomography showed decreased cerebral blood flow (CBF) in the lesions. However, gallium scintigraphy revealed weak accumulation.

Peripheral white blood cell count was normal, but serum C-reactive protein (0.81 mg/dl) and soluble-interleukin-2 receptor (790 U/ml) levels were slightly increased. Cerebrospinal fluid analysis showed no abnormalities and cultures and cytology findings demonstrated negative findings.

The preoperative differential diagnosis included lymphoma (intravascular lymphoma), leukoencephalopathy (progressive multifocal leukoencephalopathy, viral encephalitis, autoimmune disease, etc.), acute disseminated encephalomyelitis, and vasculopathy/vasculitis.

Left frontal osteoplastic craniotomy under general anesthesia and cerebral biopsy (meninges, cortex, and white matter) were performed. The histological diagnosis was primary angiitis of the CNS, or granulomatous, giant cell, or isolated angiitis (Fig. 2A–C). Vessels showing primary angiitis of the CNS were concomitantly affected by amyloid angiopathy, characterized as markedly thickened eosinophilic walls with round profiles (Fig. 2D). Dylon staining confirmed amyloid deposition in the walls of most vessels (Fig. 2E), including all of the inflamed vessels, in the leptomeninges, and the cortical gray matter. In addition, some vessels showed fibrinoid necrosis with mild lymphocytic and histiocytic infiltrates.

Prednisone (50 mg/day) was administered. The patient's dementia gradually improved and she was able to speak again. The CBF abnormalities also resolved. She continued to take 5 mg oral prednisone daily. Substantial

reversal of the MR imaging changes in the white matter was observed. The patient has been followed up for more than 2 years and no signs of relapse have been observed.

Discussion

Primary angiitis of the CNS is defined as vasculitis restricted to the small leptomeningeal and parenchymal arteries and veins without apparent systemic involvement. In our case, laboratory investigations demonstrated normal findings for autoantibodies. On the other hand, CAA is a disease of the elderly, characterized by the deposition of amyloids in the cortical and leptomeningeal vessels. The association of CAA with only vascular inflammatory changes ('vasculitis') is thought to be extremely rare. However, the coexistence of CAA and granulomatous angiitis has been reported in several cases and is well recognized. The amyloid proteins are reported to be β -protein and AL (amyloid protein derived from immunoglobulin light chains). Clinical and laboratory evidence of cerebral angiitis is present in some patients,¹¹⁾ but not in others, and some patients present with radiological evidence of mass lesions.^{2,5,7,9–11)} Granulomatous angiitis of the CNS is defined histologically by granulomatous inflammation of the cerebral blood vessels. Different conditions such as infection and altered immune state may induce granulomatous angiitis, suggesting that granulomatous angiitis is not a unique disease but represents a nonspecific immune reaction to injury to the blood vessels induced by amyloid deposition.⁴⁾

Primary angiitis of the CNS can present as a number of clinical patterns, but the three dominant features are usually encephalopathy, headache, and focal neurological signs to various degrees. The pattern of clinical presentation in the CAA and primary angiitis of the CNS groups is similar. The most common clinical features in cerebral vasculitis associated with CAA are changes in the mental status (confusion states, poor memory/concentration or impaired conscious level), often leading to frank dementia, headache, hallucinations, and seizures.⁸⁾

Diagnostic imaging can be difficult in such patients. Cerebral vasculitis associated with CAA and vascular inflammation often appears as prominent white matter changes on computed tomography and MR imaging. The white matter changes result from a combination of vascular compromise ischemia, hemorrhage, edema, and atrophy. Angiography has low sensitivity and specificity, with an enormous number of inflammatory, metabolic, malignant, or other vasculopathies mimicking CNS vasculitis. In our case, preoperative imaging showed the typical cerebral vasculitis associated with CAA. However, the present diagnosis could not have been established without biopsy. Therefore, cerebral biopsy with histological confirmation remains the 'gold standard' for an accurate diagnosis.¹¹⁾

Untreated primary angiitis of the CNS inevitably progresses to death, often within a year of onset. However, the outcome for patients with cerebral vasculitis associated with CAA varies considerably. The administration of high dose corticosteroids is the mainstay treatment for

this disease. Cyclophosphamide is also given as an immunosuppressive therapy. The response rate to medical therapy in cerebral vasculitis associated with CAA is 60%, with spontaneous recovery in only 5%.³⁾ Autopsy evidence suggests that immunosuppressive treatment decreases the amyloid burden.⁶⁾ On the other hand, sustained or dramatic improvements are rarely observed.⁸⁾ Among six patients with histology-positive primary angiitis of the CNS, two died, one suffered severe disability, two had moderate disability, and one had minor disability. All had received steroid and/or further immunosuppression therapy with no clear pattern of response to the treatment. However, in the present patient, high dose prednisone treatment (50 mg/day), as the initial induction therapy, promoted the healing of the progressive vessel inflammation, and low dose prednisone (5 mg/day) also effectively prevented relapse for more than 2 years. The preoperative differential diagnosis included intravascular lymphoma. Therefore, biopsy was promptly performed. Cerebral vasculitis associated with CAA should be included in the differential diagnosis in elderly patients, because timely histological diagnosis and aggressive treatment are critical to the successful recovery of such patients.

Acknowledgments

We thank Drs. Keisuke Ishii and Takeshi Kubo (Oita University School of Medicine) for valuable discussions.

References

- 1) Abe T, Maruyama T, Nagai Y, Kamida T, Wakabayashi Y, Ishii K, Fujiki M, Kobayashi H: Severe postoperative vasculitis of the central nervous system in a child with arteriovenous malformation: case report. *Surg Neurol* 68: 317–321, 2007
- 2) Briceno CE, Resch L, Bernstein M: Cerebral amyloid angiopathy presenting as a mass lesion. *Stroke* 18: 234–239, 1987
- 3) Fountain NB, Eberhard DA: Primary angiitis of the central nervous system associated with cerebral amyloid angiopathy: report of two cases and review of the literature. *Neurology* 46: 190–197, 1996
- 4) Gray F, Dubas F, Rouillet E, Escourolle R: Leukoencephalopathy in diffuse hemorrhagic cerebral amyloid angiopathy. *Ann Neurol* 18: 54–59, 1985
- 5) Le Coz P, Mikol J, Ferrand J, Woimant F, Masters C, Beyreuther K, Hagenau M, Cophignon J, Pepin B: Granulomatous angiitis and cerebral amyloid angiopathy presenting as a mass lesion. *Neuropathol Appl Neurobiol* 17: 149–155, 1991
- 6) Mandybur TI, Balko G: Cerebral amyloid angiopathy with granulomatous angiitis ameliorated by steroid-cytosin treatment. *Clin Neuropharmacol* 15: 241–247, 1992
- 7) Murphy MN, Sima AA: Cerebral amyloid angiopathy associated with giant cell arteritis: a case report. *Stroke* 16: 514–517, 1985
- 8) Scolding NJ, Joseph F, Kirby PA, Mazanti I, Gray F, Mikol J, Ellison D, Hilton DA, Williams TL, MacKenzie JM, Xuereb JH, Love S: Abeta-related angiitis: primary angiitis of the central nervous system associated with cerebral amyloid angiopathy. *Brain* 128: 500–515, 2005
- 9) Tamargo RJ, Connolly ES Jr, McKhann GM, Khandji A, Chang Y, Libien J, Adams D: Clinicopathological review: primary angiitis of the central nervous system in association with cerebral amyloid angiopathy. *Neurosurgery* 53: 136–143, 2003
- 10) Wong SH, Robbins PD, Knuckey NW, Kermode AG: Cerebral amyloid angiopathy presenting with vasculitic pathology. *J Clin Neurosci* 13: 291–294, 2006
- 11) Yamada M, Itoh Y, Shintaku M, Kawamura J, Jensson O, Thorsteinsson L, Suematsu N, Matsushita M, Otomo E: Immune reactions associated with cerebral amyloid angiopathy. *Stroke* 27: 1155–1162, 1996

Address reprint requests to: Tatsuya Abe, M.D., Department of Neurosurgery, Oita University School of Medicine, 1-1 Idaigooka, Hasama-machi, Yufu, Oita 879-5593, Japan.
e-mail: abet@med.oita-u.ac.jp