

---

# Cortical blindness and residual vision: Is the "second" visual system in humans capable of more than rudimentary visual perception?

G.G. Celesia, MD; D. Bushnell, MD; S. Cone Toleikis, MS; and M.G. Brigell, PhD

---

**Article abstract**—We studied 12 patients with static cortical blindness to evaluate residual vision after destruction of area 17 and to assess the visual capacity of the subcortical "second" visual system in humans. In each case, the cause was bilateral infarction of the occipital lobes. Five patients had total blindness, and four had residual rudimentary vision (RRV), characterized by homonymous areas of light perception in the peripheral field and ability to detect moving objects. Only three patients had the ability to read; two of these had spared macular vision, and the other had spared left homonymous hemimaculae and spared temporal crescent. Neuroimaging and visual evoked potentials (VEPs) correlated with the extent of the visual dysfunction. Total destruction of area 17 bilaterally was associated with total permanent visual loss. The larger the amount of spared visual cortex, the better the vision. Positron emission tomography (PET) or single photon emission computed tomography (SPECT) demonstrated retained metabolic activity in islands of preserved area 17 in patients with some residual vision. VEPs were present in totally blind individuals. We conclude that, in humans, useful visual function is preserved only when a critical amount of area 17 is spared. The subcortical second system may participate in the generation of VEPs, but is incapable of conscious visual perception.

NEUROLOGY 1991;41:862-869

---

Residual visual perception is demonstrable in sub-human primates after bilateral ablation of area 17.<sup>1-4</sup> Bilateral ablation of area 17 with sparing of parastriate cortices (areas 18 and 19) causes loss of visual recognition of stationary objects with preservation of visuo-spatial orientation and awareness of a moving object in the peripheral fields. There is also residual visual capacities following occipital lobe lesions in humans. Patients with unilateral lesions of the geniculostriate pathways have residual vision in their hemianopic field.<sup>5-9</sup> Using a forced-choice procedure, patients with homonymous hemianopia were able to localize visual targets that they could not see. This retained ability to perceive moving objects in the blind hemifield constitutes the Riddoch's phenomenon, whereas any form of rudimentary residual vision in the blind hemifield constitutes "blindsight." Perenin et al<sup>10</sup> described the reappearance of some visual perception (detection of moving stimuli and bright flashes) in a man 7 months after bilateral dense ischemic lesions of area 17. These authors concluded that residual vision was related to the extra-geniculostriate pathways, the so-called "second" visual system. The concept of two visual systems—the classic retino-geniculostriate system and the "second" retino-collicular-pulvinar-extrastriate visual system—has undergone considerable refinements in the last 20 years.<sup>11-16</sup> Although the importance of the second system in visuomotor functions is generally ac-

cepted, the role of the system in visual perception remains uncertain.<sup>12-17</sup> To assess the possible role of the extrastriate visual system in humans, we have studied 12 patients with bilateral occipital lobe ischemic lesions.

**Methods.** Twelve patients with static cortical blindness from the clinical practice of the senior author (G.G.C.) were examined between 1978 and 1989. Every patient had a detailed neuro-ophthalmologic examination including ophthalmoscopic examination, pupil evaluation, and whenever possible, visual acuity and pseudoisochromatic plates. To ascertain residual vision, patients were tested in a partially darkened room and asked to localize a bright light and to distinguish light onset and offset. Moving pen lights and drifting bars presented on a TV screen were used to test the ability to detect motion or presence or absence of a response. The bars subtended 2 and 4 degrees of arc. Optokinetic nystagmus was tested with a rotating hand-held drum with black and white stripes subtending approximately 1 degree of arc. During testing, all other sensory clues were eliminated. White noise was used to mask the click produced by the light flash.

Every test was repeated at least five times and the responses recorded. Stimulus identification or localization at a better than chance level was defined as evidence of intact function. Goldmann perimetry was attempted in patients who showed any form of residual vision. The ability to identify geometric forms, objects, and letters of the alphabet by touch was tested in each patient.

Visual evoked potentials (VEPs) were tested in every pa-

---

From the Department of Neurology, Loyola University of Chicago Stritch School of Medicine, and Hines Veterans Administration, Chicago, IL.

Supported by a grant from the Veterans Administration.

Received July 3, 1990. Accepted for publication in final form November 6, 1990.

Address correspondence and reprint requests to Dr. Gastone G. Celesia, Department of Neurology, Loyola University of Chicago Stritch School of Medicine, 2160 S. First Avenue, Maywood, IL 60153.

tient capable of maintaining the gaze directed toward the visual stimulus. Pattern stimuli consisted of checks subtending 15', 30', and 60' of arc, reversing at a frequency of 1 Hz. The mean luminance was 115 cd/m<sup>2</sup> and subtended 22 degrees. Flash stimulation was carried out with a Ganzfeld stimulator using white flashes. The critical frequency of photic driving (CFPD) was determined with the technique previously described.<sup>18,19</sup> Electroretinograms (ERGs) were obtained in selected patients. Every patient had a CT and/or MRI to ascertain the nature and location of the lesion. Positron emission tomography (PET) or single photon emission computed tomography (SPECT) was performed on selected patients. Selection of patients was based exclusively on the availability of the test and the patient's cooperation. Regional cerebral blood flow (rCBF) was studied with (<sup>18</sup>F)fluoromethane, and regional cerebral glucose metabolic rate (LCMRGlc) was measured with (<sup>18</sup>F)2-fluoro-2-deoxyglucose (<sup>18</sup>FDG); images were obtained using an ECAT scanner. The details of the technique were previously described.<sup>20,21</sup>

N-isopropyl-P-iodo-amphetamine-iodine-123 (IMP) was used to study cerebral perfusion with SPECT using a truncated head rotating gamma system.<sup>22,23</sup> In addition, two patients had repeated SPECT imaging in conjunction with flash stimulation. The computation based method of von Schulthess et al<sup>22</sup> was used to determine the percent increase in IMP concentration in the occipital region during flash stimulation. The criteria for inclusion in the study were as follows: (1) The patient had to meet the definition of cortical blindness or of bilateral hemianopia. (2) The lesion had to be ischemic in nature and verified by CT or MRI. (3) The vision loss had to be stable and therefore not in the acute stage of a stroke. The event causing the blindness had to have occurred at least 10 days before the visual examination. (4) The patient was cooperative and able to follow instructions. The exclusion criteria were as follows: (1) opacities of the ocular media, (2) history of retinopathy or amblyopia, (3) history of systemic or brain neoplasm, (4) head trauma, (5) aphasia or dementia, and (6) transient blindness.

**Definitions.** Cortical blindness was defined as a loss of vision due to verified bilateral occipital lobe lesions and meeting the following features (modified from Marquis<sup>24</sup>): (1) loss of all visual sensations including all, or mostly all, appreciation of light and dark, (2) loss of lid closure to threatening gestures, (3) retention of pupillary reflexes to light and near, (4) normal retinas to fundoscopic examination, and (5) retention of full extraocular movements.

**Bilateral hemianopia** was defined as a loss of vision involving nasal and temporal hemifields of both eyes with sparing of all or part of the central vision due to a verified lesion of both occipital lobes.

**Residual rudimentary vision (RRV)** was defined as the ability to perceive changes in illumination and the ability to localize moving targets. The subject, however, is unable to identify the nature of the target and cannot recognize objects or forms.

**Results.** Twelve patients met the criteria outlined in Methods. Their ages varied from 58 to 81 years, with a mean of 67.6 ± 7.9 years. There were seven men and five women. The most common etiology in this series was ischemic cerebral infarct (seven cases or 58%), cardiac surgery (three or 25%), embolism from cardiac source (one or 8%), cardiac arrest (one or 8%).

**Visual performance.** Nine patients had cortical blindness (table). Patients with cortical blindness were either totally blind or showed some preserved rudimentary vision. Blindness was complete with inability to

detect light or any other visual stimulus in five patients, whereas in four patients, some rudimentary vision persisted. These latter patients were able to detect presence or absence of light in a small homonymous area of their peripheral field, whereas detection of movement and ability to detect direction of movement was present only in two patients and was limited to the preserved area of vision. When the patient maintained fixation during testing, no movement was detected in the blind field. Testing was often very difficult due to poor fixation. Six of the nine patients with cortical blindness had denial of their deficit (Anton's syndrome<sup>25</sup>). The denial was complete in three patients and associated with confabulation (description of objects and individuals). The other three patients had only partial awareness of the deficit and, when asked to identify target objects visually, often confabulated or complained that poor lighting made identification difficult. The denial was transient, and every patient recognized, 3 to 8 weeks after the original event causing the blindness, that he or she had some visual impairment, although some denial and some confabulation persisted. One patient with total blindness was reexamined 2 years after the initial evaluation. She has no evidence of improved vision. The patient depended exclusively on extravisual cues to cope with the environment. She acknowledged that she was blind, but stated that she was able to detect large objects and the presence of light; however, careful testing with elimination of auditory cues revealed no residual vision.

RRV did not help any of the patients in dealing with their visual deficit, nor did it affect the patients awareness of the deficit. Patients with or without RRV were similarly visually handicapped. An island of preserved rudimentary vision was insufficient to alert the patient to changes in the environment. Although these patients were able to detect the presence of bright light and the absence of light in a testing situation, they were unable to distinguish light versus dark spontaneously in a routine setting. Optokinetic nystagmus was absent in all five patients with total blindness. Optokinetic nystagmus was preserved in two patients with residual vision and was absent in the remaining two patients. Bilateral hemianopia was present in three subjects (table). In contrast to cortical blindness, these patients complained bitterly of their visual deficits and could describe the reduction of vision in detail.

Goldmann perimetry could be carried out in each patient. One patient had preserved hemimacula in the left field and a preserved temporal crescent (figure 1), one patient had a constricted visual field with preserved vision in the central 10 degrees in both eyes, and the other patient had a preserved upper 5 degrees of the central vision and a left homonymous upper quadrant of vision. Visual acuity varied from 20/20 to 20/50. The patient with preserved hemimacula was able to read small print; however, he complained that reading required great effort because often the characters in the right side of the page disappeared from view. The patient with preserved central vision could read well, whereas the other patient with preserved homonymous upper quadrant was unable to read because he could

**Table. Summary of patients' vision and cortical deficits**

Patient	Age/Sex	Etiology	Visual performance	CT	SPECT/PET	P-VEP	CFPD
<b>Total blindness</b>							
Case 1	72/F	Ischemic infarct, thrombotic	Total blindness, Anton's syndrome	Bilateral occipital lesions (17, 18, 19)	ND	Absent N70, normal P100	Limited to 28
Case 2	58/F	Ischemic infarct, thrombotic	Total blindness	Bilateral occipital lesions (17, 18, 19)	ND	ND	ND
Case 3	78/F	Cardiac surgery, ischemic infarct	Total blindness, Anton's syndrome	Bilateral extensive occipital lesions	No activity bilateral occipitotemporal	ND	ND
Case 4	74/F	Ischemic infarct, thrombotic	Total blindness, Anton's syndrome	Bilateral extensive occipital lesions	No activity bilateral occipital (17,18,19)	Absent to 30', absent to 60'	ND
Case 5	73/M	Cardiac arrest	Total blindness	Bilateral extensive occipital lesions	ND	ND	Limited to 8
<b>Blindness with residual vision</b>							
Case 6	81/M	Ischemic infarct, thrombotic	Light perception only, Anton's syndrome	Bilateral occipital lesions (17, 18, 19)	Small spared area 17 right side	Absent N70, normal P100	Limited to 16
Case 7	59/M	Ischemic infarct, thrombotic	Light perception + motion in right lower homonymous quadrants, Anton's syndrome	Bilateral occipital lesions	PET spared left part of area 17	Delayed VEP	Limited to 10
Case 8	72/M	Ischemic infarct, thrombotic	Light perception + motion in left lower homonymous quadrant, Anton's syndrome	Bilateral occipital lesions	Small spared area 17 right side	Absent to 15' and 30', delayed P100 to 60'	Limited to 24
Case 9	58/M	Cardiac surgery, ischemic watershed infarcts	Light perception + motion and outline large objects	Bilateral occipitotemporo-parietal lesions	ND	Delayed at 15', normal at 30' and 60'	ND
<b>Bilateral hemianopia</b>							
Case 10	61/M	Ischemic infarcts, thrombotic	Preserved both left hemimaculas and OS temporal crescent, VA 20/20 OS and OD, could read with difficulty	Bioccipital infarcts sparing upper lips area 17, areas 18 and 19 spared	ND	Normal at 15' and 30'	Normal at 42
Case 11	60/F	Mitral valve dis., embolic infarcts	Preserved central 10° field, VA 20/20 both eyes, good reading ability	Bioccipital infarcts sparing some bilateral area 17 and both areas 18 and 19	Patchy decrease midline occipital areas	Normal at 15' and 30'	ND
Case 12	65/M	Cardiac surgery, ischemic infarcts	Preserved left hemimacula and right temporal lower homonymous pie-shaped field, could not read	Small bilateral infarcts area 17, with spared anterior part of both 17 spared 18 and 19	ND	Normal at 15' and 30'	ND
VA		Visual acuity.		ND		Not done.	
P-VEP		Pattern evoked potentials.		OS		Left eye.	
CFPD		Cortical critical frequency of photic driving.		OD		Right eye.	

only see part of the printed field. He had normal saccadic and pursuit eye movements.

**Neuroimaging.** CTs were done in every subject and often repeated at follow-up. MRIs were also done in two patients. There was some variation in the extent of the ischemic lesions in every subject. As shown in figure 2, patients with complete cortical blindness had more extensive lesions in the occipital lobes than patients with an island of preserved rudimentary visual perception. Not only area 17, but area 18 and most of area 19 were involved bilaterally. The injury always extended to the optic radiations. Part of the midline cortical regions (area 17?) were often anatomically unaffected in patients with RRV. The CTs of patients with bilateral hemianopia (figure 3) showed the smallest lesions with extensive sparing of areas 17 and the peristriate cortices. Normal appearing tissue on the CT does not guarantee normal functional tissue. Often the midline structures were surrounded by decreased density (in-

farcted) tissue, suggesting that these areas may be deaf-ferented from their normal connections.

To answer the question of the functional integrity of the anatomically preserved tissue, PET and SPECT studies were done. Only six patients agreed to undergo this procedure (one patient with PET and five with SPECT). SPECT showed 60 to 70% decrease in IMP concentration in both occipital lobes relative to frontal lobe regions in two patients with total blindness, suggesting that the small spared occipital areas seen in their CTs were nevertheless nonfunctional. Two other patients with rudimentary vision had some activity in the cortex localized in the appropriate cortical area contralateral to the homonymous island or preserved vision (figure 4). X-ray CT showed small areas of normal radiodensity in cortical regions in these two patients. In both of these patients, SPECT was carried out in a resting state and repeated with visual flash stimulation. In one of these patients, the cortical occipital area

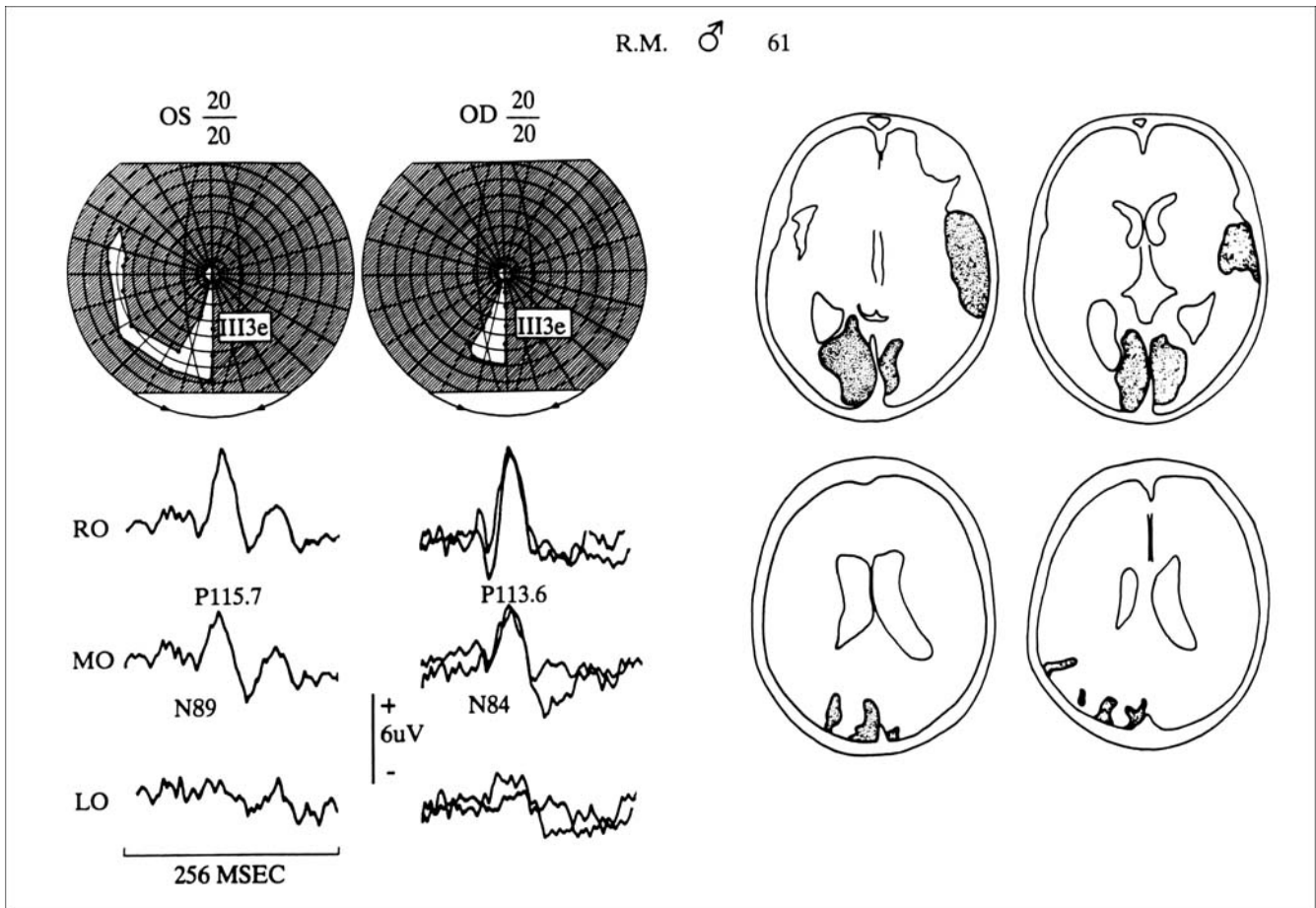


Figure 1. Patient 10, a 61-year-old man with bilateral hemianopia. Note the normal visual acuity and normal VEP to 30' checks. On the right half of the illustration are drawings of the patient's CT. The right side of the brain is shown on the right side of the template. On the upper left of the illustration are the Goldmann visual fields. The lower half of the left column illustrates the patient VEPs. Reduplication of VEPs was only carried out with stimulation of the right eye (OD).

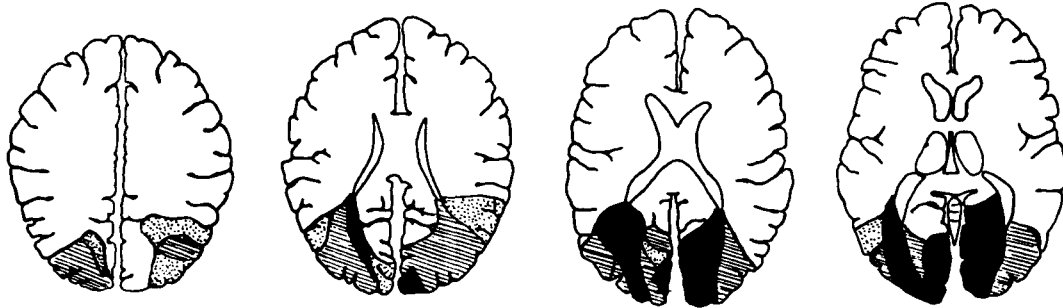
(presumably area 17), with nearly normal resting IMP concentration, showed a 25% increase in IMP activity with visual stimulation (figure 4), suggesting that visual stimuli were activating it. The other subject studied in this way showed no significant increase in occipital IMP activity with the photic stimulation. rCBF and LCMRGlC were studied with PET in a patient with Anton's syndrome, cortical blindness, and rudimentary vision (limited to perception of bright light) in the lower left homonymous peripheral field. rCBF was severely depressed over the entire posterior parieto-occipital region of both hemispheres. However, an island of residual rCBF (depressed to 16 ml/100 g/min; normal, 68 to 70 ml/100 g/min) was noted on the midline corresponding to right anterior striate cortex and around the banks of parieto-occipital sulcus. The same area showed 25% decreased LCMRGlC with  $^{18}\text{F}$ FDG, whereas the surrounding occipital hypometabolic zone had a 65 to 70% decreased LCMRGlC compared with normal metabolic areas in the same pattern. These findings indicate that the area anatomically preserved on CT had preserved, albeit reduced, function. In these five patients, the areas of severely decreased rCBF or glucose metabolism involved not only both areas 17, but also parastriate areas.

**Visual evoked potentials.** Pattern VEPs were performed in seven of the nine cortically blind patients.

Responses to small pattern (15' and 30') were absent in two patients with total blindness, but preserved to 30' and 60' stimuli in one patient. The VEP of this patient had no N70, but a normal P100 with a latency of 104 to 30' checks and 96 msec to 60' checks. Patients with residual vision had absent or delayed VEPs to 15' checks and delayed P100 with stimuli of 30' and 60'. Six patients had flash ERGs and VEPs recorded simultaneously. Flash ERGs were recorded to assure that the retina was functioning normally. Flash ERGs were normal in all cases. VEPs to flashes at a frequency of 1 Hz were within normal limits. The CFPD was tested in six patients. Retinal CFPD was normal, whereas cortical CFPD was reduced in each subject tested. Pattern VEPs and flash VEPs were normal in all patients with bilateral hemianopia (figure 1).

**Discussion.** The data presented here indicate that, in patients with extensive ischemic infarcts of both areas 17 (the striate cortices), there is no preservation of vision. Residual vision is associated with small spared remnants of area 17 and parastriate cortices (areas 18 and 19). In all nine patients with cortical blindness, the lesions were extensive and included areas 17, 18, and 19 and the optic radiations. Patients with residual vision had a larger area of spared occipital cortex than patients

## CORTICAL BLINDNESS with TOTAL LOSS of VISION



## CORTICAL BLINDNESS with RUDIMENTARY VISUAL PERCEPTION

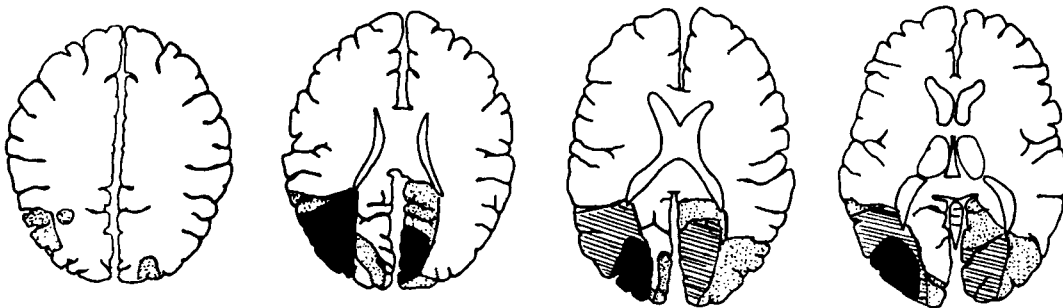


Figure 2. Composite drawings representing the patients' lesions observed with CTs. Black areas represent lesions observed in all patients. Dashed lines indicate lesions observed in four cases for the CTs of patients with total blindness and three cases for the patients with residual vision. Dotted areas indicate lesions limited to one patient. Note that the extent of lesions is greater in patients with total blindness. The right side of the brain is shown on the right side of the template.

## BILATERAL HOMONYMOUS HEMIANOPIA

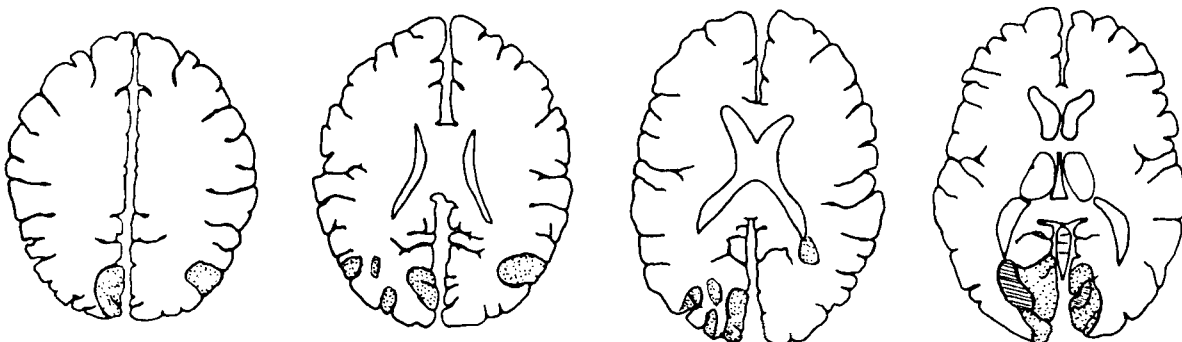


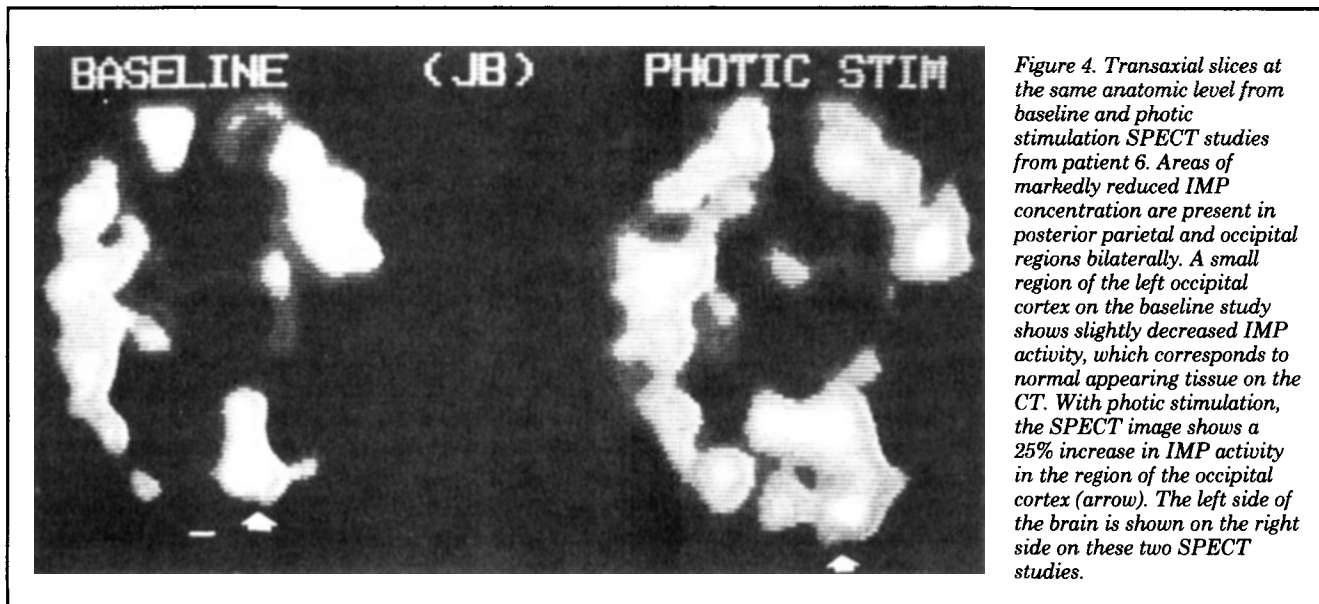
Figure 3. Composite drawings of the three patients with bilateral hemianopia. Note that the lesions were variable, and there was no lesion common to all three patients. (Lesions seen in all patients would be drawn black as in figure 2.) Only two small lesions around the calcarine lower lips of both hemispheres were involved in two patients (areas indicated by dashed lines). Dotted areas indicate lesions observed only in one patient. The right side of the brain is shown on the right side of the template.

with total blindness (figure 2). Patients with bilateral hemianopia not only had considerable sparing of area 17, but also showed little damage to surrounding areas 18 and 19 (figure 3). These patients also had no injury to the optic radiations.

Total blindness occurs whenever the entire striate

area is destroyed bilaterally or in cases when both areas 17 are disconnected from the prestriate cortices.

Bodis-Wollner et al<sup>26</sup> reported a 6-year-old boy who was completely blind since age 2 due to complete destruction of areas 18 and 19, with some spared striate cortex bilaterally. These authors concluded that total



*Figure 4. Transaxial slices at the same anatomic level from baseline and photic stimulation SPECT studies from patient 6. Areas of markedly reduced IMP concentration are present in posterior parietal and occipital regions bilaterally. A small region of the left occipital cortex on the baseline study shows slightly decreased IMP activity, which corresponds to normal appearing tissue on the CT. With photic stimulation, the SPECT image shows a 25% increase in IMP activity in the region of the occipital cortex (arrow). The left side of the brain is shown on the right side on these two SPECT studies.*

blindness can result from the destruction of areas 18 and 19, even when part of areas 17 is preserved. One of our patients with some preservation of area 17, but bilateral destruction of optic radiations and peristriate areas, remained similarly completely blind for 2 years. On the other hand, residual vision limited to light perception and occasionally to detection of motion for bright and large objects could, in every case, be explained by the survival of remnants of area 17. All of our patients had normal pupillary reflexes and eye movements, suggesting that the "second" visual system (retino-geniculate-tectal system) was functioning normally. Yet, when the striate and peristriate cortices were disabled, this system was incapable of providing visual perception. Our data are consistent with Brindley et al,<sup>27</sup> who report two cases of cortical blindness and conclude that destruction of the occipital lobes, when permanent, produces irreversible blindness. Other authors have reported similar cases of irreversible and complete cortical blindness.<sup>26,28,29</sup> We found no evidence that useful vision or even RRV is related to the extrageniculate "second" visual system. Indeed, we agree with Daroff<sup>30</sup> that humans with bilateral occipital lobe lesions are "quite blind despite a preserved tectal system." The present data further suggest that residual vision as reported by Perenin et al,<sup>8-10</sup> Ter Braak et al,<sup>31</sup> and others<sup>32,33</sup> cannot necessarily be attributed to the "second" visual system without demonstration of total functional deafferentation of area 17. This should be done either by a combination of CT/MRI and PET/SPECT response to photic stimulation or by postmortem anatomic verification. The evidence on neuroimaging and regional cerebral blood flow further indicates that there is a correlation between the amount of spared striate and parastriate cortices and useful vision. The amount of tissue that remains intact in the occipital areas determines the quality of preserved vision, from rudimentary vision to a 20/20 visual acuity and macular sparing.

Halpern and Sedler,<sup>34</sup> in cases of post-traumatic bilateral hemianopia, showed that retention of macular

vision and 20/20 visual acuity was due to sparing of the cortical representation of the central visual field. This may not, however, be the only mechanism for preservation of central vision. Lashley<sup>35</sup> pointed out that recovery of cerebral cortex function depends on the preservation of some part of the system affected by the lesion. Our three cases of bilateral hemianopia showed a surprisingly poor correlation between the extent of the visual field deficit and the location of the lesion, but rather suggested that the quantity of the spared tissue was a more important feature. This may be explained either by the possibility that the topography of macular representation varies considerably from one individual to another or that there is considerable plasticity in area 17. Following a destructive lesion, there may be a reorganization of central receptive fields in the striate area. Kaas et al<sup>36</sup> reported that in adult cats cortical neurons of areas 17 and 18 can acquire new receptive fields following selective retinal lesions, suggesting that the capacity of the visual area to adapt to such changes may be important in the recovery from brain damage.

The visual behavior of humans with bilateral destruction of visual cortices is very different than the visual behavior of other primates. The human brain may differ from that of other species in that the primary visual system may have acquired more specialized functions excluding the more primitive second system from visual conscious perception. Alternatively, the bilateral resection of the occipital cortex in primates may not have been total, thus the residual vision may reflect preserved function of the anterior striate cortex.<sup>4,15,37</sup>

Blindsight has been conclusively demonstrated in patients with hemianopia.<sup>7,9,38,39</sup> Several authors have shown, with well-designed studies, that some visual process is often preserved in the hemianopic field.<sup>38,39</sup> We do not argue with the existence of this phenomenon, but rather with the frequent interpretation that it represents the function of an extrageniculate visual system. We submit that there are two more plausible explanations. (1) Scattered light spreading into the in-

tact visual field is providing a cue to the subject.<sup>16</sup> (2) Portions of area 17 that process the information via the classic geniculostriate system are spared.

We found a disassociation between pattern VEP and visual function. The VEP to patterns was preserved in five of the seven patients tested, including one patient with total blindness. The wave form was normal, and only occasionally was the peak latency of the P100 delayed. Responses to flash were always present. Many authors have reported preservation of an essentially normal VEP in cortical blindness.<sup>20,26,28,40,41</sup> They suggested that the preserved VEPs are a response that originated either in remnants of area 17<sup>20,26</sup> or in extrastriate cortices.<sup>28,41</sup> Our data indicate that the VEP originated in remnants of area 17. They further show that the larger the amount of spared cortex the better are the responses. Each patient with bilateral hemianopia had normal responses to checkerboard stimulation including VEPs to stimuli subtending 15' of arc to the subject eye. Meredith and Celesia<sup>42</sup> studied the smallest size of patterned stimulus capable of producing a recordable VEP and estimated the size of the striate cortex activated by such a stimulus. They concluded that the activation of 7 mm<sup>2</sup> of striate cortex was sufficient to produce a VEP. Galambos et al<sup>43</sup> have reported that lesions sparing only 3% of the optic tract of animals is enough to produce a normal VEP. We conclude that VEPs can be recorded in subjects with cortical blindness and cannot be equated with preserved vision. VEPs are electrical phenomena to a visual stimulus and should not be confused with conscious perception of visual stimuli.

## References

1. Ter Braak JWG, Van Vliet AGM. Subcortical optokinetic nystagmus in the monkey. *Psychiatr Neurol Neurochir* 1963;66:277-283.
2. Weiskrantz L, Cowey A. Striate cortex lesions and visual acuity of the rhesus monkey. *J Comp Physiol Psychol* 1963;56:225-231.
3. Humphrey NK, Weiskrantz L. Vision in monkeys after removal of the striate cortex. *Nature* 1967;215:595-597.
4. Denny-Brown D, Chambers RA. Physiological aspects of visual perception: functional aspects of visual cortex. *Arch Neurol* 1976;33:219-227.
5. Ridloch G. Dissociation in visual perception due to occipital injuries, with special reference to appreciation of movement. *Brain* 1917;40:15-57.
6. Poppel E, Held R, Frost D. Residual visual function after brain wounds involving the central visual pathways in man. *Nature* 1973;243:295-296.
7. Weiskrantz L, Warrington EK, Sanders MD, Marshall J. Visual capacity in the hemianopic field following a restricted occipital ablation. *Brain* 1974;97:709-728.
8. Perenin MT, Jeannerod M. Residual vision in cortically blind hemifields. *Neuropsychologia* 1975;13:1-7.
9. Perenin MT, Jeannerod M. Visual function within the hemianopic field following early cerebral hemidecortication in man. I. Spatial localization. *Neuropsychologia* 1978;16:1-13.
10. Perenin MT, Ruel J, Hecaen H. Residual visual capacities in a case of cortical blindness. *Cortex* 1980;16:605-612.
11. Weller RE. Two cortical visual systems in old world and new world primates. In: Hicks TP, Benedek G, eds. *Vision within extrageniculostriate systems. Progress in brain research, vol 75.* Amsterdam: Elsevier, 1988:293-306.
12. Ungerleider LG, Mishkin M. Two cortical visual systems. In: Ingle DJ, Mansfield JW, Goodale MA, eds. *Advances in the analysis of visual behavior.* Cambridge: MIT Press, 1982:549-586.
13. Levine DN. Visual agnosia in monkey and in man. In: Ingle DJ, Mansfield JW, Goodale MA, eds. *Advances in the analysis of visual behavior.* Cambridge: MIT Press, 1982:629-670.
14. Mountcastle VB, Lynch JC, Georgopoulos A. Posterior parietal association cortex of the monkey: command functions for operations within extrapersonal space. *J Neurophysiol* 1975;38:871-908.
15. Creutzfeldt OD. Extrageniculostriate visual mechanisms: compartmentalization of visual functions. In: Hicks TP, Benedek G, eds. *Vision within extrageniculostriate systems. Progress in brain research, vol 75.* Amsterdam: Elsevier, 1988:307-320.
16. Campion J, Latto R, Smith YM. Is blindsight an effect of scattered light, spared cortex and near-threshold vision? *Behav Brain Sci* 1983;6:423-486.
17. Sprague JM, Berlucchi G, Rizzolatti G. The role of the superior colliculus and pretectum in vision and visually guided behavior. In: Jung R, ed. *Handbook of sensory physiology, vol VII/3.* Berlin: Springer-Verlag, 1973:27-101.
18. Celesia GG, Daly RF. VECA: a new electrophysiological test for the diagnosis of optic nerve lesions. *Neurology* 1977;27:637-641.
19. Celesia GG. Steady state and transient visual evoked potentials in clinical practice. *Ann NY Acad Sci* 1982;388:290-305.
20. Celesia GG, Polcyn RE, Holden JE, Nickles RJ, Gatley JS, Koeppe RA. Visual evoked potentials and positron emission tomographic mapping of regional cerebral blood flow and cerebral metabolism: can the neuronal potential generators be visualized? *Electroencephalogr Clin Neurophysiol* 1982;54:243-256.
21. Holden JE, Gatley SJ, Hichwa RD, et al. Cerebral blood flow using PET measurements of fluoromethane kinetics. *J Nucl Med* 1981;22:1084-1088.
22. von Schulthess GK, Ketz E, Schubiger PA, Bekier A. Regional quantitative assessment of cerebral perfusion and function with N-isopropyl-[123I]p-iodoamphetamine. *J Nucl Med* 1985;26:9-16.
23. Hill TC, Holman L, Lovett R, et al. Initial experience with SPECT (single-photon computerized tomography) of the brain using N-isopropyl 1-123 p-iodoamphetamine: concise communication. *J Nucl Med* 1982;23:191-195.
24. Marquis DG. Effects of removal of visual cortex in mammals with observations on the retention of light discrimination in dogs. *Proc Assoc Res Nerv Ment Dis* 1934;13:1-558.
25. Anton G. Über die selbstwahrnehmung der herderkrankungen des gehirns durch den kranken bei rindenblindheit und Rindentaubheit. *Arch Psychiatr Nervenkr* 1899;32:86-127.
26. Bodis-Wollner I, Atkin A, Raab E, Wolstein M. Visual association cortex and vision in man: patterned evoked potentials in a blind boy. *Science* 1977;198:629-631.
27. Brindley GS, Gautier-Smith PC, Lewin W. Cortical blindness and the functions of the non-geniculate fibres of the optic tracts. *J Neurol Neurosurg Psychiatry* 1969;32:259-264.
28. Celesia GG, Archer CR, Kuroiwa Y, Goldfader PR. Visual function of the extrageniculocalcarine system in man. *Arch Neurol* 1980;37:704-706.
29. Aldrich MS, Alessi AG, Beck RW, Gilman S. Cortical blindness: etiology, diagnosis and prognosis. *Ann Neurol* 1987;21:149-158.
30. Daroff R. Discussion of paper by Botez MI. Two visual systems in clinical neurology: the readaptive role of the primitive tectal system in visual agnostic patients. *Trans Am Neurol Assoc* 1972;63-65.
31. Ter Braak JWG, Schenk VWD, Van Vliet AGM. Visual reactions in a case of long-lasting cortical blindness. *J Neurol Neurosurg Psychiatry* 1971;34:140-147.
32. Botez MI. Two visual systems in clinical neurology: readaptive role of the primitive system in visual agnostic patients. *Eur Neurol* 1975;13:101-122.
33. Hoff H, Gloning I, Gloning K. Neuropsychological symptoms and syndromes in lesions of the occipital lobes and adjacent areas. Paris: Gauthier-Villars, 1968.
34. Halpern JI, Sedler PR. Traumatic bilateral homonymous hemianopic scotomas. *Ann Ophthalmol* 1980;12:1022-1026.
35. Lashley KS. Factors limiting recovery after central nervous lesions. *J Nerv Ment Dis* 1938;88:733-755.
36. Kaas JH, Krubitzer LA, Chino YM, Langston AL, Polley EH, Blair N. Reorganization of retinotopic cortical maps in adult mammals after lesions of the retina. *Science* 1990;248:229-231.
37. Lambert SR, Hoyt CS, Jan JE, Barkovich J, Flodmark O. Visual

- recovery from hypoxic cortical blindness during childhood: computer tomographic and magnetic resonance imaging predictors. *Arch Ophthalmol* 1987;105:1371-1377.
38. Corbetta M, Marzi CA, Tassinari G, Aglioti S. Effectiveness of different task paradigms in revealing blindsight. *Brain* 1990;113:603-616.
39. Rafal R, Smith J, Krantz J, Cohen A, Brennan C. Extrageniculate vision in hemianopic humans: saccade inhibition by signals in the blind field. *Science* 1990;250:118-120.
40. Jayle GE, Tassy AF, Deransart-Ferrero J, Cornand A. Un cas de

- cecité corticale avec conservation du potentiel évoqué visuel occipital. *Rev Otonéuroophthalmol* 1971;43:229-232.
41. Spehlmann R, Gross RA, Ho SU, Leestma JE, Nocross KA. Visual evoked potentials and post-mortem findings in a case of cortical blindness. *Ann Neurol* 1977;2:531-534.
42. Meredith JT, Celesia GG. Pattern-reversal visual evoked potentials and retinal eccentricity. *Electroencephalogr Clin Neurophysiol* 1982;53:243-253.
43. Galambos R, Norton TT, Frommer GP. Visual evoked responses in cats with optic tract lesions. *Exp Neurol* 1967;18:8-25.



# Behavioral state-specific changes in human hippocampal theta activity

K.J. Meador, MD; J.L. Thompson, MS; D.W. Loring, PhD; A.M. Murro, MD; D.W. King, MD; B.B. Gallagher, MD, PhD; G.P. Lee, PhD; J.R. Smith, MD; and H.F. Flanigin, MD

**Article abstract**—Although there has been extensive examination of the behavioral and physiologic correlates of hippocampal theta activity in animals, the human literature consists of a single case study. We investigated the differential effects of four behavioral states on human hippocampal theta activity in 16 epilepsy surgery patients. Behavioral conditions included resting eyes closed (RC), resting eyes open (RO), eyes open with auditory word activation (AW), and eyes open with visuospatial activation (VS). Hippocampal theta activity decreased during both RO and VS compared to both RC and AW. There were reciprocal changes in delta activity. Comparisons of RO to VS and of RC to AW were nonsignificant. The results demonstrate state-specific changes in human hippocampal theta and are consistent with the animal literature that relates hippocampal theta to sensorimotor integration and forebrain volitional mechanisms.

NEUROLOGY 1991;41:869-872

Numerous animal studies have examined the relationship of behavior to the hippocampal EEG.<sup>1-4</sup> Overall, the hippocampal EEG of animals has been characterized by a predominant theta rhythm known as "rhythmic slow activity" (RSA), which is associated with certain types of behavior. In contrast to the extensive literature concerning animals, few studies have examined behavioral effects on human hippocampal EEG. We previously demonstrated electrophysiologic responsiveness of the human hippocampus to behavioral activation.<sup>5,6</sup> In these reports, hippocampal EEG spectral power uniformly decreased during behavioral activation. The change in EEG was quantitatively different across tasks, but there were no qualitative differences in spectral components. In contrast, Arnolds et al<sup>7</sup> reported subtle but definite theta changes in hippocampal EEG of an epileptic patient in response to various behavioral tasks. Therefore, we reinvestigated theta reactivity by examining the relatively normal hippocampi (ie, contralateral to seizure onset) for sub-

tle theta alterations across a variety of behavioral tasks.

**Methods. Subjects.** Sixteen patients with intractable complex partial epilepsy underwent depth electrode implantation as a part of their preoperative evaluation. There were eight men and eight women with mean age 31 (range, 17 to 42). Handedness as determined by the Benton Handedness Inventory<sup>8</sup> was 13 right and three left. Language dominance was determined by the intracarotid amobarbital test, which revealed 13 patients with left and three with mixed cerebral dominance. Site of seizure onset was based on multiple ictal EEG recordings during habitual seizures, using bilateral depth, sphenoidal, and scalp electrodes. Six patients had right hippocampal seizure onset, nine patients had left hippocampal onset, and one patient had an unlocalized extrahippocampal onset. Fourteen patients subsequently underwent seizure surgery. One patient had an oligodendroglioma, and gliosis was the only histopathologic finding in the remaining cases. In the present analysis, we included only patients who had vertex trajectory depth electrodes and who had testing in all four behavioral conditions. Four new cases were added to those

From the Departments of Neurology and Surgery (Neurosurgery), Medical College of Georgia, Augusta, GA.

Supported in part by NIH/NIA grant # K08 AG00314 and by the Medical College of Georgia Research Institute.

Presented in part at the 42nd annual meeting of the American Academy of Neurology, Miami, FL, April 1990, and at the Second International Cleveland Clinic Epilepsy Symposium, Cleveland, OH, June 1990.

Received August 30, 1990. Accepted for publication in final form November 30, 1990.

Address correspondence and reprint requests to Dr. Kimford J. Meador, Section of Behavioral Neurology, Department of Neurology, Medical College of Georgia, Augusta, GA 30912.



# Neurology<sup>®</sup>

## **Cortical blindness and residual vision: Is the "second" visual System in humans capable of more than rudimentary visual perception?**

G. G. Celesia, D. Bushnell, S. Cone Toleikis, et al.

*Neurology* 1991;41;862

DOI 10.1212/WNL.41.6.862

**This information is current as of June 1, 1991**

<b>Updated Information &amp; Services</b>	including high resolution figures, can be found at: <a href="http://www.neurology.org/content/41/6/862.full.html">http://www.neurology.org/content/41/6/862.full.html</a>
<b>Citations</b>	This article has been cited by 2 HighWire-hosted articles: <a href="http://www.neurology.org/content/41/6/862.full.html##otherarticles">http://www.neurology.org/content/41/6/862.full.html##otherarticles</a>
<b>Permissions &amp; Licensing</b>	Information about reproducing this article in parts (figures, tables) or in its entirety can be found online at: <a href="http://www.neurology.org/misc/about.xhtml#permissions">http://www.neurology.org/misc/about.xhtml#permissions</a>
<b>Reprints</b>	Information about ordering reprints can be found online: <a href="http://www.neurology.org/misc/addir.xhtml#reprintsus">http://www.neurology.org/misc/addir.xhtml#reprintsus</a>

*Neurology*® is the official journal of the American Academy of Neurology. Published continuously since 1951, it is now a weekly with 48 issues per year. Copyright © 1991 by the American Academy of Neurology. All rights reserved. Print ISSN: 0028-3878. Online ISSN: 1526-632X.

