

## Self-Injection of Insulin Using Appropriate Supportive Devices in Handicapped Subjects with Diabetes

Kiyomi Masuda, M.D., Kazutaka Aoki, M.D., Ph.D., Kaori Kikuchi, M.D., Uru Nezu, M.D.,  
Tomonori Muraoka, M.D., Kazuaki Shinoda, M.D., Akinobu Nakamura, M.D., Ph.D.,  
Makoto Shibuya, M.D., Mayumi Takahashi, M.D., Mari Kimura, M.D., Ph.D.,  
and Yasuo Terauchi, M.D., Ph.D.

### Abstract

**Background:** To self-inject insulin, individuals with diabetes must be able to attach the needle to the injector, recognize the appropriate insulin dosage, detach the needle from the injector, and perform a series of operations necessary for the actual injection. These tasks require a grip strength that is strong enough to hold the necessary devices, eyesight, the use of both hands, and at least a minimum intellectual capacity. Subjects who are unable to grasp or handle the devices required for insulin injection often have difficulties with the self-injection of insulin.

**Methods:** We treated four diabetes patients who had trouble grasping objects and using both hands. One patient had lost five fingers in an accident, two patients had suffered from ischemic cerebral infarction resulting in complete one-sided hemiplegia with no movement in one arm, and one patient had limited muscular power in an arm as a result of spinal cord disease. The plasma glucose control was poor, and the initiation of insulin therapy was necessary in each of these patients. In three cases, we used a commercially available self-injection device (HumaHelper™; Eli Lilly Japan K.K., Kobe, Japan) to enable self-injection; in the fourth case, we used a newly manufactured device similar to HumaHelper.

**Results:** All the patients were able to inject insulin by themselves using the appropriate supplementary devices. The blood glucose control of all the patients subsequently improved.

**Conclusion:** Existing or newly manufactured supportive devices can enable handicapped subjects to self-inject insulin.

### Introduction

THE INTERNATIONAL DIABETES FEDERATION has estimated that the world prevalence of diabetes will reach 6.4% in 2010 and will further increase to 7.7% by the year 2030.<sup>1</sup> These numbers represent as many as 344 million individuals when subjects with impaired glucose tolerance are included.<sup>1</sup> The progressive nature of type 2 diabetes is characterized by diminishing insulin secretion and increasing insulin resistance.<sup>2,3</sup> When beta cells adequately respond to increased insulin requirements, oral hypoglycemic agents (OHAs) can be used to improve glucose control. However, once the endogenous insulin secretion is exhausted, adequate glycemic control cannot be maintained even with increased doses of OHAs; in such cases, additional insulin treatment is often necessary. The Diabetes Control and Complications Trial<sup>4</sup> and Kumamoto<sup>5</sup> studies proved that strict blood control using intensive insulin therapy is associated with a reduction in microvascular events. Thus, insulin represents one of the

greatest discoveries of the 20<sup>th</sup> century, enabling the treatment of diabetes mellitus.

However, patients face many problems when they first begin insulin treatment to maintain favorable glucose control. To self-inject insulin, individuals with diabetes must be able to attach the needle to the injector, recognize the appropriate insulin dosage, detach the needle from the injector, and perform a series of operations necessary for the actual injection. These tasks require a grip strength that is strong enough to hold the necessary devices, eyesight, the use of both hands, and at least a minimum intellectual capacity. The most common cause of difficulty performing self-injections is ischemic cerebral infarction resulting in complete one-sided hemiplegia; the second most common cause of difficulty is a decrease in muscular power as a result of aging, diabetic neuropathy, or spinal cord disease. Patients who cannot use both hands because of finger or arm amputations also have difficulty performing self-injections. Therefore, performing the series of operations required for self-injection can be quite difficult for

subjects who are unable to grasp or handle the standard devices used for insulin injection. These problems can delay the start of insulin treatment or even prevent treatment.

Sohmiya et al.<sup>6</sup> and Harvey et al.<sup>7</sup> reported the design and fabrication of supplementary devices for use with insulin pens that enabled patients who had suffered from an ischemic cerebral infarction resulting in complete one-sided hemiplegia to self-inject insulin. Moreover, three other reports have described the design and fabrication of a supplementary tool for use with vial and syringe-type insulin injection by hemiplegic subjects.<sup>8–10</sup> In these reports, healthcare professionals designed and fabricated the supplementary devices used by their patients; however, such treatments are very difficult and time consuming. The use of supplementary tools that are commercially available or easily made has not been previously reported. Here, we describe the cases of four patients with diabetes who initially had difficulty injecting insulin by themselves but who were ultimately successful once they began using an appropriate supplementary device. Three of these patients used HumaHelper™, a commercially available self-injection device distributed by Eli Lilly Japan K.K. (Kobe, Japan), with two of the patients using additional supplementary tools. The fourth patient used a supplementary device that was similar to HumaHelper.

## Cases

The details of each case are summarized in Table 1.

### *Case 1 (a 54-year-old woman with type 2 diabetes mellitus who had lost all of her left fingers)*

The patient had been diagnosed as having diabetes at the age of 47 years. Sulfonylurea, pioglitazone, and an  $\alpha$ -glucosidase inhibitor were prescribed, but her plasma glu-

cose control was poor (hemoglobin A1c [HbA1c], 10.0%). She was admitted to our hospital for the stringent control of her blood glucose level.

Because the patient's endogenous insulin secretion capacity was extremely impaired, we planned to switch her treatment from OHAs to insulin. However, as she had lost her five left fingers in an accident at the age of 49 years, she had great difficulty injecting the insulin by herself. We therefore instructed her in the use of an insulin self-injection device (HumaHelper) to be used with the HumaPen® Luxura™ [HL] (Eli Lilly and Co., Indianapolis, IN), which enabled her to inject the insulin single-handedly. As shown in Figure 1, the HumaHelper device is a cylinder rubber product (outside diameter, 50 mm; height, 50 mm) that can be fixed to the surface of a table. The device has two holes: a small hole, for attaching the needle and turning the insulin unit dial, and a large hole, for the insertion of the insulin cartridge. This device was originally designed for use with the HL insulin doser, but it also works well when used in combination with the FlexPen® [FP] (Novo Nordisk, Copenhagen, Denmark).

The patient began injecting a biphasic insulin analog (Humalog® Mix50™, Eli Lilly and Co.) twice daily. The HumaHelper made it possible for her to attach and remove the needles and to self-inject the insulin (Fig. 2). Three months after the introduction of the insulin therapy, her HbA1c level had decreased to 6.9%.

### *Case 2 (a 67-year-old woman with type 2 diabetes mellitus who could not move her right arm because of complete right hemiplegia)*


The patient had been diagnosed as having diabetes at the age of 60 years. An OHA was prescribed, and her plasma

TABLE 1. DETAILS OF THE FOUR CASES

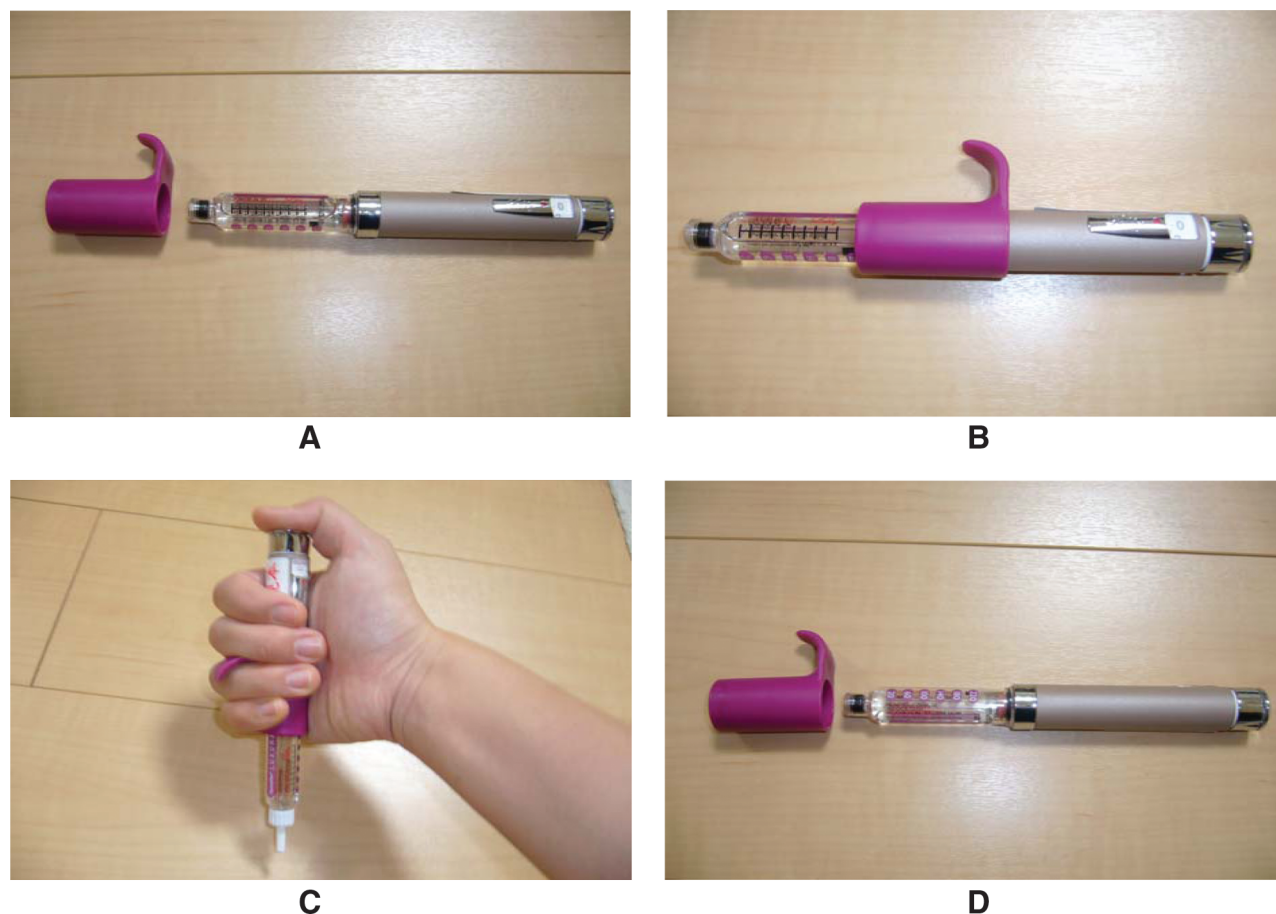
Case number	Age (years)	Kinds of handicap	Background	Previous treatment	Supplementary devices	Improvement (before → after 3 months on insulin therapy)
1	54	Both hands are not usable	Five left fingers lost because of an accident	Sulfonylurea, $\alpha$ -glucosidase inhibitor, thiazolidinedione	HumaHelper	HbA1c level 10.0% → 6.4%
2	67	Both hands are not usable; left grip strength is weak	Complete right hemiplegia, due to cerebral infarction, aging	Sulfonylurea, $\alpha$ -glucosidase inhibitor	HumaHelper, HL slipping stop	Fasting blood sugar level 141 ± 35 mg/dL → 93 ± 5 mg/dL
3	64	Both hands are not usable; left grip strength is weak	Cervical spondylosis	Sulfonylurea	HumaHelper, splint for left hand	HbA1c level 8.1% → 6.0%
4	72	Both hands are not usable; reduced vision	Complete left hemiplegia, due to cerebral infarction, aging	Insulin (NovoMix 30)	Original self-injection device made from empty container of PET bottle, clay, and skid mat	Fasting blood sugar level 148 ± 39 mg/dL → 106 ± 32 mg/dL



**FIG. 1.** (A) General appearance of the insulin self-injection device (HumaHelper). (B) Top view of HumaHelper. Color images available online at [www.liebertonline.com/dia](http://www.liebertonline.com/dia).



**FIG. 2.** Procedure for insulin self-injection (Case 1). (A) A needle is placed in the small hole of the device. (B) The needle's protection sticker is peeled away. (C) A pen-type insulin injector (HL) is placed directly over the needle. The pen is twisted clockwise and fixed in place. (D) The patient turns the unit dial for the insulin, and the injector is withdrawn vertically after removing the needle's cap. (E) The patient injects the insulin subcutaneously into the abdomen. (F) The HL with the needle is inserted straight into the needle cover fixed in the small hole of the device, twisted counterclockwise, and removed. (G) The HL is removed from the tool, and the cap is put in place. The needle is removed from the device and thrown away. Color images available online at [www.liebertonline.com/dia](http://www.liebertonline.com/dia).



**FIG. 3.** General appearance and use of the HL slipping stop (Case 2). (A) The slipping stop tool is fixed over the HL before the needle is installed. (B) The tool is firmly pushed along the length of the HL until it cannot be pushed any further. (C) The tool's finger stop is placed between the user's fingers, and the pen is grasped and used. (D) The slipping stop tool is removed from the HL after the needle has been removed. Color images available online at [www.liebertonline.com/dia](http://www.liebertonline.com/dia).

glucose control improved. Her renal dysfunction, however, was exacerbated because of anti-neutrophilic cytoplasmic antibody-related nephritis. She was admitted to our hospital with the intention of switching her treatment from the OHA to insulin. The patient lived alone and had suffered an ischemic cerebral infarction at the age of 63 years, resulting in complete right hemiplegia with no movement in her right arm.

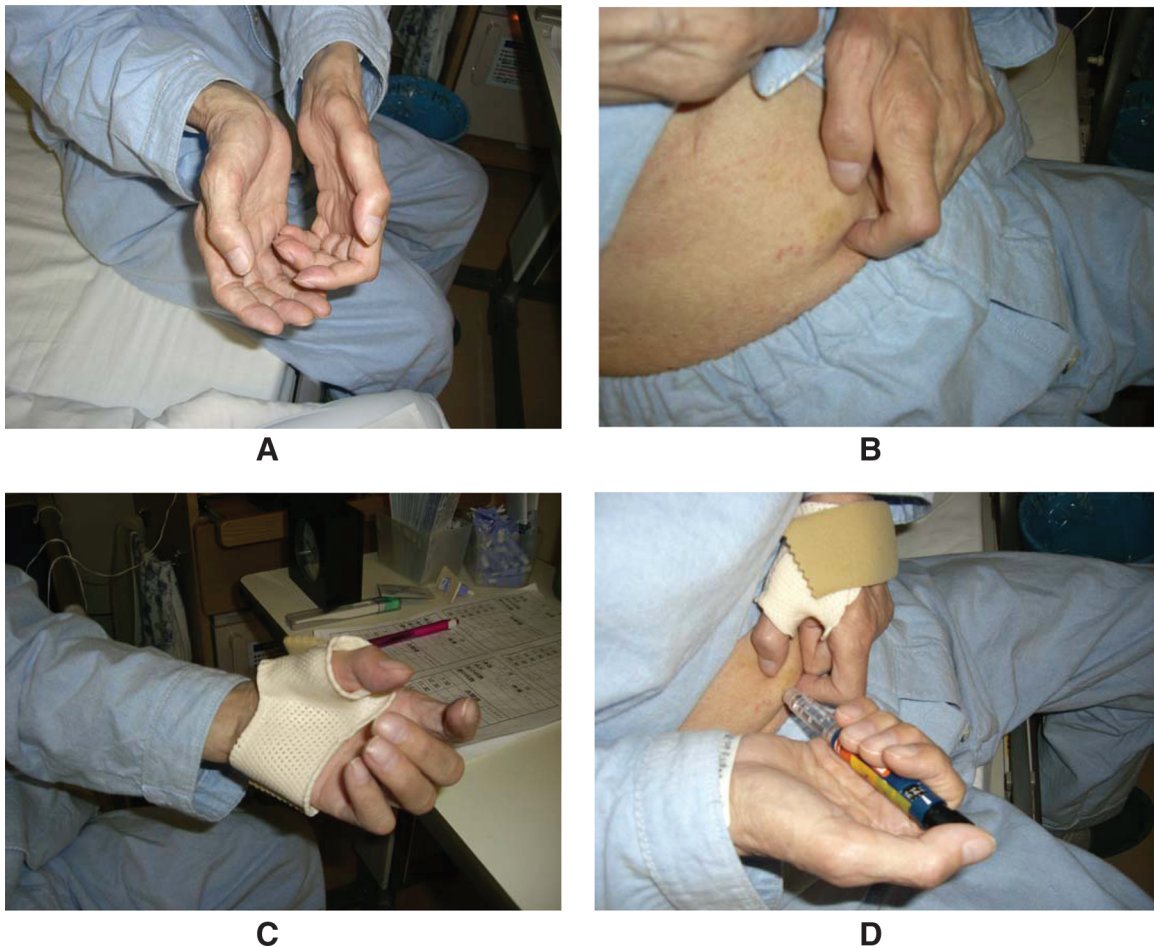
We instructed her in the use of an insulin self-injection device (HumaHelper) to allow her to perform the insulin injections using her left hand. She began injecting a biphasic insulin analog (Humalog Mix50) once daily. However, once she had placed the appropriate number of insulin units in the needle, she was unable to maintain the insulin injector in a stable position because her grip was inadequate. We therefore instructed her in the combined use of the HumaHelper and an HL slipping stop so that she would be able to self-inject the insulin successfully using her non-dominant left hand. The use of the HL slipping stop is illustrated in Figure 3. The combined use of these devices enabled her to self-inject the insulin. Three months after the introduction of the insulin therapy, she was able to self-inject the insulin, and her fasting blood sugar level had improved from  $141 \pm 35$  mg/dL before insulin therapy to  $93 \pm 5$  mg/dL.

#### *Case 3 (a 64-year-old man with type 2 diabetes mellitus)*

The patient had been diagnosed as having diabetes at the age of 58 years. Sulfonylurea was administered, but his plasma glucose control was poor. He was admitted to our hospital for the stringent control of his glucose level. Because of chronic pancreatitis, the patient's endogenous insulin secretion was markedly impaired. We therefore initiated intensive insulin therapy (Novorapid® [16-7-16-0]/Novolin N® [0-0-0-4] [both from Novo Nordisk]) using an FP. During the course of the patient's hospitalization, the muscles of his left arm were found to be atrophic (Fig. 4A), and the muscular power of his left hand was markedly decreased. He was diagnosed as having cervical spondylotic myelopathy.

We instructed the patient in the use of an insulin self-injection device (HumaHelper) to enable him to inject insulin using only his right hand. The patient commented that he would be able to perform the injection more smoothly if he could lift his abdomen with his left hand (Fig. 4B). This inspired an occupational therapist to make a splint for his left hand, enabling the patient to lift his abdomen using the splint sheet (ORFIT Industries, Wijnegem, Belgium) (Fig. 4C). Through the combined use of this splint and the HumaHelper,





**FIG. 4.** Use of a splint (Case 3). (A) The patient's muscles in his left hand have atrophied, and his muscular power has decreased. (B) The patient cannot lift his abdomen using his left hand. (C) A splint (short opponens) was placed on his left hand. (D) With the splint in position, the patient was able to lift his abdomen using his left hand, allowing him to master the smooth self-injection of insulin. Color images available online at [www.liebertonline.com/dia](http://www.liebertonline.com/dia).

the patient was able to master the smooth self-injection of insulin (Fig. 4D). Three months after the introduction of insulin therapy, he was able to self-inject the insulin, and his HbA1c level had improved from 8.1% before insulin therapy to 6.0%.

**Case 4 (a 72-year-old man with type 2 diabetes mellitus and complete left hemiplegia)**


The patient had been diagnosed as having diabetes at the age of 30 years. His renal dysfunction was severely impaired because of chronic renal failure associated with poor long-term blood pressure control. He was treated at another hospital, and insulin treatment was started. At the age of 68 years, he suffered an ischemic cerebral infarction resulting in complete left hemiplegia with no movement in the left arm. While he was admitted at another hospital, the nurses in charge of his care injected insulin (NovoMix 30) subcutaneously into his abdomen twice a day. Afterwards, he was admitted to our hospital in the hope that he would be able to master insulin self-injection using his injured right hand.

We instructed him in the use of an insulin self-injection device (HumaHelper) with an FP to enable him to inject insulin

using only one hand. However, he had difficulty detaching the needle from the device because of his poor eyesight. An occupational therapist made an insulin self-injection device using an empty polyethylene terephthalate (PET) bottle, modeling clay, and a skid mat. The fabrication of this device is shown in Figure 5. The patient was able to master the self-injection of insulin using this new device because the needle can be detached at eye level (Fig. 5F). This device is useful for subjects with impaired vision because the needle can be detached at a position within their range of vision. Three months after the introduction of insulin therapy, he was able to self-inject the insulin, and his fasting blood sugar level had improved from  $148 \pm 39$  mg/dL before insulin therapy to  $106 \pm 32$  mg/dL.

**Discussion**

To self-inject insulin, a grip strength strong enough to hold the necessary devices, eyesight, the use of both hands, and at least a minimum intellectual capacity are needed. Manual dysfunction arising from finger amputation, a cerebrovascular incident, or muscle weakness can make the self-injection of insulin quite difficult, possibly leading to a diminished



**FIG. 5.** Fabrication method (Case 4). (A) An empty 500-mL PET bottle, some modeling clay, and a skid mat are required to fabricate the device. (B) The container is divided into three pieces, and the upper and lower parts are used. A tape is placed over the cut surfaces to prevent injury. (C) The mat is matched and cut to size so that it lines the inside circumference of the drinking opening and covers the bottom of the PET bottle. (D) The modeling clay is shaped into a lump that will fill the lower part of the PET bottle. (E) The modeling clay is packed into the lower part of the PET bottle and covered with the upper part of the PET bottle. The skid mat is placed on the bottom of the device so that it will not slip while the needle of the insulin injection syringe is being fixed in place. To improve the adhesion between the insulin injector and this device, the skid mat is also used to line the inside circumference of the PET bottle's drinking opening. (F) A pen-type insulin injector is placed in the device, allowing the needle to be mounted at eye level. This device is useful for subjects with impaired vision because the needle can be detached at eye level. Color images available online at [www.liebertonline.com/dia](http://www.liebertonline.com/dia).

quality of life. Between April 2007 and February 2008, we treated four diabetes patients who had trouble grasping objects or using both hands. Though the numbers of cases are only four, the most important finding of the present series was that all the patients were able to self-inject insulin using existing or newly made supplementary devices. Blood glucose control was subsequently improved in all the patients. After 3 months on the insulin therapy, HbA1c levels were improved from 10.0% to 6.9% in Case 1 and from 8.1% to 6.0% in Case 3, respectively. Fasting blood glucose levels were improved from  $141 \pm 35$  mg/dL to  $93 \pm 5$  mg/dL in Case 2 and from  $148 \pm 39$  mg/dL to  $106 \pm 32$  mg/dL of Case 4, respectively.

In Case 1, the patient was able to self-inject insulin using only the HumaHelper. In Case 2, the patient was able to self-inject the insulin using a HumaHelper, but she often dropped the injection device because of her poor grip when using her left hand. Therefore, we instructed her in the combined use of HumaHelper and an HL slipping stop. This kit was also commercially available. In Case 3, the patient was able to self-inject the insulin using a HumaHelper; however, as this patient wished to perform the procedure more smoothly, an occupational therapist made him a splint. In Case 4, the patient's poor eyesight made it difficult for him to detach the needle; consequently, an occupational therapist made a device that enabled the patient to detach the needle close to

his eyes. This device enabled the patient to master the self-injection of insulin.

Proper use of the HumaHelper requires some training. If other problems are noted during the training period, supplementary tools can be used to provide a solution.

The HL is a durable insulin pen that contains a replaceable insulin cartridge, and patients can replace empty cartridges with the aid of a HumaHelper. The dial of this device can be easily manipulated. On the other hand, the FP is a disposable and prefilled insulin injector that is lighter than the HL but somewhat expensive in Japan. We selected either the HL or the FP according to the patients' preferences. Compared with vials and syringes, insulin pens offer substantial improvements in compliance, freedom, and flexibility for all insulin-using patients.<sup>11–13</sup> Consistent with these results, many studies have reported a preference for pen devices over traditional syringes.<sup>14–16</sup> The insulin pen has made independent insulin delivery among blind patients with diabetes easier by eliminating the need to visually draw up insulin from a vial.<sup>17</sup> The clarity of the click when setting a dose on an insulin delivery device also reportedly affects a patient's confidence in selecting the correct dose.<sup>18</sup>

In Japan, a newly made supplementary device for use with an insulin pen has been reported; this device was designed for use by hemiplegic patients,<sup>6</sup> and several case reports on such supplementary devices have been published in Japanese. On

the other hand, only a few similar reports have been made in Europe and North America.<sup>7-10</sup> One report<sup>7</sup> described a device for use with an insulin pen, while three other reports<sup>8-10</sup> described devices for use with vial and syringe-type insulin injections. These differences might reflect differences in the methods used for the self-injection of insulin between Japan and other countries. In Japan, up to 90% of all insulin injections are reportedly performed using pen-type devices, whereas insulin pens account for only 14% of all insulin injections in the United States.<sup>19</sup>

In all of these reports, the healthcare professionals designed and fabricated the supplementary devices used by their patients. The use of an existing supplementary tool has not been previously reported. In the present report, we used a commercially available self-injection device (HumaHelper) for three patients and a newly made device similar to the HumaHelper for one patient.

Healthcare professionals must ensure that appropriate supplementary devices are available for patients who have trouble grasping objects or using both hands. However, it is not easy for healthcare professionals to fabricate such devices from scratch within the period of an individual patient consultation. Therefore, self-injection devices should be available commercially. Much to our regret, however, the HumaHelper has been discontinued; in Japan, however, a similar rubber product is being sold for another use under the name "AORI-GOMU" (Waki Sangyo Co., Ltd., Osaka, Japan). The AORI-GOMU is a rubber band that can be applied to the leg of a chair and the gate in a truck bed. Healthcare professionals can purchase this product and instruct patients who have trouble grasping objects or using both hands to use this product to self-inject insulin according to the instructions in the pamphlet provided with the HumaHelper. However, few healthcare professionals are aware that the AORI-GOMU can be used in such a manner. We hope that a self-injection device similar to the HumaHelper will become commercially available worldwide, as such a product would greatly benefit diabetes patients and their families. We also hope that patients who have trouble grasping objects or using both hands will be able to use such devices to self-inject insulin without requiring the help of another individual.

## Conclusions

To self-inject insulin, a series of actions are required: the needle must be attached to the device, a dial must be turned or set to select the insulin dose, a series of operations must be performed for the actual injection of the insulin, and the needle must be detached. We treated four patients who had difficulty grasping objects or using both of their hands, complicating the self-injection of insulin. Appropriate supportive devices, either existing or newly manufactured, enabled the handicapped subjects to self-inject insulin. Such devices would greatly benefit handicapped subjects with diabetes throughout the world.

## Acknowledgments

This work was supported in part by the Yokohama City University Center of Excellence Program and a grant for the 2007 Strategic Research Project (K19004) of Yokohama City University.

## Author Disclosure Statement

No competing financial interests exist.

## References

1. International Diabetes Federation: Diabetes Atlas, 4<sup>th</sup> ed. International Diabetes Foundation, Brussels, 2009.
2. Lebovitz HE: Type 2 diabetes: an overview. *Clin Chem* 1999;45:1339-1345.
3. U.K. Prospective Diabetes Study 16. Overview of 6 years' therapy of type 2 diabetes: a progressive disease. U.K. Prospective Diabetes Study (UKPDS) Group. *Diabetes* 1995; 44:1249-1258.
4. The effect of intensive treatment of diabetes on the development and progression of long-term complications in insulin-dependent diabetes mellitus. The Diabetes Control and Complications Trial Research Group. *N Engl J Med* 1993;329:977-986.
5. Ohkubo Y, Kishikawa H, Araki E, Miyata T, Isami S, Motoyoshi S, Kojima Y, Furuyoshi N, Shichiri M: Intensive insulin therapy prevents the progression of diabetic microvascular complications in Japanese patients with non-insulin-dependent diabetes mellitus: a randomized prospective 6-year study. *Diabetes Res Clin Pract* 1995;28: 103-117.
6. Sohmiya M, Kanazawa I, Inomata N, Yonehara S, Sumigawa M, Terai R, Shitamori A, Kagawa M, Kato Y: A new device to introduce self-injection of insulin by his non-dominant hand in a patient with hemiplegia. *Diabetes Technol Ther* 2004;6:505-509.
7. Harvey RL, Stachowski KM, Dewulf SK: Independent insulin administration by the hemiplegic patient: stabilization of an insulin pen with a new device. *Arch Phys Med Rehabil* 1992;73:779-781.
8. Keon HM, Hanna AK: Self-administration of insulin by a hemiplegic individual. *Diabetes Care* 1980;3:705.
9. Holliman K: Another device for one-handed insulin management. *Am J Occup Ther* 1979;33:393.
10. Bray J, Mattern GK: Device for one-handed insulin injection. *Am J Occup Ther* 1968;22:534.
11. Summers KH, Szeinbach SL, Lenox SM: Preference for insulin delivery systems among current insulin users and nonusers. *Clin Ther* 2004;26:1498-1505.
12. Bohannon NJ: Insulin delivery using pen devices. Simple-to-use tools may help young and old alike. *Postgrad Med* 1999;106:57-68.
13. Da Costa S, Brackenridge B, Hicks D: A comparison of insulin pen use in the United States and the United Kingdom. *Diabetes Educ* 2002;28:52-60.
14. Korytkowski M, Bell D, Jacobsen C, Suwannasari R; FlexPen Study Team: A multicenter, randomized, open-label, comparative, two-period crossover trial of preference, efficacy, and safety profiles of a prefilled, disposable pen and conventional vial/syringe for insulin injection in patients with type 1 or 2 diabetes mellitus. *Clin Ther* 2003;25:2836-2848.
15. Shemet J, Schwartz S, Cappleman J, Peterson G, Skovlund S, Lytzen L, Nicklasson L, Liang J, Lyness W; InnoLet Study Group: Preference and resource utilization in elderly patients: InnoLet versus vial/syringe. *Diabetes Res Clin Pract* 2004;63:27-35.
16. Stockl K, Ory C, Vanderplas A, Nicklasson L, Lyness W, Cobden D, Chang E: An evaluation of patient preference for an alternative insulin delivery system compared to standard vial and syringe. *Curr Med Res Opin* 2007;23:133-146.

17. Sommerfeldt E, Oygard R, Sander J, Jervell J: Novopen: a useful aid also for blind diabetic patients. *Diabetes Care* 1989;12:306–307.
18. Asakura T, Seino H: Assessment of dose selection attributes with audible notification in insulin pen devices. *Diabetes Technol Ther* 2005;7:620–626.
19. Brunton S: Initiating insulin therapy in type 2 diabetes: benefits of insulin analogs and insulin pens. *Diabetes Technol Ther* 2008;10:247–256.

Address correspondence to:

*Yasuo Terauchi, M.D., Ph.D.*

*Department of Endocrinology and Metabolism*

*Yokohama City University Graduate School of Medicine*

*3-9 Fuku-ura*

*Kanazawa-ku, Yokohama 236-0004, Japan*

*E-mail: terauchi@yokohama-cu.ac.jp*