

Neurol Med Chir (Tokyo) 50, 399 ~ 401, 2010

**Spontaneous Epidural Hematoma
Secondary to Sphenoid Sinusitis**
—Case Report—

Yoshinobu TAKAHASHI, Naoya HASHIMOTO*, and Akihiko HINO**

Department of Neurosurgery, Hokuto Hospital, Obihiro, Hokkaido;

**Department of Neurosurgery, Osaka University Medical School, Suita, Osaka;*

***Department of Neurosurgery, Saiseikai Shiga Hospital, Ritto, Shiga*

Abstract

Epidural hematoma is typically caused by direct head trauma. Spontaneous epidural hematoma can be caused by infections of adjacent regions, vascular malformations of the dura mater, and disorders of blood coagulation. A 10-year-old girl with no history of head injury presented with complaints of headache and fever. On arrival at our hospital, her Glasgow Coma Scale score was 13 and neurological examination revealed right oculomotor palsy and left hemiparesis. Computed tomography (CT) showed an epidural hematoma in the right temporal base. Preoperative angiography identified no specific vascular lesions. Removal of the hematoma was undertaken immediately. Retrospective evaluation of the preoperative CT revealed sphenoid sinusitis and a bone defect between the temporal base and the sphenoid sinus. The epidural hematoma was probably caused by the spread of inflammation from the sphenoid sinus. Sphenoid sinusitis is one of the possible causes of acute epidural hematoma, especially if no traumatic episodes or risk factors can be identified.

Key words: sphenoid sinusitis, spontaneous epidural hematoma

Received May 28, 2009; Accepted September 25, 2009

Neurol Med Chir (Tokyo) 50, May, 2010

Introduction

Epidural hematoma is generally a direct sequela of head injury. Spontaneous epidural hematoma can arise from various other pathological conditions, including dural vascular lesions, disorders of coagulation, and infections of adjacent regions. Epidural hematoma occurring as a complication of paranasal sinusitis is very rare. We report a case of spontaneous epidural hematoma secondary to sphenoid sinusitis in a child.

Case Report

A 10-year-old girl with no history of head trauma suffered sudden onset of headache and high fever. She became drowsy and was brought to the hospital. Her Glasgow Coma Scale score on arrival at the hospital was 13. Neurological examination revealed oculomotor palsy on the right side and left hemiparesis. Emergent computed tomography (CT) showed an epidural hematoma at the

right temporal base with marked midline shift (Fig. 1). Routine blood examination revealed no evidence of any coagulation disorder. Subsequent internal and external carotid angiography revealed no specific vascular lesions. Immediate surgery was undertaken to remove the epidural hematoma. The source of the bleeding could not be identified. Postoperative angiography also failed to reveal any lesions. Retrospective evaluation of the preoperative CT and postoperative magnetic resonance imaging demonstrated fluid collection in the sphenoid sinus, consistent with the diagnosis of sinusitis. The bone window CT images also showed a bone defect between the temporal base and the sphenoid sinus (Fig. 2). We suspected that the epidural hematoma was caused by spread of inflammation from the sphenoid sinus. The patient was successfully treated with antibiotics, recovered well, and was discharged with no neurological deficits.

Discussion

Review of 80 cases of intracranial arteriovenous malformations encountered during a 7-year period concluded that dural arteriovenous fistulas (AVFs) accounted for 6.25% of all such cases.⁶⁾ In general, vascular malformations tend to bleed into the subarachnoid or subdural space. Only one case of epidural hematoma caused by dural AVF has been reported.³⁾ In our patient, neither pre- or postoperative angiography detected vascular malformations of the dura mater, nor were such malformations observed during surgery. Intracranial hemorrhage may also be caused by coagulopathies. Among 124 cases of intracranial hemorrhage in patients receiving anticoagulant therapy, the bleeding was subdural in 82% and intracerebral in 18%, whereas epidural bleeding was not observed.⁷⁾ In the present case, there was no evidence of bleeding diathesis.

Infections of adjacent regions including otitis, orbital cellulites, and paranasal sinusitis are also associated with the development of epidural hematoma. The first case of spontaneous epidural hematoma associated with sinusitis was reported in 1968.⁵⁾ Nine cases of paranasal sinusitis associated with epidural hematoma have been reported (Table 1). Some mechanisms have been proposed to explain the formation of epidural hematoma associated with infections of adjacent regions. The infection may extend from the primary site through diploic vascular channels resulting in arteritis and subsequent rupture of the meningeal vessel wall.⁵⁾ Alternatively, granulation tissue may erode through bone, with spontaneous hemorrhage occurring secondary to infarction of the tissue trapped by the bone edges.³⁾ Intraoperative findings in a case of thrombosed diploic vessels were consistent with the former mechanism.⁴⁾ However, numerous studies have confirmed the presence of bone destruction during surgery consistent with the second mechanism.^{1,5,8)}

In our case, head CT had clearly delineated the sinusitis and also the bone defect between the right temporal base and the sphenoid sinus, although we failed to notice these findings preoperatively. The risk is that the dura mater may become progressively stripped from the inner table of

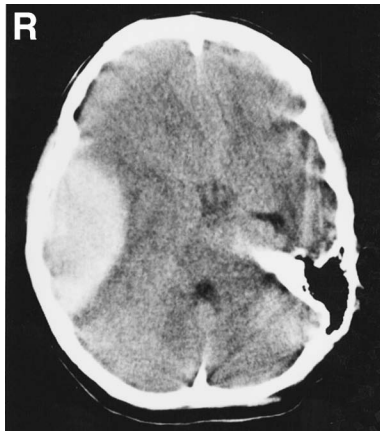

Fig. 1 Computed tomography scan on admission showing an epidural hematoma in the right middle fossa, with marked midline shift.

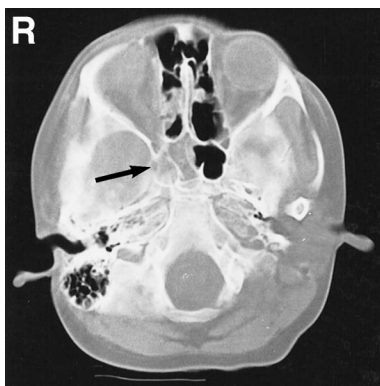


Fig. 2 Bone window computed tomography scan on admission showing a bone defect between the temporal base and the sphenoid sinus (arrow).

Table 1 Reported cases of epidural hematoma associated with paranasal sinusitis

Author (Year)	Age (yrs)	Sex	Sinus	Location of the hematoma	Surgery	Outcome
Kelly and Smith (1968) ⁹⁾	11	M	frontal	lt frontal	done	good
Rajput and Rzdilsky (1971) ¹¹⁾	18	M	frontal	lt frontal	no	dead
Marks and Shaw (1982) ⁸⁾	31	M	frontal	rt frontal	done	good
Ataya (1986) ¹⁾	31	M	frontal	lt frontal	done	good
Sakamoto et al. (1997) ¹²⁾	16	F	maxillary	lt frontal	done	good
Papadopoulos et al. (2001) ¹⁰⁾	17	M	frontal	rt frontal	done	good
Griffiths et al. (2002) ⁴⁾	17	M	pansinusitis	lt frontal	done	good
Moonis et al. (2002) ⁹⁾	21	M	sphenoid	lt temporal	done	good
Chaiyasate et al. (2007) ²⁾	14	M	pansinusitis	rt frontal	done	good
Present case	10	F	sphenoid	rt temporal	done	good

the skull by extension of pus, exudates, and air.^{1,2,4,5,8-12)} In our patient, the inflammation probably spread through the bone defect to cause local arteritis and rupture of the blood vessels, and progressive detachment of the dura mater led to recurrent bleeding and the formation of the epidural hematoma.

Epidural hematoma may show rapid onset in some cases, but progress more slowly in others. In our case, the epidural hematoma was formed at the temporal base, and the infection spread directly from the sphenoid sinus, which led to rapid progression and impending tentorial herniation. All cases reported until date (including the present case) have occurred in patients younger than 31 years. This may be related to the increased adherence of the dura mater to the inner surface of the skull that occurs with advancing age.

The present case illustrates that paranasal sinusitis is one of the possible causes of acute epidural hematoma, particularly in younger patients, especially in the absence of history of trauma or other identifiable risk factors.

References

- Ataya NL: Extradural hematoma secondary to chronic sinusitis: A case report. *J Laryngol Otol* 100: 951-953, 1986
- Chaiyasate S, Halewyck S, Van Rompaey K, Clement P: Spontaneous extradural hematoma as a presentation of sinusitis: Case report and literature review. *Int J Pediatr Otorhinolaryngol* 71: 827-830, 2007
- Gallagher JP, Browder EJ: Extradural hematoma: Experience with 167 patients. *J Neurosurg* 29: 1-12, 1968
- Griffiths SJ, Jatavallabhula NS, Mitchell RD: Spontaneous extradural haematoma associated with craniofacial infections: case report and review of the literature. *Br J Neurosurg* 16: 188-191, 2002
- Kelly DL Jr, Smith JM: Epidural hematoma secondary to frontal sinusitis: Case report. *J Neurosurg* 28: 67-69, 1968
- Kune Z, Bret J: Congenital arterio-sinusal fistulae. *Acta Neurochir (Wien)* 20: 85-103, 1969
- Lizuka J: Intracranial and intraspinal haematomas associated with anticoagulant therapy. *Neurochirurgia (Stuttg)* 15: 15-25, 1972
- Marks SM, Shaw MDM: Spontaneous intracranial extradural hematoma. Case report. *J Neurosurg* 57: 708-709, 1982
- Moonis G, Granados A, Simon SL: Epidural hematoma as a complication of sphenoid sinusitis and epidural abscess. A case report and literature review. *Clin Imaging* 26: 382-385, 2002
- Papadopoulos MC, Dyer A, Hardwidge C: Spontaneous extradural hematoma with sinusitis. A case report. *J R Soc Med* 94: 588-589, 2001
- Rajput AJ, Rzdilsky B: Extradural hematoma following frontal sinusitis. Report of case and review of literature. *Arch Otolaryngol Head Neck Surg* 94: 83-86, 1971
- Sakamoto T, Harimoto K, Inoue S, Konishi A: Extradural hematoma following maxillary sinusitis. Case illustration. *J Neurosurg* 87: 132, 1997

Address reprint requests to: Yoshinobu Takahashi, M.D., Department of Neurosurgery, Hokuto Hospital, 7-5 Inada, Obihiro, Hokkaido 080-0039, Japan.
e-mail: yosinobu@hokuto7.or.jp