

# Synchronous Multifocal Osteosarcoma Involving the Skull Presenting With Intracranial Hemorrhage

## —Case Report—

Hikari SATO, Nakamasa HAYASHI, Hiromichi YAMAMOTO, Shoichi NAGAI, Kazuo OHMORI\*, Masahiko KANAMORI\*, and Shunro ENDO

Departments of Neurosurgery and \*Orthopedics, Faculty of Medicine, University of Toyama, Toyama

### Abstract

A 40-year-old man presented with a rare case of synchronous multifocal osteosarcoma involving the skull associated with intracerebral hemorrhage, manifesting as sudden headache and left homonymous hemianopia. Computed tomography revealed a skull tumor in the right occipital bone and intracerebral hemorrhage in the right occipital lobe. Gross total resection of the skull tumor with hematoma was performed. The histological diagnosis was osteosarcoma. The tumor cells had invaded into the surrounding brain parenchyma, resulting in intracerebral hemorrhage.

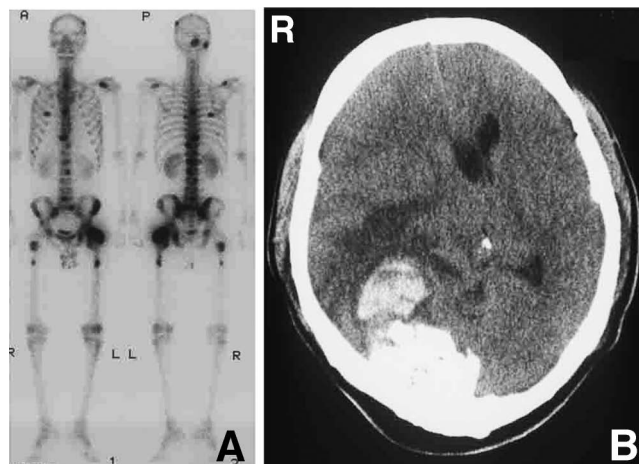
Key words: brain invasion, intracerebral hemorrhage, intracranial hemorrhage, multifocal osteosarcoma, skull tumor

### Introduction

Osteosarcoma is the most common primary malignant neoplasm of bone and can occur anywhere in the body, but is most commonly found in the long bones, especially around the knee. Synchronous multifocal osteosarcoma, a rare variant of osteosarcoma, is described as the simultaneous appearance of two or more tumors at any site in the peripheral or axial skeleton.<sup>7,8,10,11,14,15,18,22,25</sup> We present a case of synchronous multifocal osteosarcoma involving the skull presenting with intracerebral hemorrhage.

### Case Report

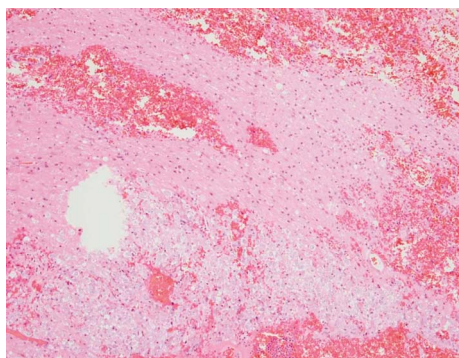
A 40-year-old man presented with a 4-month history of low back pain. Vertebral magnetic resonance imaging demonstrated multiple extradural lesions compressing the spinal cord. Gallium systemic bone scintigraphy revealed multiple regions of hyperaccumulation in the skeleton including the skull (Fig. 1A). Computed tomography (CT) of the chest and abdomen found no abnormalities. Biopsy of the dominant lesion in the left femur was performed and revealed a lesion consistent with an osteoblastic osteosarcoma. The diagnosis was type II synchronous multifocal osteosarcoma. The patient was treated with 2 cycles of chemotherapy with methotrexate, adriamycin, and cisplatin in the Department of Orthopedics in our hospital. Four months later, the patient complained of sudden headache and left homonymous hemianopia. Head CT revealed a



**Fig. 1** A: Gallium systemic bone scintigrams revealing multiple regions of hyperaccumulation in the skeleton including the skull. B: Computed tomography scan showing a skull tumor in the right occipital bone and intracerebral hemorrhage in the right occipital lobe.

tumor of the skull in the right occipital bone and intracerebral hemorrhage in the right occipital lobe (Fig. 1B). Cerebral digital subtraction angiography revealed no vascular abnormalities such as arteriovenous malformation or cerebral aneurysm.

The patient underwent a right occipital craniotomy under general anesthesia in the prone position. A horseshoe-shaped skin incision was created in the occipital region.



**Fig. 2** Photomicrograph of the brain tissue surrounding the tumor showing large tumor cells with eosinophilic cytoplasm, ill-defined contours, and prominent nucleoli have invaded the surrounding brain parenchyma with intracerebral hemorrhage. Hematoxylin and eosin stain, original magnification  $\times 40$ .

Protuberance of the occipital bone was recognized, and osteoclastic craniectomy was performed around this lesion. The lesion had penetrated through the dura mater and into the brain tissue. The dura mater around the tumor was circumferentially cut, and the tumor was removed with the surrounding brain tissue and hematoma. The tumor was about  $6 \times 6 \times 4$  cm in size with a smooth surface. Histological examination revealed tumor cells with eosinophilic cytoplasm, ill-defined contours, and prominent nucleoli had invaded the surrounding brain parenchyma with intracerebral hemorrhage consistent with an osteoblastic osteosarcoma of the skull (Fig. 2).

Postoperatively, the patient's headache disappeared, but left homonymous hemianopia persisted and was unchanged. Two weeks after the craniotomy, he underwent laminectomy of the lumbosacral spine (L5–S1) for relief of pain of the lower extremities. Thereafter, he was treated conservatively and died approximately 14 months after the diagnosis of synchronous multifocal osteosarcoma. Autopsy was not performed.

## Discussion

Primary osteosarcoma of the skull is rare.<sup>4,5,12,23</sup> The most common complaint associated with this type of tumor is a growing protuberance on the head that may or may not be tender.<sup>5</sup> The cranial vault is affected more often than the base of the skull.<sup>20</sup> Previously reported cases include three of primary osteosarcoma involving the skull combined with intracranial hemorrhage.<sup>1,23,26</sup> One case of primary osteosarcoma of the temporal skull base was combined with subdural hematoma.<sup>23</sup> The tumor was firm and rigidly adherent to the dura in the middle cranial fossa. The extradural tumor was totally excised but the subdural hematoma could not be completely removed because of tight adhesion to the brain. Histological examination showed that tumor cells were present in the subdural hematoma. The tumor recurred after initial surgical intervention and chemotherapy, and the patient died 15 months after diagnosis. Another case of primary osteosarcoma of the tem-

poral fossa was treated by radical excision of a tumor of the skull base.<sup>1</sup> Histological examination found no evident parenchymal invasion. The patient was alive and without evidence of disease 8 months after presentation but died shortly thereafter of complications related to adjuvant therapy. A case of intracranial osteosarcoma occurred at the site of previous radiosurgery.<sup>21</sup> Cerebral hemorrhage occurred in the peritumoral region. The tumor and surrounding hematoma were completely excised. Parenchymal invasion was not present. The patient underwent adjuvant combination chemotherapy consisting of high-dose methotrexate, doxorubicin, and cisplatin, and was alive without evidence of disease 12 months after diagnosis.

Synchronous multifocal osteosarcoma is a rare condition, with a reported incidence of 1 to 3%.<sup>7,11</sup> Multifocal osteosarcoma may be an unusual form of osteosarcoma with rapid metastasis, regardless of the presence of pulmonary metastases, and usually presents as one dominant lesion and multiple small lesions.<sup>8,10,18</sup> Metastasis via the vertebral venous plexus system may be a plausible mechanism of bone-to-bone metastasis without evidence of pulmonary metastasis.<sup>7,9,15</sup>

Multifocal osteosarcoma can be classified according to histology, patient age, and time at presentation of multiple osseous lesions.<sup>2</sup> Type I patients are less than 18 years of age, with multiple histologically anaplastic osseous lesions appearing within 5 months of the initial presentation. Type II patients are older than 18 years of age, and present with multiple osseous lesions that are histologically well differentiated. Type IIIA and IIIB represent categories of metastatic disease, with patients presenting with secondary lesions 5 months or more after the initial presentation.

Synchronous multifocal osteosarcoma involving the skull is relatively rare.<sup>6,10,13,15–19,22,24,25</sup> A study of skeletal distribution of secondary foci of multifocal osteosarcoma found 5 of 175 secondary lesions (3%) involved the skull in 29 cases of multifocal osteosarcoma.<sup>10</sup> The present case was synchronous multifocal osteosarcoma involving the calvarium and manifesting as intracerebral hemorrhage. Histological examination revealed tumor cells present in the surrounding brain tissue.

Brain metastases have been reported in 5.7% of patients with a diagnosis of osteosarcoma with lung metastasis.<sup>3</sup> The clinical presentation in such cases tends to be acute and catastrophic, necessitates emergency management, and is associated with major morbidity. Since the present patient had no evidence of lung metastasis, we speculated that the skull tumor had invaded the surrounding brain tissue through the dura mater.

The prognosis for patients with synchronous multifocal osteosarcoma is very poor.<sup>7,10,14,15,18</sup> The mean survival of type I patients is 6 months, and that of type II patients is between 5 months and 4 years.<sup>2,8,15</sup> Pulmonary metastases are considered to be one of the major factors affecting the prognosis of unifocal osteosarcoma and multifocal osteosarcoma.<sup>22</sup> The present patient died 14 months after the diagnosis of type II synchronous multifocal osteosarcoma, despite surgical intervention and chemotherapy. In-

tradural involvement may have been another important prognostic factor.

### References

- 1) Alleyne CH Jr, Theodore N, Spetzler RF, Coons SW: Osteosarcoma of the temporal fossa with hemorrhagic presentation: case report. *Neurosurgery* 47: 447-451, 2000
- 2) Amstutz HC: Multiple osteogenic sarcomata: metastatic or multicentric? *Cancer* 24: 923-931, 1969
- 3) Baram TZ, van Tassel P, Jaffe NA: Brain metastases in osteosarcoma: incidence, clinical and neuroradiological findings and management options. *J Neurooncol* 6: 47-52, 1988
- 4) Benson JE, Goske M, Han JS, Brodkey JS, Yoon YS: Primary osteogenic sarcoma of the calvaria. *AJNR Am J Neuroradiol* 5: 810-813, 1984
- 5) Bose B: Primary osteogenic sarcoma of the skull. *Surg Neurol* 58: 234-240, 2002
- 6) Chap LI, Mirra J, Ippolito V, Rentschler R, Rosen P: Miliary osteosarcomatosis with associated hypocalcemia. *Am J Clin Oncol* 20: 505-508, 1997
- 7) Currall VA, Dixon JH: Synchronous multifocal osteosarcoma: case report and literature review. *Sarcoma* 2006: 53901, 2006
- 8) Daffner RH, Kennedy SL, Fox KR, Crowley JJ, Sauser DD, Cooperstein LA: Synchronous multicentric osteosarcoma: the case for metastases. *Skeletal Radiol* 26: 569-578, 1997
- 9) Enneking WF, Kagen A: "Skip" metastases in osteosarcoma. *Cancer* 36: 2192-2205, 1975
- 10) Hopper KD, Moser RP, Haseman DB, Sweet DE, Madewell JE, Kransdorf MJ: Osteosarcomatosis. *Radiology* 175: 233-239, 1990
- 11) Jones RD, Reid R, Balakrishnan G, Barrett A: Multifocal synchronous osteosarcoma: the Scottish Bone Tumour Registry experience. *Med Pediatr Oncol* 21: 111-116, 1993
- 12) Kanazawa R, Yoshida D, Takahashi H, Matsumoto K, Teramoto A: Osteosarcoma arising from the skull: case report. *Neurol Med Chir (Tokyo)* 43: 88-91, 2003
- 13) Lam KS, Wu PC, Chan FL, Pang SW, Pan HY: Multicentric sclerosing osteosarcoma: a rare cause of cranial nerve palsy. *Clin Oncol* 10: 281-287, 1984
- 14) Longhi A, Fabbri N, Donati D: Neoadjuvant chemotherapy for patients with synchronous multifocal osteosarcoma: results in eleven cases. *J Chemother* 13: 324-330, 2001
- 15) Mahoney JP, Spanier SS, Morris JL: Multifocal osteosarcoma: a case report with review of the literature. *Cancer* 44: 1897-1907, 1979
- 16) Moseley JE, Bass MH: Sclerosing osteogenic sarcomatosis: a radiologic entity. *Radiology* 66: 41-44, 1956
- 17) Nerlich AG, Brenner RE, Muller PK, Remberger K: Multifocal osteogenic sarcoma of the skull in a patient who had congenital hyperphosphatasemic skeletal dysplasia: a case report. *J Bone Joint Surg Am* 74: 1090-1095, 1992
- 18) Parham DM, Pratt CB, Parvey LS, Webber BL, Champion J: Childhood multifocal osteosarcoma: clinicopathologic and radiologic correlates. *Cancer* 55: 2653-2658, 1985
- 19) Price CH, Truscott DE: Multifocal osteogenic sarcoma; report of a case. *J Bone Joint Surg Br* 39-B: 524-533, 1957
- 20) Salvati M, Ciappetta P, Raco A: Osteosarcomas of the skull: clinical remarks on 19 cases. *Cancer* 71: 2210-2216, 1993
- 21) Sanno N, Hayashi S, Shimura T, Maeda S, Teramoto A: Intracranial osteosarcoma after radiosurgery: case report. *Neurol Med Chir (Tokyo)* 44: 29-32, 2004
- 22) Sato J, Himi T, Tamakawa M: Osteosarcomatosis involving craniofacial bones presenting with cranial nerve palsies. *J Laryngol Otol* 114: 214-217, 2000
- 23) Shinoda J, Kimura T, Funakoshi T, Iwata H, Tange K, Kasai C, Miyata Y: Primary osteosarcoma of the skull: a case report and review of the literature. *J Neurooncol* 17: 81-88, 1993
- 24) Silverman G: Multiple osteogenic sarcoma. *Arch Pathol* 21: 88-95, 1936
- 25) Soltani A, Hasani-Ranjbar S, Moayyeri A: Hypocalcemia as a presentation for multifocal osteosarcoma. *Pediatr Blood Cancer* 50: 687-689, 2008
- 26) Tsuji N, Iwamoto M, Nakakita K, Kuriyama T, Shizuki K: [Primary osteogenic sarcoma of the skull base: report of a case]. *Gan No Rinsho* 28: 1735-1739, 1982 (Jpn)

---

Address reprint requests to: Nakamasa Hayashi, M.D., Department of Neurosurgery, Faculty of Medicine, University of Toyama, 2630 Sugitani, Toyama 930-0194, Japan.  
e-mail: nakamasa@iwa.att.ne.jp