

MRI-based thrombolysis in patients with stroke with minor aphasia

CASES SUMMARY

We report two men (aged 39 and 63 years) presenting with a mild, isolated limitation of conversation about provided materials without obvious comprehension impairment (National Institutes of Health Stroke Scale (NIHSS) score: 1). Both patients underwent magnetic resonance angiography (MRA), diffusion and perfusion weighted imaging on admission. MRI revealed limited lesions on diffusion imaging involving Wernicke (patient 1) and Broca (patient 2) areas with a significant diffusion/perfusion mismatch, although no obvious arterial occlusion was visible on MRA (figure 1). Recovery was complete in both patients after intravenous t-PA given within 3 h of onset.

COMMENT

Many patients presenting with minor symptoms are denied angiographic and perfusion imaging as well as thrombolysis, despite an uncertain outcome.¹ In a prospective study, a third of such patients died or were left dependent.² Our patients showed only mild aphasia with a low NIHSS score of 1. As most patients with intracranial occlusion demonstrate low to moderate NIHSS scores,³ no reliable lower threshold can be used for treatment decisions. Thus, a comprehensive neurovascular imaging is required in patients with acute stroke to assess the true severity of underlying haemodynamic and tissular abnormalities. As illustrated here, perfusion imaging can be used to confirm distal clots that may be missed on MRA.

The present cases further illustrate that clinical criteria alone may prove misleading for acute stroke management. All acute patients with minor symptoms should be emergently assessed for intracranial arterial occlusion and treated accordingly. Patients with mild aphasia and low NIHSS scores

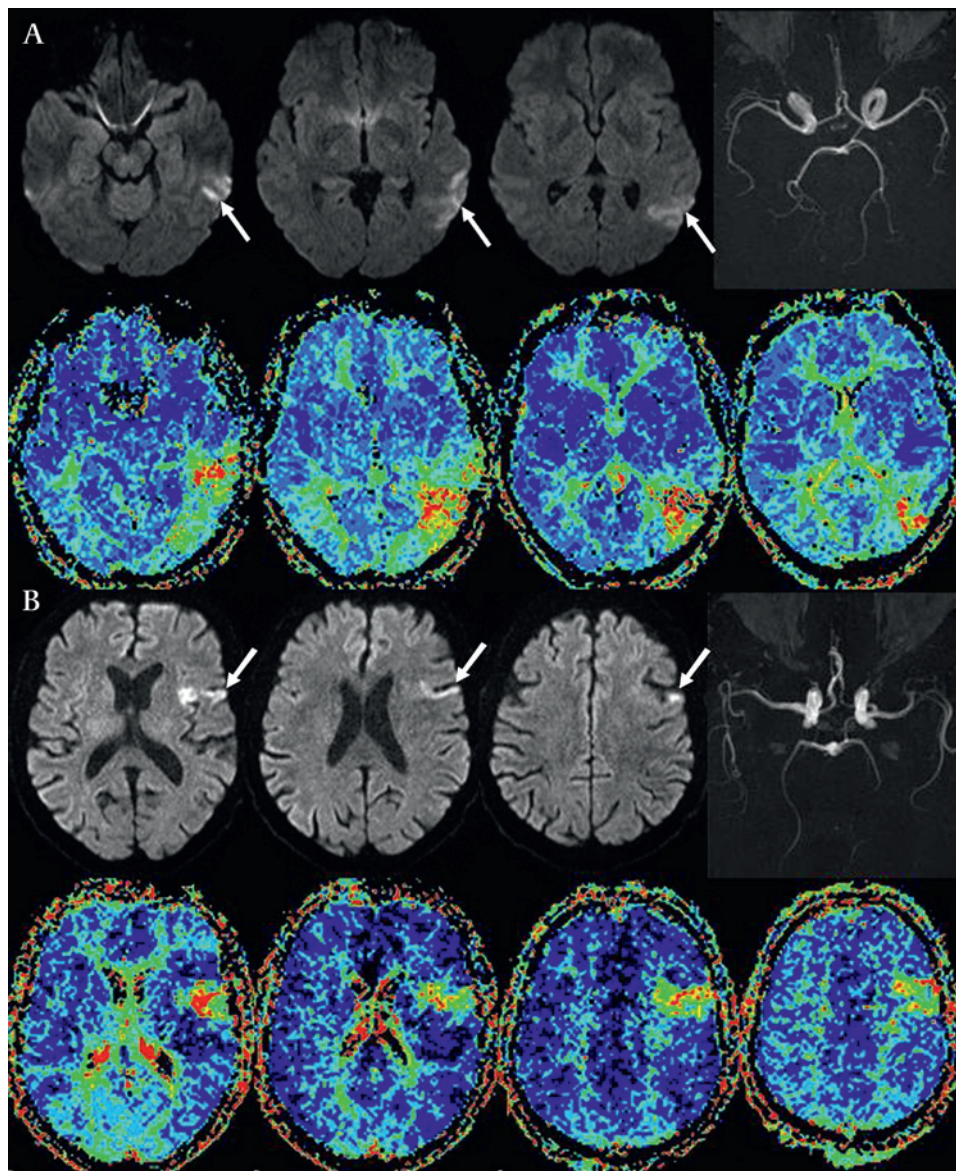


Figure 1 (A) Patient 1: 39-year-old man with Wernicke area lesion on diffusion-weighted-imaging (DWI, arrows). (B) Patient 2: 63-year-old man with Broca area involvement on DWI (arrows). Both patients showed a significant DWI perfusion (time-to-peak maps) mismatch on MRI, prompting intravenous thrombolysis despite minor isolated aphasia. Perfusion imaging confirmed in both patients a distal branch occlusion of the left middle cerebral artery not readily visible on MRA.

Neurological picture

who have a mismatch even in the absence of obvious arterial occlusion should be offered reperfusion therapies, as their natural course carries a significant risk of deterioration. Intravenous t-PA appears to be safe and effective in these patients.⁴

T H Cho,^{1,2} M Hermier,^{2,3} N Nighoghossian^{1,2}

¹Hospices Civils de Lyon, Cerebrovascular Unit, Hôpital Pierre Wertheimer, Lyon, France; ²Université de Lyon, Lyon 1, CNRS, UMR 5220, INSERM, U630, INSA de Lyon, Creatis-LRMN, Lyon, France; ³Hospices Civils de Lyon, Neuroradiology Department, Hôpital Pierre Wertheimer, Lyon, France

Correspondence to Professor N Nighoghossian, Hospices Civils de Lyon, Cerebrovascular Unit, Hôpital Pierre Wertheimer, 59, Bv Pinel, 69003 Lyon, France; norbert.nighoghossian@chu-lyon.fr

Competing interests None.

Patient consent Obtained.

Contributors All authors contributed equally to data acquisition and analysis as well as manuscript preparation and review.

Provenance and peer review Not commissioned; externally peer reviewed.

Accepted 3 December 2009

Published Online First 14 June 2010

J Neurol Neurosurg Psychiatry 2010;**81**:1215–1216. doi:10.1136/jnnp.2009.200386

REFERENCES

1. **Smith EE**, Abdullah AR, Petkovska I, *et al*. Poor outcomes in patients who do not receive intravenous tissue plasminogen activator because of mild or improving ischemic stroke. *Stroke* 2005;**36**:2497–9.
2. **Barber PA**, Zhang J, Demchuk AM, *et al*. Why are stroke patients excluded from tPA therapy? An analysis of patient eligibility. *Neurology* 2001;**56**:1015–20.
3. **Maas MB**, Furie KL, Lev MH, *et al*. National institutes of health stroke scale score is poorly predictive of proximal occlusion in acute cerebral ischemia. *Stroke* 2009;**40**:2988–93.
4. **Kruetzelmann A**, Siemonsen S, Gerloff C, *et al*. Thrombolysis targeting MRI defined tissue at risk in minor stroke. *J Neurol Neurosurg Psychiatry* 2009;**80**:1156–8.



MRI-based thrombolysis in patients with stroke with minor aphasia

T H Cho, M Hermier and N Nighoghossian

J Neurol Neurosurg Psychiatry 2010 81: 1215-1216 originally published online June 14, 2010

doi: [10.1136/jnp.2009.200386](https://doi.org/10.1136/jnp.2009.200386)

Updated information and services can be found at:

<http://jnp.bmj.com/content/81/11/1215>

These include:

References

This article cites 4 articles, 4 of which you can access for free at:

<http://jnp.bmj.com/content/81/11/1215#BIBL>

Email alerting service

Receive free email alerts when new articles cite this article. Sign up in the box at the top right corner of the online article.

Topic Collections

Articles on similar topics can be found in the following collections

[Stroke](#) (1353)
[Radiology](#) (1623)
[Radiology \(diagnostics\)](#) (1223)

Notes

To request permissions go to:

<http://group.bmj.com/group/rights-licensing/permissions>

To order reprints go to:

<http://journals.bmj.com/cgi/reprintform>

To subscribe to BMJ go to:

<http://group.bmj.com/subscribe/>