

Proposal for bail-out procedures - Carotid and imaging Carotid stent removal of symptomatic plaque protrusion after carotid angioplasty stenting

Emanuele Ferrero*, Michelangelo Ferri, Andrea Viazzo, Franco Nessi

Vascular and Endovascular Surgery Unit, Mauriziano Umberto I Hospital, Largo Turati 62, 10128 Turin, Italy

Received 30 April 2010; received in revised form 24 May 2010; accepted 28 May 2010

Abstract

We treated two patients with asymptomatic high grade internal carotid artery stenosis, by carotid artery stenting (CAS) with embolus protection filters 75% and 70%, respectively (North American Symptomatic Carotid Endarterectomy criteria). The immediate cranial and carotid angiogram showed a good result with regular patency of carotid and cerebral vessels. In both cases, the CAS procedure was complicated with symptomatic embolism, in one case 6 h after CAS and the other one occurring after seven days. The duplex scan (DS) control revealed the presence of plaque protrusion intra-stent in both cases. An early treatment with stent removal and carotid surgery was performed <24 h after the presenting symptoms (in one case a standard endarterectomy in the other and a carotid bypass was performed). Both patients were discharged without neurological deficit. At neurological follow-up at 30 days the patients were in good general condition without neurological symptoms or deficit and the DS follow-up at 30 days and six to 12 months show the patency of carotid vessels. These two cases demonstrate that plaque protrusion is a possible complication of CAS, where symptoms which may occur either immediately or later and can be managed successfully with urgent surgical intervention of carotid stent removal.

© 2010 Published by European Association for Cardio-Thoracic Surgery. All rights reserved.

Keywords: Carotid artery stenting; Carotid stent removal; Carotid endarterectomy; Plaque protrusion; Cerebral embolism; Transient ischemic attack

In recent years carotid artery stenting (CAS) has become a safe and effective alternative to carotid endarterectomy (CEA) to treat severe internal carotid artery (ICA) stenosis to prevent future ischemic stroke. In the literature cases of acute or subacute in-stent restenosis, a CAS complication that occurs in 0.04–2%, that can cause severe neurological deficits are described [1, 2]. In acute in-stent restenosis usually caused by thrombosis or due to plaque protrusion, the cause of restenosis is difficult to distinguish by angiography or Duplex ultrasound scanning (DS) [3]. In our series of 247 CAS performed between 1 January 2007 and 31 December 2008, we observed two cases of symptomatic embolism after CAS placement. Two patients (73-year-old female and 77-year-old male) with fibrotic plaque determining asymptomatic left ICA stenosis, 75% [peak systolic velocity (PSV): 165 cm/s; end diastolic velocity (EDV): 67 cm/s] and 70% (PSV: 295 cm/s; EDV: 95 cm/s), at DS [North American Symptomatic Carotid Endarterectomy (NASCET) criteria], respectively, underwent angio-magnetic resonance (MR) scan, that confirmed the stenosis. Both patients presented risk factors: ex-smokers, hypertension and dyslipidemia; the male also presented: chronic obstructive pulmonary disease (COPD), mild chronic renal failure (CRF) (creatinine 2 mg/dl) and a past episode of anginous chest pain. Patients underwent CAS with an embolic protection device (EPD): in the female, after positioning the EPD EPI-Filterwire EZ™ (Boston Scientific, Natick, MA, USA)

an open cell CAS (Precise-Pro-Rx Nitinol 8×30 mm – Cordis/Johnson&Johnson, Warren, NJ, USA) was placed; in the male, after positioning the EPD Spider FX (ev3, Plymouth, MN, USA), a closed-cell CAS (Wallstent 7×40 mm – Boston Scientific) was placed. In both cases, the post procedure angiography showed a good result of stent placement with carotid patency without signs of plaque protrusion. In the female patient, an episode of aphasia and modest deficit of the right hand, occurred three times after CAS (one after 6 h, one after 14 h and one after 24 h) this regressed in few minutes. The cerebral computed tomography (CT) scan performed (MR was not available) was negative for ischemic or hemorrhagic cerebral lesion. The DS showed patency of the ICA, and an absence of thrombosis or dissection, right stent placement with evidence of plaque protrusion between the stent struts (Fig. 1). The male patient was discharged one day after CAS in the absence of neurological or general complications; after seven days he returned due to a sudden episode of amaurosis fugax in the left eye. The DS showed the carotid stent patency with plaque protrusion across the stent (Video 1). The patients underwent surgery under general anaesthesia; the heparin was administered before carotid clamping (70 UI/kg i.v.) and was not reversed. Intraoperatively, in the gross pathological we found plaque protrusion through the stent in the absence of associated thrombus (Fig. 2). After stent removal we performed a carotid–carotid by-pass with a 6-mm polytetrafluoroethylene (PTFE) in the female patient (the plaque extended high into the ICA, the distal endpoint

*Corresponding author. Tel.: +39-11-5082605; fax: +39-11-5082606.

E-mail address: emaferrero@libero.it (E. Ferrero).

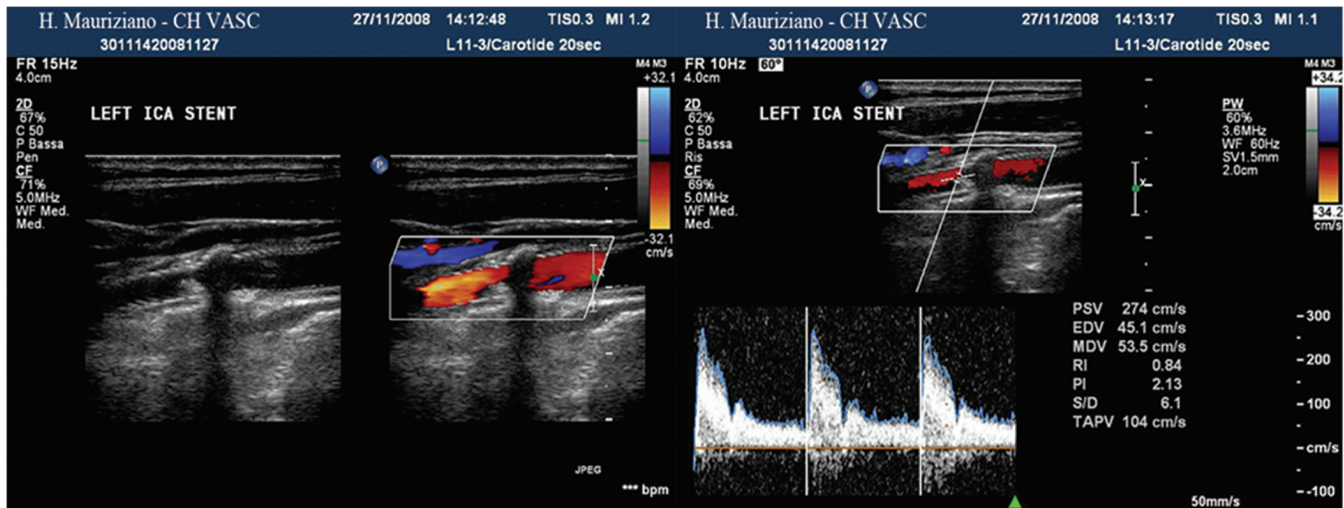
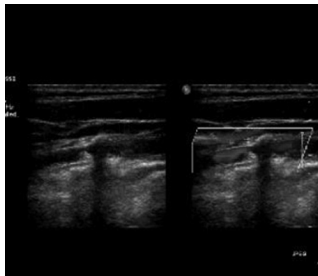


Fig. 1. Duplex scan of plaque protrusion intrastent.



Video 1. Carotid stent patency with plaque protrusion across the stent.

could not be adequately visualized and an adequate intemectomy could not be done), in this case we used the Pruitt–Inahara shunt because the stump pressure was ≤ 30 mmHg (cerebral ischemic time during surgery: 5, 1 and 3 min); in the male patient a CEA with direct suture was performed without shunt use (stump pressure: 100 mmHg), the cerebral ischemic time was 38 min. The surgical time was 180 min in one case and 85 min in the other. The peri- and postoperative course was uneventful with neurological symptoms completely regressed, the patients were discharged on the second day after surgery. At neurological follow-up at 30 days, the patients were in good general condition without neurological symptoms or deficit and the DS follow-up showed the patency of the bypass and of the carotid vessels. In the literature, to our knowledge, we found only four cases reporting plaque protrusion after CAS. Setacci et al. [4] described a case of a patient who presented with crescendo transient ischemic attack (TIA) on the second day after CAS; the DS demonstrated incomplete in-stent thrombosis due to plaque protrusion confirmed during urgent surgical procedure with stent removal and CEA. Hayashi et al. [5] described a case of plaque protrusion identified during CAS and treated by balloon angioplasty, but the patient developed right hemiparesis postoperatively, the MR showed multiple infarction in the right cerebral hemisphere; the symptom resolved seven days later. Aikawa et al. [6] reported a case in which, during CAS, the angiography after deflation of the distal

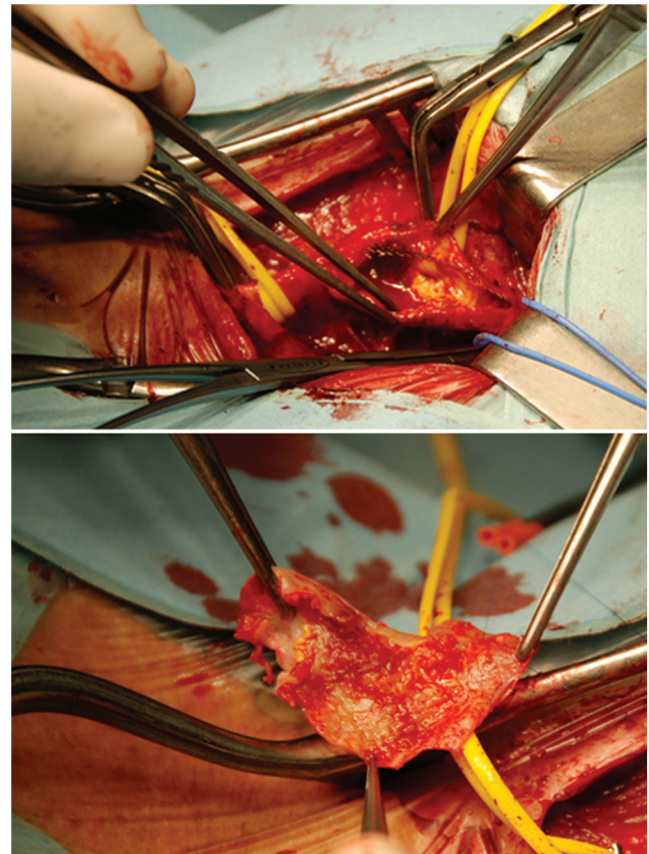


Fig. 2. Intraoperative image of carotid stent cutted and plaque protrusion.

blocking balloon demonstrated a small in-stent filling defect of the contrast medium that protruded from the anterior wall of the carotid artery; the following cranial carotid angiogram showed abrupt occlusion of the left middle cerebral artery (MCA) and the in-stent lesion had vanished in the repeat angiographic study; it was suggested that the embolus was speculated to originate in the ruptured plaque, which protruded into the stent through the

cells of the device and became liberated into the bloodstream reaching the left MCA and obliterating it. Wehman et al. [7] described a case of CAS in which an intraluminal lesion was noted in the distal aspect of the stent after poststent angioplasty, the DS characteristics of the intraluminal defect were consistent with ruptured plaque material, the angiographic runs failed to demonstrate the lesion; embolic material was noticed in the distal EPD after removal, in this case the patient did not experience any ischemic neurological symptoms. Tanemura et al. [8] described the presence of lesions in the endothelium, rupture of the fibrous cap, clots, debris detaching from plaque and stent struts detected by angioscopy during CAS. Published data regarding CAS reports that it is safe and effectiveness in stroke prevention as CEA to treat severe ICA stenosis; in our center over two years the stroke/TIA/death rate by CEA was 1.4% and the cumulative stroke/TIA/death rate after CAS was 1.1%. In the literature, we found few cases of symptomatic plaque protrusion in stent after CAS [9] that caused immediate or late cerebral embolism after CAS. As the recently reported by Müller-Hülsbeck et al. [10], the exact influence of stent design on outcome is currently unknown and the results in literature are not unequivocal. No suitable strategy for the treatment of in-stent plaque protrusion has been established. This report illustrates that in-stent plaque protrusion may occur through open-cell and closed-cell carotid stent and that it can cause neurological symptoms (TIA). Stent plaque protrusion can be successfully managed with early surgical intervention, by stent removal and CEA, without neurological deficit.

References

- [1] Bush RL, Bhama JK, Lin PH, Lumsden AB. Transient ischemic attack due to early carotid stent thrombosis: successful rescue with rheolytic thrombectomy and systemic abciximab. *J Endovasc Ther* 2003;10:870–874.
- [2] Chaturvedi S, Sohrab S, Tselis A. Carotid stent thrombosis: report of 2 fatal cases. *Stroke* 2001;32:2700–2702.
- [3] Kurisu K, Manabe H, Ihara T. [Case of symptomatic subacute in-stent thrombosis after carotid angioplasty and stenting for severe carotid stenosis]. *No Shinkei Geka* 2007;35:1001–1005.
- [4] Setacci C, de Donato G, Setacci F, Chisci E, Cappelli A, Pieraccini M, Castriota F, Cremonesi A. Surgical management of acute carotid thrombosis after carotid stenting: a report of three cases. *J Vasc Surg* 2005;42:993–996.
- [5] Hayashi K, Kitagawa N, Morikawa M, Hiu T, Morofuji Y, Suyama K, Nagata I. Case of internal carotid artery stenosis complicated with shower embolism during filter-protected carotid artery stenting. *Brain Nerve* 2009;61:83–87.
- [6] Aikawa H, Kodama T, Nii K, Tsutsumi M, Onizuka M, Iko M, Matsubara S, Etou H, Sakamoto K, Kazekawa K. Intraprocedural plaque protrusion resulting in cerebral embolism during carotid angioplasty with stenting. *Radiat Med* 2008;26:318–323.
- [7] Wehman JC, Holmes DR Jr, Ecker RD, Sauvageau E, Fahrback J, Hanel RA, Hopkins LN. Intravascular ultrasound identification of intraluminal embolic plaque material during carotid angioplasty with stenting. *Catheter Cardiovasc Interv* 2006;68:853–857.
- [8] Tanemura H, Hatazaki S, Asakura F, Kawaguchi K, Kuraishi K, Toma N, Sakaida H, Maeda M, Taki W. Angioscopic observation during carotid angioplasty with stent placement. *AJNR Am J Neuroradiol* 2005;26:1943–1948.
- [9] Takigawa T, Matsumaru Y, Kubo T, Fukuhara N, Hayakawa M, Usui M. Recurrent subacute in-stent restenosis after carotid artery stenting due to plaque protrusion. *Neurol Med Chir (Tokyo)* 2009;49:413–417.
- [10] Müller-Hülsbeck S, Preuss H, Elhöft H. CAS: which stent for which lesion. *J Cardiovasc Surg (Torino)* 2009;50:767–772.