

Case report - Thoracic non-oncologic Giant cell arteritis presenting as dysarthria and mediastinal mass

Ricard Ramos^{a,*}, Ramon Vila^b, Rosa Penin^c, Marc-Antoni Cairols^b

^aDepartment of Thoracic Surgery, Hospital Universitari de Bellvitge, L'Hospitalet de Llobregat, Barcelona, Spain

^bDepartment of Vascular Surgery, Hospital Universitari de Bellvitge, L'Hospitalet de Llobregat, Barcelona, Spain

^cDepartment of Pathology, Hospital Universitari de Bellvitge, L'Hospitalet de Llobregat, Barcelona, Spain

Received 5 April 2010; received in revised form 2 June 2010; accepted 3 June 2010

Abstract

Giant cell arteritis, Takayasu arteritis, and Horton disease are rare, idiopathic diseases that cause chronic inflammation and obliteration of large arteries, mainly the aorta and its major branches. Histological examination reveals multinucleated giant cells and clinical presentation is characterized by general symptoms and/or symptoms related to stenosis or occlusion of vessels. A case of a 50-year-old woman with neurological symptoms, cervicothoracic tumour with severe stenosis of the right subclavian artery and complete occlusion of common carotid artery is presented.

© 2010 Published by European Association for Cardio-Thoracic Surgery. All rights reserved.

Keywords: Giant cell arteritis; Mediastinal mass

1. Introduction

Giant cell arteritis (GCA) is the most common type of vasculitis affecting the elderly population. Cranial vessels are typically the most affected, and less commonly the remainder of the large arterial tree. We present a case of a 50-year-old female with dysarthria and buccal commissure deviation, without associated fever or systemic manifestations [1, 2]. In this case, vasculitis presented as a brachiocephalic artery tumour, which is infrequent and should be considered in the differential diagnosis of patients with mediastinal tumours and neurological symptoms.

2. Case report

A 50-year-old female presented at the emergency department with a second episode of dysarthria, buccal commissure deviation, perioral dysaesthesia and head instability, without associated fever or any other systemic manifestations. Her previous medical history was unremarkable except for hyperthyroidism and hysterectomy.

The physical examination revealed a blood pressure of 120/80 mmHg, heart rate of 70 bpm, and a baseline saturated oxygen (SaO₂) of 98%. Axillary temperature was 36.7 °C. Neurological examination revealed no significant data and cardiovascular auscultation showed a bruit sound in both the neck and supraclavicular regions. The right radial pulse was absent.

Complete blood count, biochemistry and coagulation findings were normal. Cranial computed axial tomography (CT) and echocardiography were also normal. Doppler ultrasound of the neck vessels revealed complete occlusion of the right common carotid artery, with a patent bifurcation and a vascularized mass affecting the brachiocephalic artery. Chest CT and magnetic angioresonance showed a 35-mm tumour surrounding the brachiocephalic artery, with severe stenosis of the right subclavian artery and completed occlusion of the common carotid artery. The tumour extended beyond the arterial walls into the mediastinum, in contact with the trachea, the right brachiocephalic vein and the thyroid gland. There was no mediastinal adenopathy or any other lesion (Fig. 1).

Based on a diagnosis of a cervicothoracic mass, a cervico-sternotomy of the manubrium was performed, revealing a fibrous mass around the brachiocephalic artery. Since intraoperative biopsy was negative for lymphoma, a total resection of the brachiocephalic artery was carried out. Revascularization of the common carotid was achieved with a polytetrafluoroethylene (PTFE) bypass graft from the ascending aorta followed by anastomosis of the subclavian artery to the PTFE bypass. The postoperative course was uneventful, with the patient recovering the right radial pulse and showing signs of Horner's syndrome.

The resected specimen consisted of a 40×30×30 mm white fibrous mass which surrounded a vascular structure. The histological examination showed partial arterial obliteration, with a dense transmural inflammatory infiltration formed by lymphocytes, macrophages, and numerous multinucleated giant cells. The infiltration was mostly located at the medial–external border, close to the fragmented

*Corresponding author. Cirugía Torácica, Hospital Universitari de Bellvitge, Feixa Llargà s/n, 08907, L'Hospitalet de Llobregat, Barcelona, Spain. Tel.: +34-93-3357011 ext. 2744; fax: +34-93-2607983.

E-mail address: ricardramos@ub.edu (R. Ramos).

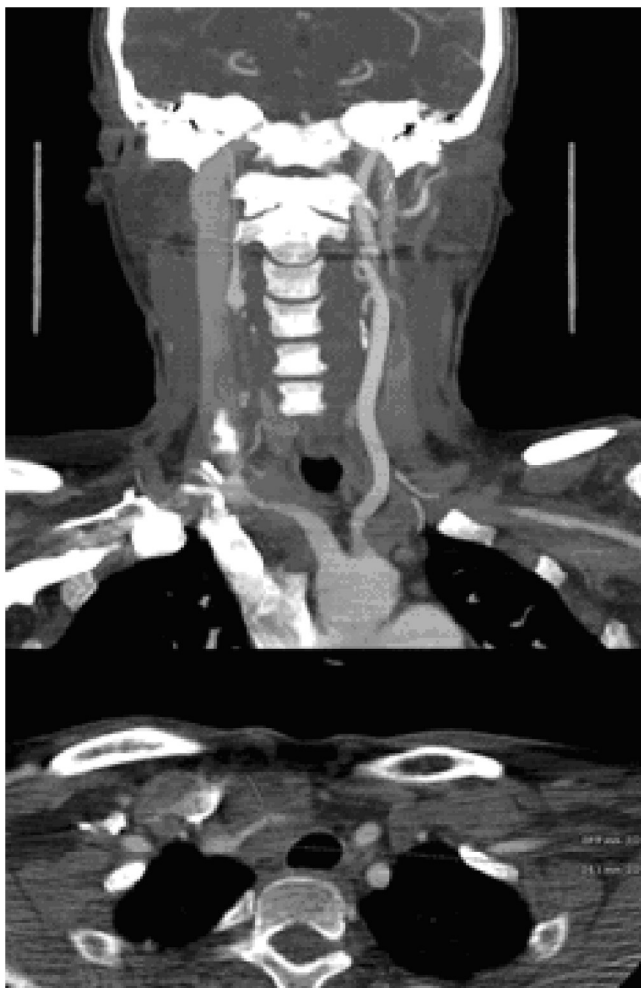

Fig. 1. Tumour around the brachiocephalic artery with severe stenosis of right subclavian artery and completed occlusion of common carotid artery.

fibres of the external elastic lamina. Moderate acute inflammation of the adventitia was seen in the right common carotid, with no signs of infiltration (Fig. 2). These findings were characteristic of GCA and are consistent with the diagnosis of temporal Horton disease or Takayasu arteritis (TA). On the basis of the histological findings, erythrocyte sedimentation rate (ESR), immunological study, syphilis serology, and fludeoxyglucose F18 positron emission tomography (PET) were carried out, all with negative findings. Treatment with oral steroids was initiated. After one year of follow-up, the patient showed no symptoms and treatment continued.

3. Discussion

GCA is a systemic vasculitis of unknown aetiology which typically affects the temporal, vertebral, and ophthalmic arteries, and less commonly the large arterial tree. Temporal Horton arteritis affects over 1% of the general population aged 50 years or more. Diagnosis is usually late, typically several years after disease onset. TA is also char-

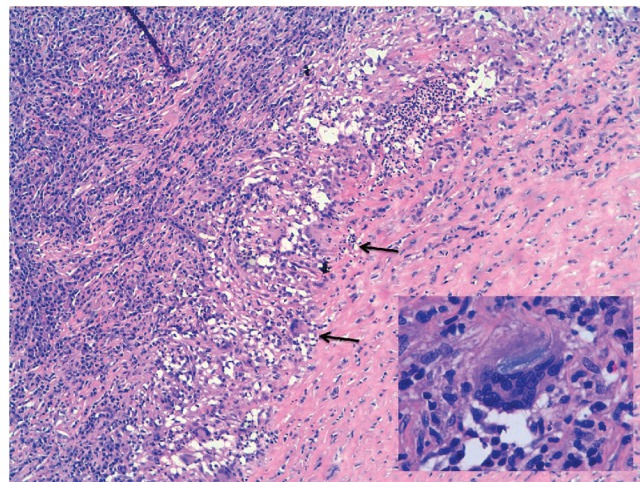


Fig. 2. Partial arterial obliteration with dense transmural inflammatory infiltration with lymphocytes, macrophages, and numerous multinucleated giant cells (arrows) (20 \times). Multinucleated giant cell contain fragments of phagocytosed internal elastic lamina in the cytoplasm (40 \times).

acterized by giant cells, although onset is usually between 10 and 30 years of age, predominantly in women. Maksimowicz-McKinnon et al. recently reported that GCA and TA are the same entity with different phenotypes [3].

The typical symptomatology is migraine associated with general symptoms, such as weakness, anorexia, fever, and weight loss. Damage to large vessels, particularly the thoracic aorta, subclavian and axillary arteries, the femoropopliteal axis and supra-aortic arterial vessels, are the main complications. In the long-term, complications such as aneurysms, aortic dissection, or aortitis are common. In our patient, the neurological symptoms and the mass located around the brachiocephalic artery suggested a vascular or soft-tissue tumour, fibrosing mediastinitis, or localized lymphoma.

Diagnosis was supported by the inflammation pattern blood test; although a normal blood count and ESR do not exclude the diagnosis. Magnetic resonance angiography and histological examination (biopsy of temporal artery) usually confirm the diagnosis [4–6].

Treatment of GCA consists of suppressing inflammation with systemic steroid therapy. In our case, surgical resection of the affected artery and posterior bypass was both diagnostic and therapeutic. A straight bypass graft from the aorta to the common carotid artery was performed for artery replacement. Due to the lesion location, we were able to perform a direct anastomosis of the right subclavian artery to the bypass; as a result, a bifurcated graft – the usual solution for brachiocephalic artery lesions – was not needed. Due to the rare and unusual form of presentation, the diagnosis was based on histological findings.

References

- [1] Weyand CM, Goronzy JJ. Medium- and large-vessel vasculitis. *N Engl J Med* 2003;349:160–169.

- [2] Wang X, Hu ZP, Lu W, Tang XQ, Yang HP, Zeng LW, Zhang J, Li T. Giant cell arteritis. *Rheumatol Int* 2008;29:1-7.
- [3] Maksimowicz-McKinnon K, Clark TM, Hoffman GS. Takayasu arteritis and giant cell arteritis: a spectrum within the same disease? *Medicine (Baltimore)* 2009;88:221-226.
- [4] Turlakow A, Yeung HWD, Pui J, Macapinlac H, Liebovitz E, Rusch V, Goy A, Larson SM. Fludeoxyglucose positron emission tomography in the diagnosis of giant cell arteritis. *Arch Intern Med* 2001;161:1003-1007.
- [5] Houthuizen P, Polak PE, Edelbroek MAL, Peels CH. Giant cell arteritis as a cardiovascular entity. *Neth Heart J* 2009;17:281-283.
- [6] Moschos M, Guex-Crosier Y. Giant cell arteritis: a rare cause of posterior vasculitis. *Clin Ophthalmol* 2009;3:111-115.