

Neurol Med Chir (Tokyo) 50, 502~505, 2010

**Chondrosarcoma With Atypical Clinical Presentation
Treated by Gamma Knife Radiosurgery
for Multiple Brain Metastases
—Case Report—**

Satoshi TSUTSUMI, Yukimasa YASUMOTO,
Hideki OIZUMI*, and Masanori ITO

*Departments of Neurological Surgery and *Neurology,
Juntendo University Urayasu Hospital, Urayasu, Chiba*

Abstract

A 60-year-old male was first treated for World Health Organization (WHO) grade II chondrosarcoma arising from the ring finger manifesting as painful swelling. Four years later, the patient presented with cerebral infarction. Echocardiography revealed a tumor occupying the left atrium. He underwent open heart surgery and the tumor was identified as metastatic chondrosarcoma with malignant transformation to WHO grade III lesion. Five months following the cardiac surgery, the patient suffered generalized seizure. Cerebral magnetic resonance imaging revealed multiple parenchymal lesions. Surgical tumor extirpation confirmed the histological diagnosis as metastatic grade III chondrosarcoma. Gamma knife radiosurgery (GKS) performed postoperatively controlled the parenchymal lesions for more than 10 months without relapse. GKS may be effective for the treatment of brain metastasis from high grade chondrosarcoma.

Key words: chondrosarcoma, cardiac metastasis, brain metastasis, radiosurgery

Introduction

Chondrosarcoma is a malignant type of mesenchymal tumor arising from the bone and soft tissue, and can be classified into World Health Organization (WHO) grade I benign to grade III malignant subtypes according to the histological appearance. Grade III chondrosarcoma is a dedifferentiated type with high metastatic potential and is associated with a dismal prognosis, as adjuvant chemoradiation therapy is not effective.^{6,12,13} Distant metastases account for 10% of grade II and 71% of grade III chondrosarcomas, and can occur in the lung, humerus, femur, sternum, liver, pleura, and ureter. Survival in patients with metastasis is significantly reduced, with a 5-year survival rate of only 18%.^{2,12} Heart and brain metastases, especially the latter, are exceptionally rare and scarcely documented.^{1,2,4,5,9-11} Although rare, chondrosarcoma can arise from the hand.^{8,10,12}

Here we describe a case of chondrosarcoma originating from the ring finger, followed by metastasis to the heart manifesting as cerebral infarction, and presented with multiple brain metastases which were successfully controlled by gamma knife radiosurgery (GKS).

Case Report

A 60-year-old male presented with a painful swelling in the left ring finger in 2003. He underwent a biopsy which established the diagnosis of WHO grade II chondrosarcoma, followed by amputation of the affected finger. Systemic examination revealed no metastatic foci and the patient did not undergo additional therapy. He remained asymptomatic for more than 4 years, but then suffered cerebral infarction in the right frontal lobe manifesting as left hemiparesis in October 2007.

Echocardiography revealed a mixed-echoic mass occupying the left atrium with to and fro movements between the atrium and ventricle, without symptoms of heart failure. Systemic examination revealed tumorous lesions, 3.5 cm in diameter, in the hilum of the left lung, separate from the mass in the heart, and spleen. He was a non-smoker and the serum tumor markers were within normal limits. Cerebral magnetic resonance (MR) imaging with contrast medium showed no metastatic lesion other than small infarcts in the right frontal lobe and ipsilateral cerebellar hemisphere in the distribution of the posterior inferior cerebellar artery. MR angiography revealed no vascular lesions. As the cardiac tumor was considered to be the origin for brain infarction and threatened sudden heart failure, he underwent open heart surgery. The tumor was totally resected and histological examination identified WHO grade III chondrosarcoma with exaggerated cell atypia compared to the primary histology. Postoperatively, the patient underwent three courses of cisplatin-based chemotherapy, after which the lung tumor showed no growth, but the splenic lesion demonstrated additional asymptomatic enlargement. The patient suffered generalized seizure in March 2008 and was referred to our department.

On admission, the patient presented with mild left

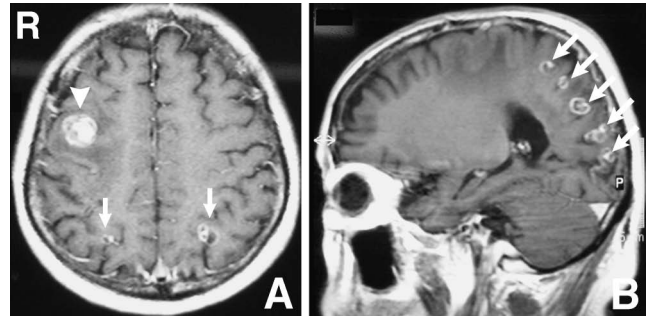


Fig. 1 Preoperative axial (A) and sagittal (B) T₁-weighted magnetic resonance images after gadolinium infusion demonstrating subcortically located, heterogeneously enhanced, multiple tumors in the bilateral frontoparietal and occipital lobes (arrows), with a lesion located in the right frontal lobe (arrowhead).

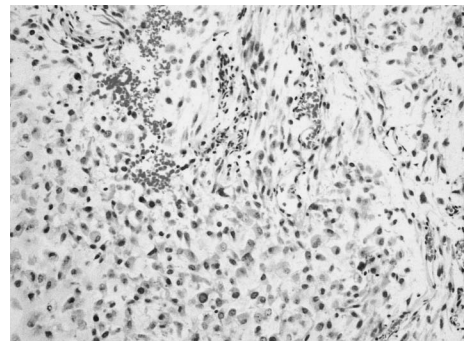


Fig. 2 Photomicrograph of the metastatic brain tumor showing dedifferentiation of the chondrosarcoma with prominent cell atypism, pleomorphism, and mitotic activity. Hematoxylin and eosin stain, $\times 200$.

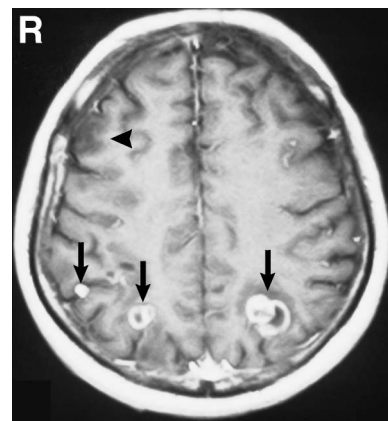


Fig. 3 Axial T₁-weighted magnetic resonance image after gadolinium infusion performed 1 month following tumor removal showing total resection of the right frontal tumor (arrowhead) and significant growth of the untreated metastatic foci (arrows).

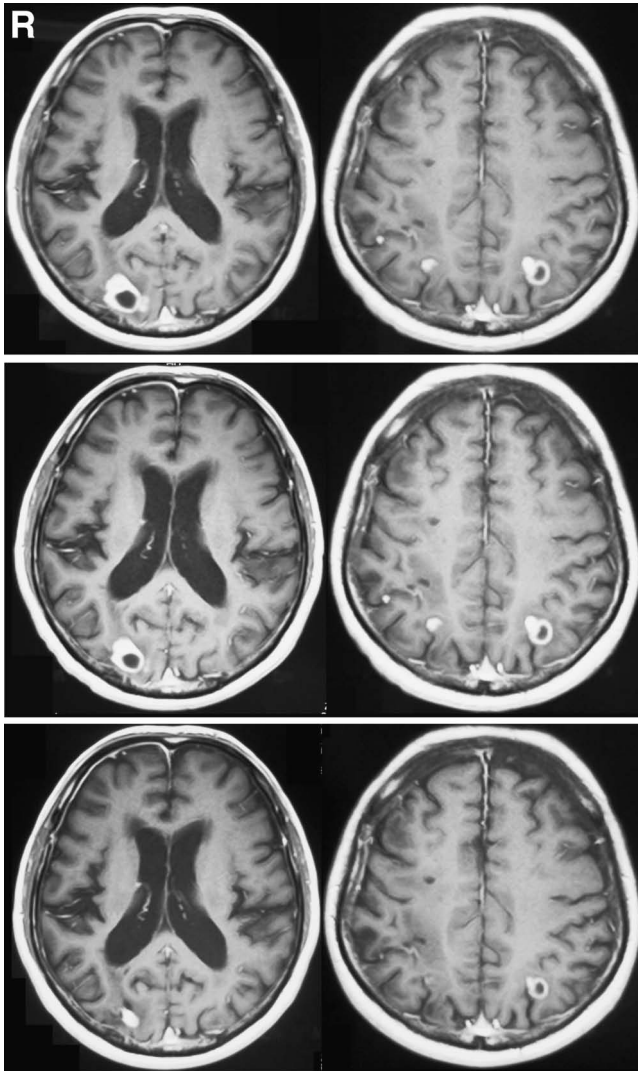


Fig. 4 Serial postcontrast T₁-weighted magnetic resonance images before (upper row), 3 month after (middle row), and 9 months after gamma knife radiosurgery (lower row) demonstrating significant tumor regression and even disappearance of some tumors.

hemiparesis due to the previous cerebral infarction. Cranial MR imaging revealed multiple contrast-enhanced lesions in the cerebral parenchyma (Fig. 1). No enhanced lesion was found within the supra- and infratentorial old infarcts. He underwent surgical extirpation of a superficially located tumor in the right frontal lobe. The grayish tumor was well-circumscribed, elastic soft, and bled little. The histological diagnosis was WHO grade III chondrosarcoma based on the prominent cell atypism and mitotic activity (Fig. 2). Cerebral MR imaging performed 1 month following tumor resection revealed significant growth of the untreated parenchymal lesions (Fig. 3). Then the patient underwent GKS (marginal dose 22.6 Gy, maximum dose 45.2 Gy) for the multiple foci, 14 in total, distributed in the bilateral frontoparietal and occipital lobes, and except for the totally removed right frontal

mass, which were all less than 1.5 cm in diameter. The irradiated tumors showed a continuous regression without relapse in the following 9 months (Fig. 4). The patient has been doing well for more than 10 months after irradiation with asymptomatic but gradually enlarging lesions in the lung and spleen refractory to serial courses of cisplatin-based chemotherapy.

Discussion

In the present case, metastatic foci in the brain parenchyma were controlled well by GKS without relapse or worsening of the daily activities of the patient for more than 10 months. Although GKS is a treatment option for selected cases of primary chondrosarcoma arising in the skull base, GKS for metastatic lesions has not previously been documented.⁷⁾ Generally, chondrosarcoma is considered to be less sensitive to conventional radiation therapy, as well to any type of chemotherapy, like other mesenchymal sarcomas. In the present case, irradiated chondrosarcomas, especially if less than 1 cm in diameter, showed significant regression or even disappearance, without consequent relapse, in a short follow-up period. Considering the usual dismal prognosis of high-grade chondrosarcoma, GKS may be a useful option for controlling intracranial metastases, while simultaneously maintaining the affected patients' quality of life. More patients and longer follow-up periods may determine the role and effectiveness of GKS against parenchymal metastases from chondrosarcoma.

The currently used grading system for chondrosarcomas is defined for convenience in the clinical setting, but the malignant potential is difficult to evaluate based only on the histological appearance.¹⁴⁾ With recent advances in genetic and molecular diagnostics, chondrosarcomas are to be considered as part of a heterogeneous group of tumors including the diverse family of cartilaginous neoplasms. Developmental therapeutics based on these modalities may improve the classification algorithm and appropriate chemotherapeutic regimen for individual chondrosarcomas.³⁾ GKS should be considered as an option with developing chemotherapy to comprise treatment strategies for chondrosarcoma. The present case suggests that GKS may be effective for controlling brain metastases from chondrosarcoma, especially if the lesions are small.

References

- 1) Banfić L, Jelić I, Jelasić D, CuZiĆ S: Heart metastasis of extraskeletal myxoid chondrosarcomas. *Croat Med J* 42: 199–202, 2001
- 2) Bruns J, Elbracht M, Niggemeyer O: Chondrosarcoma of bone: an oncological and functional follow-up study. *Ann Oncol* 12: 859–864, 2001
- 3) Chow WA: Update on chondrosarcomas. *Curr Opin Oncol* 19: 371–376, 2007
- 4) Fichaux O, de Muret A, Dessenne X, Rosset P, Pacouret G, Pagot O, Charbonnier B: [Cardiac metastasis of chondrosarcoma: a case report]. *Ann Cardiol Angeiol (Paris)* 47: 165–168, 1998 (Fre, with Eng abstract)
- 5) Gercovich FG, Luna MA, Gottlieb JA: Increased incidence of

- cerebral metastases in sarcoma patients with prolonged survival from chemotherapy. *Cancer* 36: 1843-1851, 1975
- 6) Grimer RJ, Gosheger G, Taminiau A, Biau D, Metejevsky Z, Kollender Y, San-Julian M, Gherlinzoni F, Ferrari C: Dedifferentiated chondrosarcoma: prognostic factors and outcome from a European group. *Eur J Cancer* 43: 2060-2065, 2007
 - 7) Hasegawa T, Ishii D, Kida Y, Yoshimoto M, Koike J, Iizuka H: Gamma Knife surgery for skull base chordomas and chondrosarcomas. *J Neurosurg* 107: 752-757, 2007
 - 8) Hatori M, Watanabe M, Kotake H, Kokubun S: Chondrosarcoma of the ring finger: a case report and review of the literature. *Tohoku J Exp Med* 208: 275-281, 2006
 - 9) Leung CY, Cummings RG, Reimer KA, Lowe JE: Chondrosarcoma metastatic to the heart. *Ann Thorac Surg* 45: 291-295, 1998
 - 10) Nigrisoli M, Ferraro A, De Cristofaro R, Picci P: Chondrosarcoma of the hand and foot. *Chir Organi Mov* 75: 315-323, 1990 (Eng, Ita)
 - 11) Ogose A, Morita T, Hotta T, Kobayashi H, Otsuka H, Hirata Y, Yoshida S: Brain metastasis in musculoskeletal sarcomas. *Jpn J Clin Oncol* 29: 245-247, 1999
 - 12) Pritchard DJ, Lunke RJ, Taylor WF, Dahlin DC, Medley BE: Chondrosarcoma: a clinicopathologic and statistical analysis. *Cancer* 45: 149-157, 1980
 - 13) Staals EL, Bacchini P, Bertoni F: Dedifferentiated central chondrosarcoma. *Cancer* 106: 2682-2691, 2006
 - 14) Sugita H, Osaka S, Toriyama M, Osaka E, Yoshida Y, Ryu J, Sano M, Sugitani M, Nemoto N: Correlation between the histological grade of chondrosarcoma and the expression of MMPs, ADAMTSs and TIMPs. *Anticancer Res* 24: 4079-4084, 2004
-
- Address reprint requests to: Satoshi Tsutsumi, M.D., Department of Neurological Surgery, Juntendo University Urayasu Hospital, 2-1-1 Tomioka, Urayasu, Chiba 279-0021, Japan. e-mail: shotaro@juntendo-urayasu.jp