

Loss of psychic self-activation with bithalamic infarction

Neurobehavioural, CT, MRI and SPECT correlates

Bogousslavsky J, Regli F, Delaloye B, Delaloye-Bischof A, Assal G, Uske A. Loss of psychic self-activation with bithalamic infarction. Neurobehavioural, CT, MRI and SPECT correlates. *Acta Neurol Scand* 1991; 83: 309–316.

Two patients with bilateral thalamo-mesencephalic infarct in the paramedian territory developed vertical gaze dysfunction and marked behavioural changes, in the absence of significant motor inability and formal neuropsychological impairment. While they were physically and emotionally active before stroke, they became apathetic, asponaneous, indifferent, and seemed to have lost motor and affective drive, as well as the need itself for any psychic activity. However, this mental and motor inertia was reversible when the patients were repeatedly stimulated by another person. This need for constant external programming, together with a lack of emotional reactivity, made the patients resemble robots. CT and MRI suggested involvement of the dorsomedial and midline nuclei of the thalamus, and SPECT showed remote frontomesial hypoperfusion. A disturbance of the striatal-ventral pallidal-thalamic-frontomesial limbic loop is suggested by previous reports of a similar "loss of psychic self-activation", "pure psychic akinesia", or "athymhormia" with bipallidal, bistriatal, or subcortical bifrontal lesions.

J. Bogousslavsky¹, F. Regli², B. Delaloye², A. Delaloye-Bischof², G. Assal³, A. Uske⁴

Department of ¹ Neurology, ² Division of Nuclear Medicine, ³ Division of Neuropsychology, ⁴ Department of Radiology, Centre Hospitalier Universitaire Vaudois, Lausanne, Switzerland

Key words: infarction; bithalamic; psychic self-activation; CT; MRI; SPECT

J. Bogousslavsky, Department of Neurology, CHUV, 1011 Lausanne, Switzerland

Accepted for publication October 29, 1990

The neurobehavioural changes due to bilateral lesions of the thalamus usually include memory dysfunction, and, in severe cases, a picture known as "thalamic dementia" may develop (1–4), in which amnesia, speech disturbances, confusional state and complex motor abnormalities may be associated with some degree of apathy, flattened affect and decreased motivation (5). We have studied two patients with bithalamic infarction, who had no amnesia, aphasia, apraxia or agnosia, but with emotional indifference and selective impairment of spontaneous acting, which could readily be reversed under external stimulations by another person. This behavioural syndrome seems similar to the "loss of psychic self-activation" reported in patients with bilateral lesions of the globus pallidus, striatum, and frontal lobe white matter (6–10).

Case reports

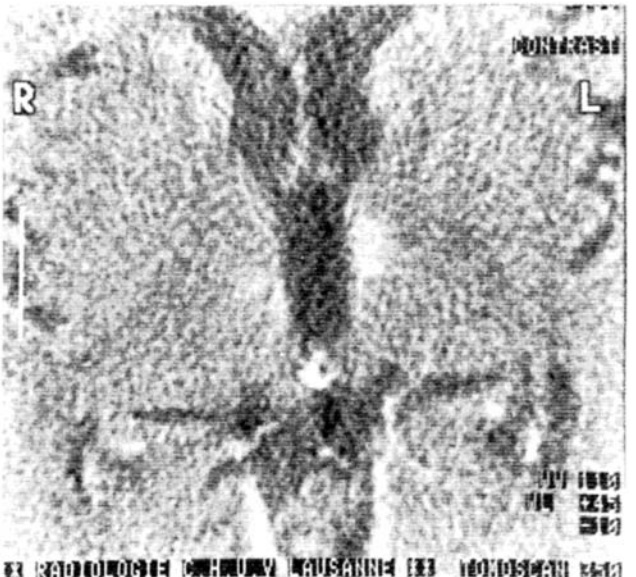
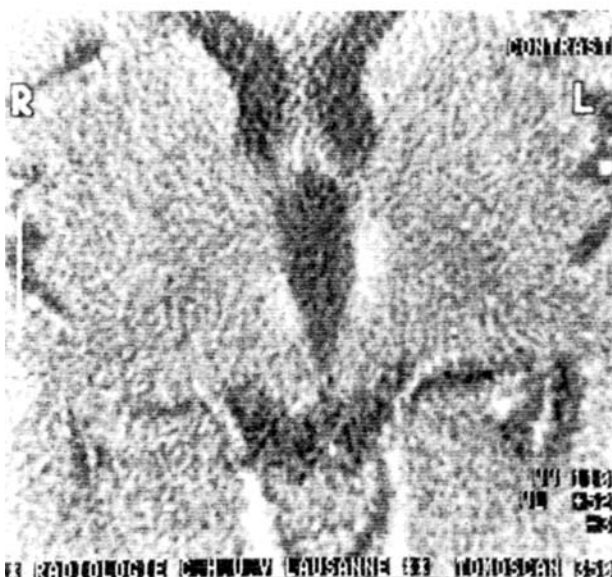
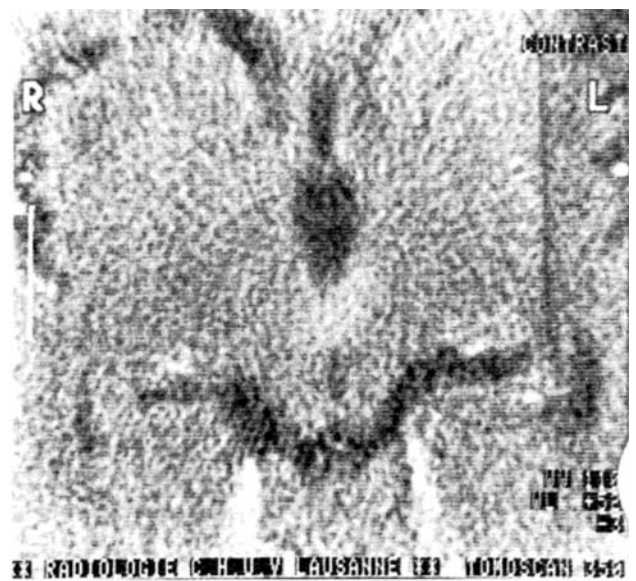
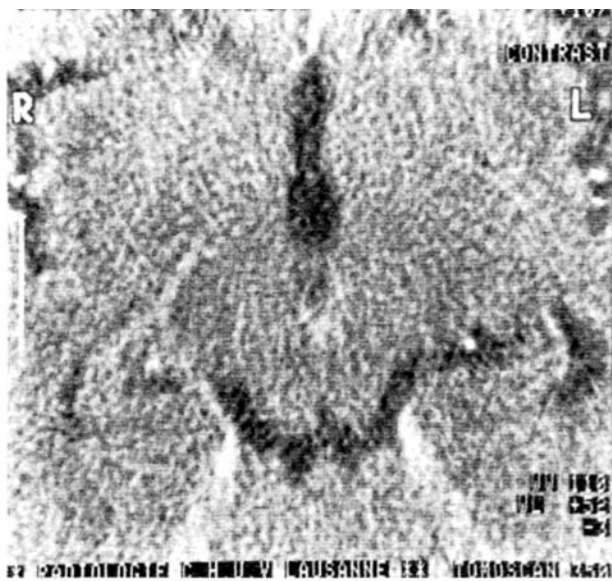
Patient #1. A 61-year old clerk with known atrial fibrillation was admitted because of "confusion" and left palpebral ptosis. On admission, the patient was reported to be disorientated in time, without somnolence. He had a left palpebral ptosis, adduction paresis in the left eye, and combined up- and down-gaze palsy. The remainder of neurologic examination was unremarkable, except for slight dysmetria and

hypermetria in the four limbs. Blood pressure was 130/80 mm Hg. CT the same day was normal, but, four days later, thin (3 mm) CT sections with contrast showed a subacute bilateral thalamo-mesencephalic infarct in the paramedian territory (4, 11, 12) (Fig. 1); at the thalamic level, the midline nuclei, the posterior part of the dorsomedial nucleus and the ventro-oralis part of the ventral lateral nucleus were involved bilaterally, as well as the inner part of the intralaminar nuclei on the left side (13, 14). SPECT (HM-PAO 10 mCi, with a dual head ROTA camera at 6° steps of 30" each) 20 days after stroke showed marked hypoperfusion (50% compared with parietal and temporal lobes) in the frontal and diencephalic structures bilaterally; in the frontal lobes, the reduction in perfusion was maximal in the posterior parasagittal areas (Fig. 2). ECG showed atrial fibrillation and an old anterior infarct. Bidimensional echocardiography showed an anterolateral aneurysm and thrombus.

The most striking changes involved the patient's behaviour. According to his family, he had become "passive" and had lost any emotional concern. He was somnolent and was orientated in time and place (from Day 2), but remained apathetic and did not speak spontaneously. He moved very little unless asked to do so, only to go to the bathroom three or four times a day. He would sit down at the table to

eat only when asked by the nurses or family and would stop eating after a few seconds unless repeatedly stimulated. During the day, he would stay in bed or in an armchair unless asked to go for a walk. He did not react to unusual situations in his room, such as Grand Mal seizures in another patient. He did not read the newspapers and did not watch the television. This behaviour contrasted with preserved motor and speech abilities when he was directly stimulated by another person: with constant activation, he was able to move and walk normally, he could play cards, answer questions, and read a test and comment on it thereafter; however, these activities would stop immediately if the external stimulation disappeared. He did not show imitation and

utilization behaviour (15), and could inhibit socially inadequate acts, even when asked to perform them by an examiner (shouting in the room, undressing during daytime); however, he did not react emotionally to such orders. Also, he showed no emotional concern to his illness, though he did not deny it, and he remained indifferent when he had visitors or received gifts. He did not smile, laugh or cry. He never mentioned his previous activities and, when asked about his job, he answered he had no project to go back to work. When asked about his private thoughts, he just said "that's all right", "I think of nothing", "I don't want anything". Because his motor and mental abilities seemed normal when stimulated by another person, his family and friends



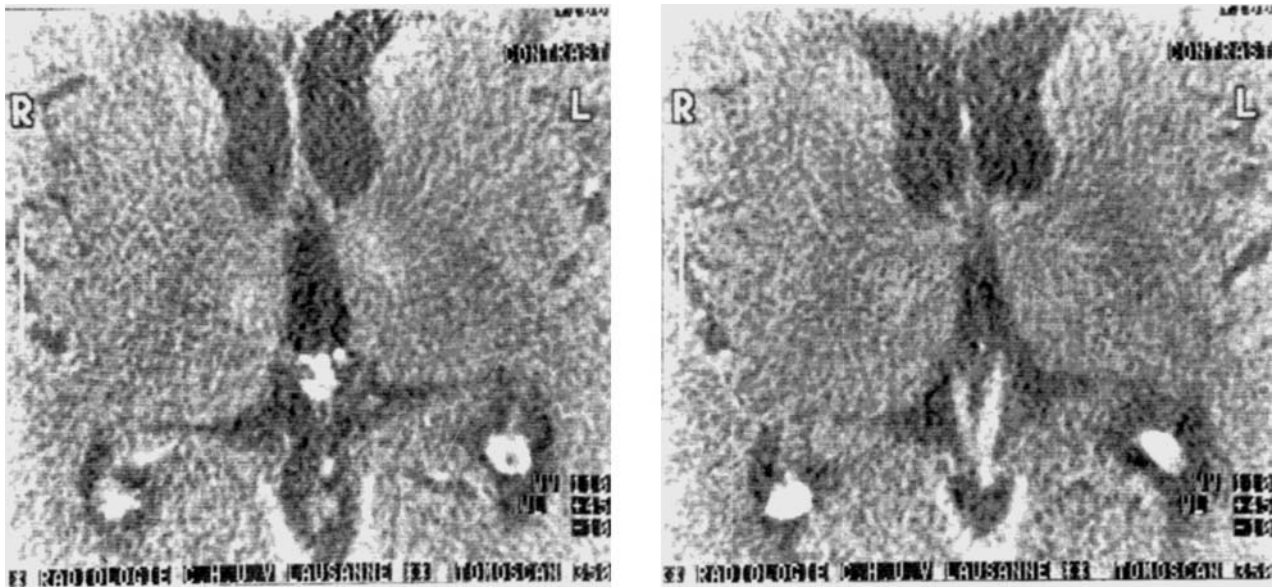


Fig. 1. Patient 1. Contrast CT thin (3 mm) slices from upper midbrain to thalamus (A to E) show bilateral infarction in the paramedian territory.

wondered whether he was really ill or was inactive on purpose, to annoy them. They complained he had become "a larva".

Formal neuropsychological examination using a standard battery of tests (16) was performed 3, 10, 25 and 60 days after stroke, including naming (17), repetition (16), comprehension (18), writing (16), reading (16), facial recognition (19), visuospatial recognition (20, 21), topographic orientation on maps (16), drawing (16), copy of the Rey-Osterrieth figure (22), which were normal. No memory dysfunction was found: the patient could evoke remote and recent events of his past, visual [Corsi's block tapping (23, 24)] and verbal [Hebb's recurring digits (24)] learning, delayed reproduction of the Rey-Osterrieth figure (22) showed normal results for age. Only minor disturbances were found on "frontal lobe tests" (inhibition of automatic responses during conflictual tasks): slight slowing on Stroop test (25) (1'10"; no mistake; 4 self-corrections), but no mistake or perseveration on Luria's conflicting tasks, sequential rhythms and sequential geometrical figures (26). His symbolic understanding of proverbs was preserved. The patient could cross out 20 lines distributed evenly on a sheet of paper; with no left- or right-side preference.

The patient was discharged unchanged two months after stroke to a chronic care institution, because his family could not cope with his behavioural disturbances, though they recognized that his intellect was spared.

Patient #2. A 64-year-old housewife was in good health until she was admitted to hospital after she

lost consciousness for 5 min and subsequently complained that she was unable to look downwards. On admission 2 h later, her state of consciousness was normal, and detailed examination showed no abnormality, except a slight (10°) upward deviation of the eyes, with complete downgaze palsy. Blood pressure was 140/90 mm Hg. CT with and without contrast was normal the same day, but 9 days later, thin (3 mm) MRI sections with gadolinium enhancement showed a bilateral thalamo-mesencephalic infarct in the paramedian territory (Fig. 3); in the thalamus, the midline nuclei and the dorsomedial nucleus were involved on both sides (13, 14). SPECT (same technique as for Patient 1) 16 days stroke showed decreased perfusion (40% compared with parietal and temporal lobes) in the frontal and diencephalic regions; in the frontal lobe, the hypoperfusion predominated in the postero-mesial region (Fig. 4). ECG monitoring showed paroxysmal bursts of atrial fibrillation.

According to her family, the patient's mood had changed completely after her stroke. Previously, she was active, she liked jokes, and enjoyed being with her grandchildren, but she had become indifferent, did not manifest emotions and did not laugh anymore. Though she was not sleepy, she would stay in bed for the whole morning, unless the nurse would come and ask her to get up and wash herself. She spoke very little spontaneously and did not join conversations with other patients, except to answer questions. She did not seem to be interested in anything and did not enjoy or criticize the meals, though she used to be an expert cook. Unless stimulated by the staff or her family, she did not do

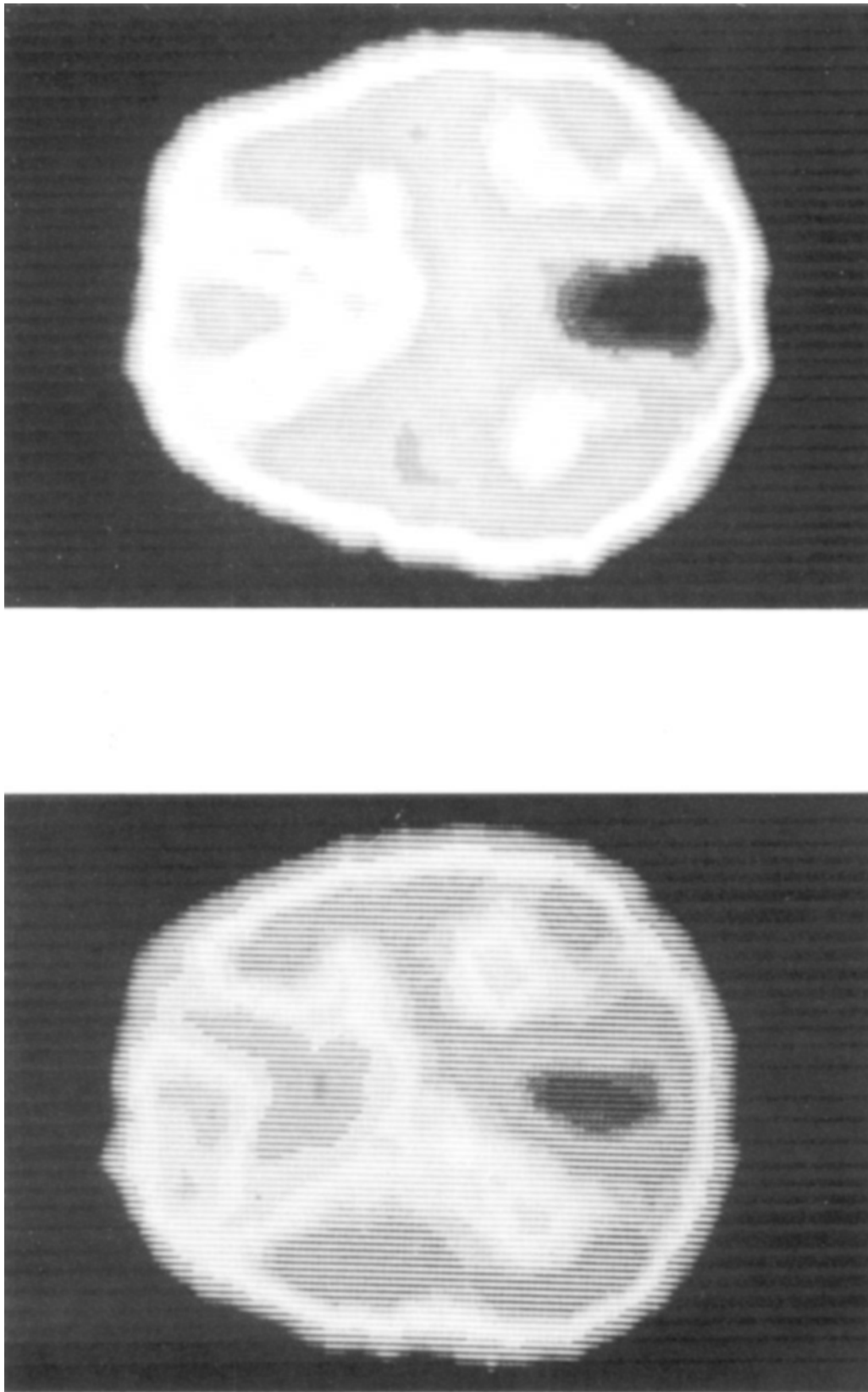


Fig. 2. Patient 1. SPECT 20 days after stroke (HM-PAO 10 m Ci, transverse slices obtained 10 min after injection in a plan parallel to the orbitomeatal line). Transverse views 5 cm (A) and 9 cm (B) above the orbitomeatal line show decreased perfusion in the deep frontothalamic and cortical frontomesial regions (50% compared with parietal lobes) on both sides.

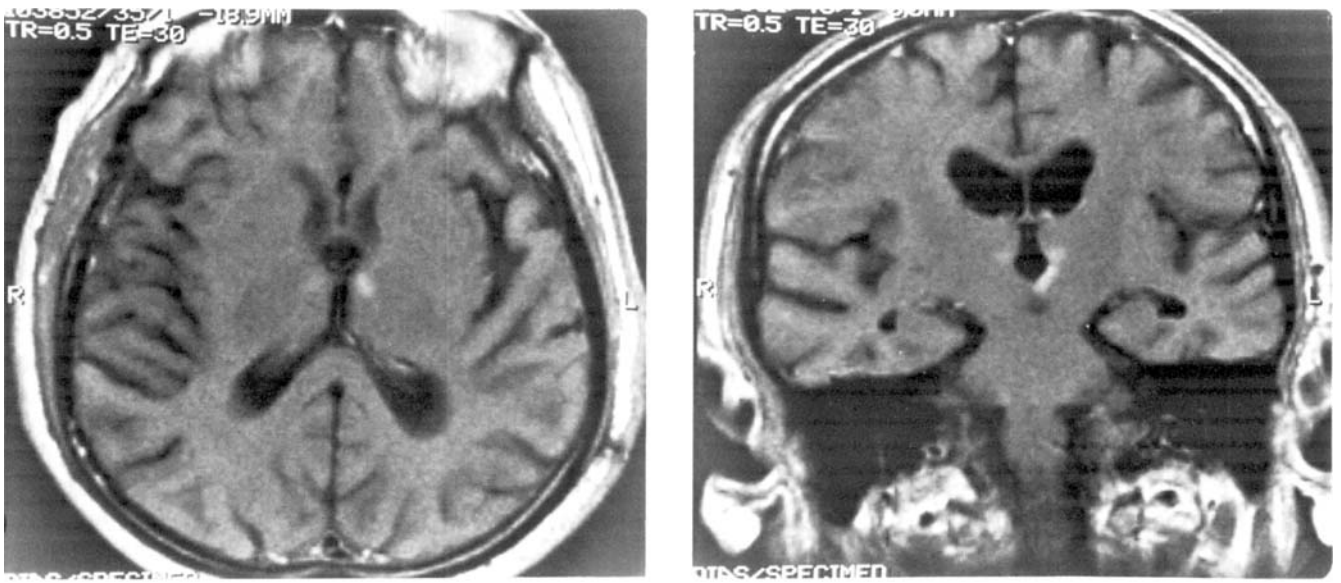


Fig. 3. Patient 2. MRI thin (3 mm) sections with gadolinium enhancement show bilateral thalamic infarct (A, B) in the paramedian territory.

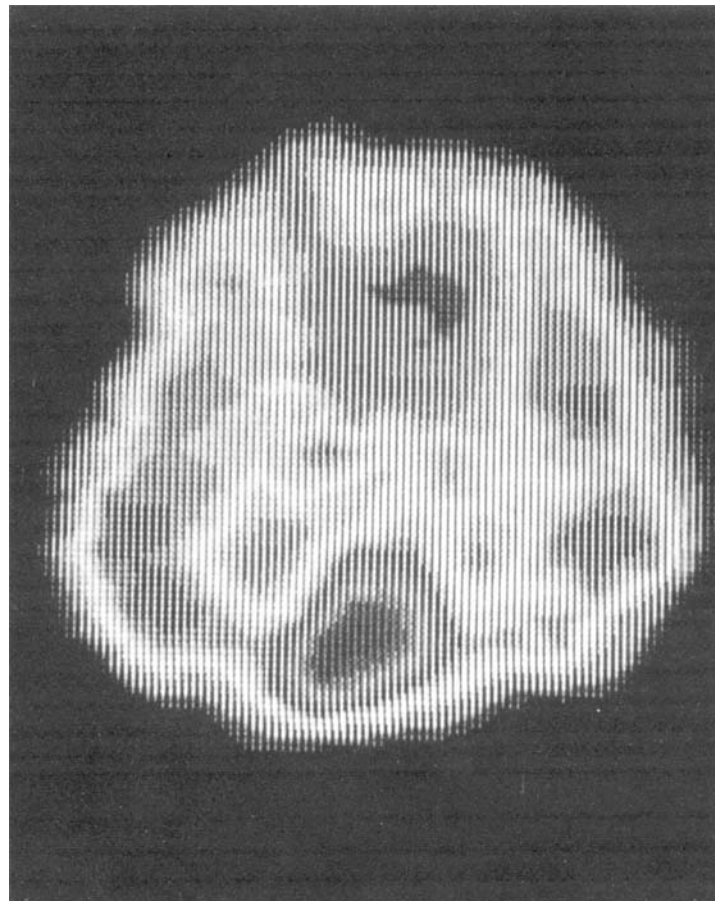


Fig. 4. Patient 2. SPECT 16 days after stroke (HM-PAO m Ci, transverse slices obtained 10 min after injection in a plan parallel to the orbitomeatal line). Transverse views 4 cm above the orbitomeatal line show bifrontal hypoperfusion predominating in the posterior mesial region (40% decrease compared with temporo-parietal regions).

anything spontaneously, except sitting in front of the television for hours, going to the bathroom, and browsing among magazines, but without apparent curiosity. She remembered perfectly what she had seen on television or in the magazines, but without expressing any particular interest in any item. She did not have any projects for the future and did not report personal thoughts. This passive behaviour contrasted with her ability to perform usual daily activities when stimulated and ordered by another person. She could sew, knit, play dominoes and go shopping when assisted by her daughter, who had to tell her what to do next. However, she did not show imitation and utilization behaviour (15), and even after a rather automatic activity (like knitting), she showed no perseverations.

Neuropsychological examination (16) was done 2 and 17 days after stroke. The patient was not disorientated or distracted, but tended to stop doing the tests unless constantly stimulated. With such help, she collaborated well with the examiner. Naming (17), repetition (16), comprehension (18), reading (16), writing (16), Poppelreuter (20), and recognition of objects and faces (16, 19) were normal. Verbal (15 words of Rey (22): total of 55: 9-10-10-12-14) and visual (15 signs (16): total of 60: 10-10-12-14-14) learning was unimpaired. She made no mistake but some self-corrected perseverations on Luria's conflicting tasks (26) and, on Stroop's test (25), naming was slightly slowed (1'04"; no mistake; 5 self-corrections). On Wisconsin card sorting test (27), she found 4 clues out of 6.

The patient was discharged 3 weeks after stroke to her daughter's home. On follow-up phone calls 2 and 4 months later, the daughter reported that the apathy and indifference had slightly improved, but that the patient still needed external stimulations to accomplish her daily activities. Under this condition, the patient was able to help cleaning the house and to cook; she did not seem, however, to have feelings of happiness or sadness.

Discussion

Both our patients showed striking behavioural changes as the main feature of bilateral paramedian thalamo-mesencephalic infarct. While they were reported to be active people who enjoyed life before their stroke, they became apathetic and indifferent, and they lost the drive for acting and speaking spontaneously. They seemed to have lost not only the willingness to search for satisfactions, but also the very need for mental and affective activities. This severe impairment of psychic and motor spontaneity contrasted with sparing of neuropsychological and motor abilities when tested with external stimulations. Actually, our patients behaved as if their

primary disturbance was the loss of ability to activate their own psychism and motricity. When somebody else made up for this loss by asking or ordering what to do, the patients could then act nearly normally.

This "psychic akinesia" (28) or "loss of psychic self-activation" (6) or "athymhormia" (10) was previously reported in patients with toxic bilateral subcortical lesions predominating in the globus pallidus (7, 8) or putamen (6, 10). In addition, most of their patients showed a compulsive-like, pseudo-obsessional, activity (arithmomania, vocalization, stereotyped mental activity) which was lacking in our patients.

In many ways, the apathy and indifference is reminiscent of the "pseudo-retarded" form of the frontal lobe syndrome (29), though our patients showed only minimal dysfunction on "frontal lobe tests". This sparing can occur in bilateral frontal damage (9, 30). Patient EVR (30) had bilateral orbito-mesial damage, a normal measurable intelligence, but he was unable to use planned or learned programs for his daily living. For that reason, he was considered a malingerer for a long time, and the same thing happened to some extent to our first patient. It is interesting to emphasize that, in our two patients, SPECT showed marked bilateral mesial frontal hypoperfusion, though none had a frontal lesion on CT or MRI.

In our patients, the only visible lesions were in the paramedian thalamus and upper midbrain, involving the dorsomedial nucleus and midline nuclei bilaterally, and in Patient 1 a small part of the intralaminar nuclei (left side) and of the ventral lateral nucleus (both sides). In reported cases with bilateral paramedian thalamic infarcts, several neuropsychological disturbances may be present (31-48), in relation to involvement of the dorsomedial nucleus (dysphasia, amnesia) (4, 49-51), mamillo-thalamic tract (amnesia) (3), intralaminar nuclei (confusion, hemineglect) (3, 45, 52), or ventral lateral nucleus (hemineglect) (53), possibly with subsequent deactivation of some cortical areas (54-58). In larger bithalamic infarcts, akinetic mutism may occur (45, 59, 60). Apathy, unconcern, poor motivation and flat affect have been reported in patients with "thalamic dementia" (3-5), but they were only part of a more complex dysfunction. To our knowledge, they have not been reported in isolation.

In patients with bilateral lesions of the globus pallidus and striatum, the authors hypothesized a disruption of the limbic loop of the striato-pallidal complex (61). In this loop, the ventral striatum projects to the ventral pallidum, which projects to the dorsomedial nucleus of the thalamus, which projects to the posterior orbital cortex and mesial frontal cortex rostral to area 32, which projects to the anterior cingular gyrus, which projects back to the ventral

striatum. It is conceivable that bilateral disruption of this loop at different levels may lead to a similar clinical picture.

In our patients, the core of the thalamic infarct was in the dorsomedial and midline nuclei, yet none had the features of thalamic amnesia or thalamic dementia, which have often been related to bilateral involvement of the dorsomedial nucleus (36, 62, 63). However, the issue of topographic correlates of thalamic amnesia is still debated (64), and some patients with amnesia but no or little damage to the dorsomedial nucleus have been reported (3, 65). In fact, it is possible that partial damage to the dorsomedial nucleus may have markedly different clinical effects, according to the lesion site, because this nucleus contains several nuclear subgroups involved in different circuits. The magnocellular part forms the medial third of the nucleus, while the parvocellular part and the multiformis part form the lateral two-thirds of the nucleus and extend more caudally (66). The "memory loop" of the dorsomedial nucleus may involve its magnocellular part, which receives projections from the amygdaloid nucleus and projects to the precommissural hippocampus; on the other hand, non-magnocellular parts of the nucleus seem to be involved in the limbic loop of the striato-pallidal complex (61), and their damage may thus lead to loss of psychic self-activation without amnesia. Our findings of fronto-mesial hypoperfusion support the hypothesis of a thalamic-frontomesial dysfunction as a dynamic correlate.

Our study highlights the development of severe behavioural dysfunction from limited and selective involvement of subcortical structures. Loss of psychic self-activation should be added to other syndromes from bithalamic lesions such as isolated amnesia (32, 34), akinetic mutism (45, 59, 60), or "thalamic dementia" (1, 2).

References

- GRÜNTAL E. Über thalamische Demenz. *Monatsschr Psychiatr Neurol* 1942; 106: 114-128.
- CASTAIGNE P, BUGE A, CAMBIER J, ESCOUROLLE R, BRUNET P, DEGOS JD. Démence thalamique d'origine vasculaire par ramollissement bilatéral, limité au territoire du pédicule rétroamillaire. A propos de deux observations anatomo-cliniques. *Rev Neurol* 1966; 114: 89-107.
- GENTILINI M, DE RENZI E, CRISI G. Bilateral paramedian thalamic artery infarcts: Report of 8 cases. *J Neurol Neurosurg Psychiatr* 1987; 50: 900-909.
- BOGOUSSLAWSKY J, REGLI F, USKE A. Thalamic infarcts: Clinical syndromes, etiology, and prognosis. *Neurology* 1988; 38: 837-848.
- KATZ DI, ALEXANDER MP, MANDELL AM. Dementia following strokes in the mesencephalon and diencephalon. *Arch Neurol* 1987; 44: 1127-1133.
- LAPLANE D, WIDLÖCHER D, PILLON B, BAULAC M, BINOUX F. Comportement compulsif d'allure obsessionnelle par nécrose circonscrite bilatérale pallido-striatale. Encéphalopathie par piqûre de guêpe. *Rev Neurol* 1981; 137: 269-276.
- LAPLANE D, BAULAC M. Perte de l'autoactivation psychique. Activité compulsive d'allure obsessionnelle. Lésion lenticulaire bilatérale. *Rev Neurol* 1982; 138: 137-141.
- LAPLANE D, BAULAC M, WIDLÖCHER D, DUBOIS B. Pure psychic akinesia with bilateral lesions of basal ganglia. *J Neurol Neurosurg Psychiatr* 1984; 47: 377-385.
- LAPLANE D, DUBOIS B, PILLON B, BAULAC M. Perte d'autoactivation psychique et activité mentale stéréotypée par lésion frontale. Rapports avec le trouble obsessionnel-compulsif. *Rev Neurol* 1988; 144: 564-570.
- HABIB M, PONCET M. Perte de l'élan vital, de l'intérêt et de l'affectivité (syndrome athymhormique) au cours de lésions lacunaires des corps striés. *Rev Neurol* 1988; 144: 571-577.
- PERCHERON G. The anatomy of the arterial supply of the human thalamus and its use for the interpretation of the thalamic vascular pathology. *Z Neurol* 1973; 205: 1-13.
- CASTAIGNE P, LHERMITTE F, BUGE A, ESCOUROLLE R, HAUV JJ, LYON-CAEN O. Paramedian thalamic and midbrain infarcts: Clinical and neuropathological study. *Ann Neurol* 1981; 10: 127-148.
- SCHLESINGER B. The upper brainstem in the human: Its nuclear configuration and vascular supply. Springer, New York 1976.
- SCHALTENBRAND G, WAHREN W. Atlas for stereotaxy of the human brain: Architectonic organization of the thalamic nuclei, by Rolf Hassler. Stuttgart: Georg Thieme Publ. 1977.
- LHERMITTE F, PILLON B, SERDARU M. Human autonomy and the frontal lobes. Part I: Imitation and utilization behavior: A neuropsychological study of 75 patients. *Ann Neurol* 1986; 19: 326-334.
- ASSAL G. Batterie des examens neuropsychologiques du CHUV. Centre Hospitalier Universitaire Vaudois, Lausanne, 1985.
- KAPLAN E, GOODGLASS H, WEINSTRaub S. Boston naming memory test. Experimental Edition, Boston 1976.
- DE RENZI E, VIGNOLO LA. The Token test: A sensitive test to detect receptive disturbances in aphasia. *Brain* 1962; 85: 665-678.
- BENTON AL, VAN ALLEN MV. Impairment of facial recognition in patients with cerebral disease. *Cortex* 1968; 4: 344-358.
- POPPELREUTER W. Die psychischen Schädigungen durch Kopfschuss im Kriege 1914/1916. Leipzig, Von Leopold Voss, 1917.
- GHEENT L. Perception of overlapping and embedded figures by children of different ages. *Ann J Psychol* 1956; 69: 575-587.
- REY A. L'examen clinique en psychologie. Paris, PUF, 1965.
- MILNER B. Interhemispheric differences in the localization of psychological processes in man. *Br Med Bull* 1971; 27: 272-277.
- MILNER B. Memory and the medial temporal regions of the brain. In: PRIBRAM KH, BROADBENT DE, Biology of memory. New York, Academic Press 1970.
- STROOP JR. Studies of interference in serial verbal reactions. *J Exp Psychol* 1945; 18: 643-662.
- LURIA AR. Frontal lobe syndromes. In: VINKEN PJ, BRUYN GW (eds), *Handbook of Clinical Neurology*, vol. 2 (chapter 23), Amsterdam, Elsevier 1969: pp. 725-757.
- BERG EA. A single objective test for measuring flexibility in thinking. *J Gen Psychol* 1948; 39: 15-22.
- HASSLER R. Extrapyramidal- motorische Systeme und Erkrankung. In: *Handbuch der Inneren Medizin*, vol. V/3, Springer Verlag, Berlin 1953: pp. 676-704.
- STUSS DT, BENSON DF. The frontal lobes. Raven Press, New York 1986.
- ESLINGER PJ, DAMASIO AR. Severe disturbance of higher

- cognition after bilateral frontal lobe ablation: Patient EVR. *Neurology* 1985; 35: 1731-1741.
31. SCHOTT B, MAUGUIÈRE F, LAURENT B, SERCLERAT O, FISCHER C. L'amnésie thalamique. *Rev Neurol* 1980; 136: 117-130.
 32. BARBIZET J, DEGOS JD, LOUARN F, NGUYEN JP, MAS JL. Amnésie par lésion ischémique bi-thalamique. *Rev Neurol* 1981; 137: 415-424.
 33. GUBERMAN A, STUSS D. The syndrome of bilateral paramedian thalamic infarction. *Neurology* 1983; 33: 540-546.
 34. WINOCUR G, OXBURY S, ROBERTS et al. Amnesia in a patient with bilateral lesions to the thalamus. *Neuropsychologia* 1984; 22: 123-143.
 35. SWANSON KA, SCHMIDLEY JW. Amnestic syndrome and vertical gaze palsy: Early detection of bilateral thalamic infarction by CT and NMR. *Stroke* 1985; 16: 823-827.
 36. ROUSSEAU M, CABARET M, LESOIN F et al. Bilan de l'amnésie des infarctus thalamiques restreints - 6 cas. *Cortex* 1986; 22: 213-228.
 37. RONDOT P, DE RECONDO J, DAVOUS P, BATHIEN N, COIGNET A. Infarctus thalamique bilatéral avec mouvements anormaux et amnésie durable. *Rev Neurol* 1986; 142: 398-405.
 38. VIGHETTO A, CONFAVREUX C, BOISSON D, AIMARD G, DEVIC M. Paralyse de l'abaissement du regard et amnésie globale durables par lésion thalamo-sous-thalamique bilatérale. *Rev Neurol* 1986; 142: 449-455.
 39. MEISSNER I, SAPIR S, KOKMEN E, STEIN SD. The paramedian diencephalic syndrome: A dynamic phenomenon. *Stroke* 1987; 18: 380-385.
 40. CATSMAN-BERREVOETS CE, VAN HARSKAMPF. Compulsive pre-sleep behavior and apathy due to bilateral thalamic stroke: Response to bromocriptine. *Neurology* 1988; 38: 647-649.
 41. GERBER O, GUEDEBLATT M. Bilateral paramedian thalamic infarctions: A CT study. *Neuroradiology* 1986; 28: 128-131.
 42. GRAFF-RADFORD NR, DAMASIO H, YAMADA T, ESLINGER PJ, DAMASIO AR. Nonhaemorrhagic thalamic infarction. *Brain* 1985; 108: 485-516.
 43. SCHUSTER P. Beiträge zur Pathologie des Thalamus opticus. I. Mitteilung: Kasuistik. Gefäßgebiet der A. thalamo-geniculata, der A. thalamo-perforata, der A. tubero-thalamica und der A. lenticulo-optica. *Arch Psychiat Nervenkr* 1936; 105: 358-432.
 44. DE BOUCAUD P, VITAL C, DE BOUCAUD D. Démence thalamique d'origine vasculaire. *Rev Neurol* 1968; 119: 461-468.
 45. SEGARRA JM. Cerebral vascular disease and behavior. I. The syndrome of the mesencephalic artery (basilar artery bifurcation). *Arch Neurol* 1970; 22: 408-418.
 46. DEHAENE I. Bilateral thalamo-subthalamic infarction. *Acta Neurol Belg* 1982; 82: 253-261.
 47. POIRIER J, BARBIZET J, GASTON A, MEYRIGNAC C. Démence thalamique. Lacunes expansives du territoire thalamo-mésencéphalique paramédian. Hydrocéphalie par sténose de l'aqueduc de Sylvius. *Rev Neurol* 1983; 139: 349-358.
 48. KÖMPF D, OPPERMANN J, KÖNIG F, TALMON-GROS S, BABAÏAN E. Vertikale Blickpause und thalamische Demenz. Syndrom der posterioren thalamo-subthalamischen paramedianen Arterie. *Nervenarzt* 1984; 55: 625-636.
 49. BOGOUSLAVSKY J, MIKLOSSY J, DERUAZ JP, REGLI F, ASSAL G. Uni-lateral left paramedian infarction of thalamus and midbrain: A clinico-pathological study. *J Neurol Neurosurg Psychiat* 1986; 49: 686-694.
 50. DAVOUS P, BIANCO C, DUVAL-LOTA AM, DE RECONDO J, VEDRENNE C, RONDOT P. Aphasie par infarctus thalamique paramédian gauche. Observation anatomo-clinique. *Rev Neurol* 1984; 140: 711-719.
 51. TUSZINSKI MH, PETITO CK. Ischemic thalamic aphasia with pathologic confirmation. *Neurology* 1988; 38: 800-802.
 52. WATSON RT, VALENTIN E, HEILMAN KM. Thalamic neglect. Possible role of the medial thalamus and nucleus reticularis in behavior. *Arch Neurol* 1981; 38: 501-506.
 53. LAPLANE D, ESCOUROLLE R, DEGOS JD, SAURON B, MASSON H. La négligence motrice d'origine thalamique. A propos de deux cas. *Rev Neurol* 1982; 138: 201-211.
 54. BARON JC, D'ANTONA R, SERDARU M, PANTANO P, BOUSSER MG, SAMSON Y. Hypométabolisme cortical après lésion thalamique chez l'homme: étude par la tomographie à positons. *Rev Neurol* 1986; 142: 465-474.
 55. BEWERMEYER H, DRESBACH HA, RACKL A, NEVELING M, HEISS WD. Presentation of bilateral thalamic infarction on CT, MRI and PET. *Neuroradiology* 1985; 27: 414-419.
 56. FRANCK G, SALMON E, SADZOT B, VAN DER LINDEN M. Etude hémodynamique et métabolique par tomographie à émission de positons d'un cas d'atteinte ischémique thalamo-capsulaire droite. *Rev Neurol* 1986; 142: 475-479.
 57. VIADER F, CAMBIER J, LUFT A et al. Etude du débit sanguin cérébral par injection intraveineuse de Xénon 133 lors de lésions thalamiques et juxta-thalamiques. *Rev Neurol* 1987; 143: 729-736.
 58. BOGOUSLAVSKY J, FERRAZZINI M, REGLI F, ASSAL G, TANABE H, DELALOYE-BISCHOF A. Manic delirium and frontal-like syndrome with paramedian infarction of the right thalamus. *J Neurol Neurosurg Psychiat* 1988; 51: 116-119.
 59. LHERMITTE F, GAUTIER JC, MARTEAU R, CHAIN F. Troubles de la conscience et mutisme akinétique. Etude anatomo-clinique d'un ramollissement paramédian, bilatéral, du pédoncule cérébral et du thalamus. *Rev Neurol* 1963; 109: 115-131.
 60. SZIRMAI I, GUSEO A, MOLNAR M. Bilateral symmetrical softening of the thalamus. *J Neurol* 1977; 217: 57-65.
 61. HABER SN, GOENEWEGEN HJ, GROVE EA, NAUTA WJH. Efferent connections of the ventral pallidum in the rat. Evidence of a dual striato-pallidofugal pathway. *J Comp Neurol* 1985; 238: 322-335.
 62. VICTOR M, ADAMS RD, COLLINS GH. The Wernicke-Korsakoff syndrome. Blackwell, Oxford 1971.
 63. MAYES AR, MENDELL PR, MANN D, PICKERING A. Location of lesions in Korsakoff's syndrome: Neuropsychological and neuropathological data on two patients. *Cortex* 1988; 24: 367-388.
 64. MARKOWITSCH HJ. Thalamic mediodorsal nucleus and memory: A critical evaluation of studies in animals and man. *Neurosci Biobehav Rev* 1982; 6: 351-380.
 65. VON CRAMON DY, HEBEL N, SCHURI U. A contribution to anatomical basis of thalamic amnesia. *Brain* 1985; 108: 993-1008.
 66. JONES EG. The Thalamus. Plenum Press, New York 1985.