

Simultaneous Occurrence of Subarachnoid Hemorrhage and Cerebral Infarction Caused by Anterior Cerebral Artery Dissection Treated by Endovascular Trapping

—Case Report—

Tomoo INOUE, Miki FUJIMURA, Yasushi MATSUMOTO*, Ryushi KONDO*,
Takashi INOUE, Hiroaki SHIMIZU**, and Teiji TOMINAGA**

Departments of Neurosurgery and *Endovascular Neurosurgery,
Kohnan Hospital, Sendai, Miyagi;

**Department of Neurosurgery, Tohoku University Graduate School of Medicine, Sendai, Miyagi

Abstract

A 48-year-old man presented with a rare dissection of the anterior cerebral artery (ACA) causing simultaneous subarachnoid hemorrhage (SAH) and cerebral infarction manifesting as sudden onset of headache and left hemiparesis. Computed tomography and magnetic resonance imaging showed SAH localized in the interhemispheric fissure and cerebral infarction in the territory of the right ACA. Digital subtraction angiography (DSA) demonstrated segmental narrowing and dilatation at the right A₁ and A₂ portions of the ACA, leading to a diagnosis of ACA dissection. Fourteen days after the onset, DSA confirmed the enlarged fusiform dilatation of the right A₂ portion with distal narrowing, suggesting the risk of rerupture of the dissection. Endovascular obliteration of the aneurysm with parent artery occlusion was performed without anastomosis on day 16. The aneurysm was catheterized and obliterated with detachable coils. Postoperative DSA revealed complete obliteration of the dissection and parent artery. The patient was doing well without recurrence of the dissection 8 months after the intervention. The simultaneous occurrence of SAH and cerebral infarction in patients with ACA dissection is extremely rare, and the optimal treatment has not yet been established. Endovascular treatment is safe and effective for the treatment of ACA dissection.

Key words: digital subtraction angiography, dissection, endovascular treatment, cerebral infarction, magnetic resonance imaging, subarachnoid hemorrhage

Introduction

Spontaneous intracranial dissection usually affects the vertebrobasilar system,^{1,2,7,10,13,14} and is relatively rare in the anterior circulation, especially in the anterior cerebral artery (ACA).^{3,4,8,9,11,12,15} Spontaneous intracranial dissection is often associated with severe morbidity and mortality, and causes subarachnoid hemorrhage (SAH), intracranial hemorrhage, or ischemic stroke.^{9,11} Only three cases presenting with both SAH and infarction have been reported.^{4,5,15} Here, we present an unusual case of simultaneous SAH and cerebral infarction caused by dissection of the ACA, which was successfully treated by an endovascular procedure.

Case Report

A 48-year-old man was admitted with sudden onset of headache and left hemiparesis with dominance in the low-

er extremity. He had a history of arterial hypertension, but had not suffered any head injury. Hematological and laboratory examinations found no abnormality. On admission, computed tomography revealed SAH localized in the interhemispheric fissure (Fig. 1). Diffusion-weighted magnetic resonance (MR) imaging showed cerebral infarction in the territory of the right ACA (Fig. 2A) and MR angiography showed aneurysmal dilatation (Fig. 2D). Three-dimensional digital subtraction angiogram (DSA) one day after the onset demonstrated segmental narrowing and dilatation at the A₁ and A₂ portions of the right ACA (Fig. 3A), with the double lumen observed on maximum intensity projection (Fig. 3C). These findings lead to a diagnosis of dissection. The patient was initially treated conservatively by edaravone, a free radical scavenger. Two days after the onset, diffusion-weighted MR imaging showed expansion of cerebral infarction in the territory of the right ACA (Fig. 2B), and MR angiography showed progression to occlusion of the right A₂ (Fig. 2E). The patient remained neurologically stable, and the conservative treatments were continued. Diffusion-weighted MR imaging detected

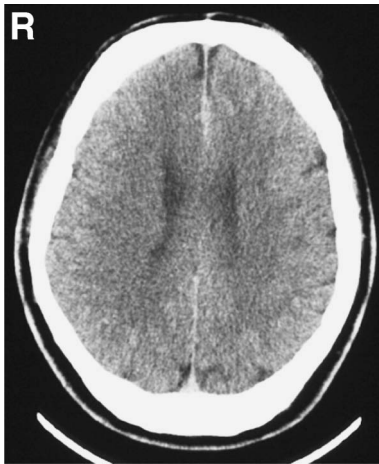

Fig. 1 Computed tomography scan showing subarachnoid hemorrhage localized in the interhemispheric fissure.

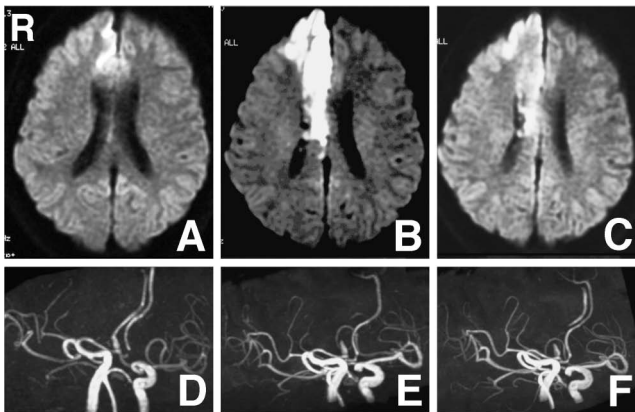


Fig. 2 Diffusion-weighted magnetic resonance (MR) image on admission demonstrating cerebral infarction in the territory of the right anterior cerebral artery (ACA) (A), and MR angiogram showing the aneurysmal dilatation (D). Diffusion-weighted MR image on day 2 demonstrating enlargement of ischemic lesion in the territory of the right ACA (B), and MR angiogram showing the right A₂ was occluded (E). Diffusion-weighted MR image on day 9 demonstrating no expansion of cerebral infarction (C), and MR angiogram showing the reperfusion of the right ACA (F).

no new lesions on day 9 (Fig. 2C), but MR angiography demonstrated the right ACA (Fig. 2F) which was not visualized on day 2 (Fig. 2E), indicating reperfusion of the right ACA. DSA confirmed the enlarged fusiform dilatation of the right A₂ portion with distal narrowing on day 14 (Fig. 3B), suggesting increasing risk for aneurysmal rupture. Based on these findings, endovascular occlusion of the aneurysm and parent artery was attempted without side-to-side anastomosis between the bilateral A₂ segments due to cerebral infarction in the right A₂ perfusion area. This procedure was performed 16 days after the onset of headache and left hemiparesis.

Transfemoral transarterial embolization of the dissec-

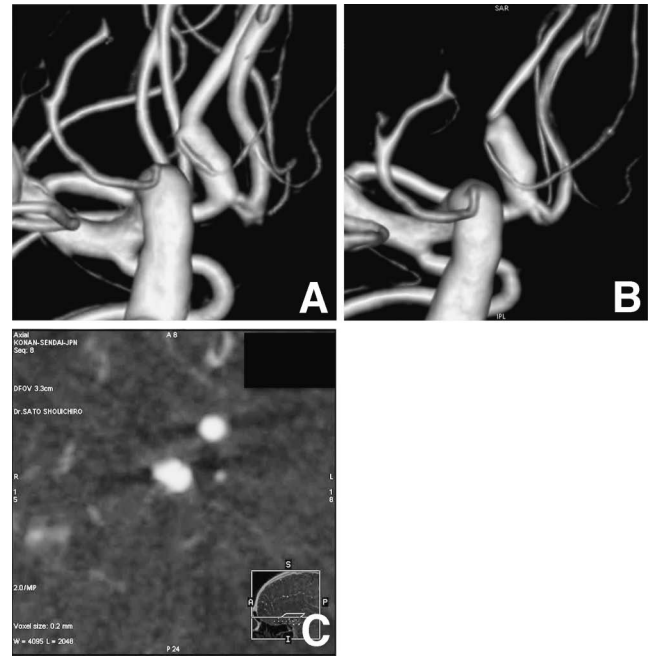


Fig. 3 Three-dimensional digital subtraction angiogram (DSA) on day 1 revealing segmental narrowing and dilatation at the right A₁ and A₂ portions of the anterior cerebral artery (A), with intensity projection scan confirming the double lumen (C). Digital subtraction angiogram on day 14 showing the enlarged fusiform dilatation of the right A₂ portion with distal narrowing (B).

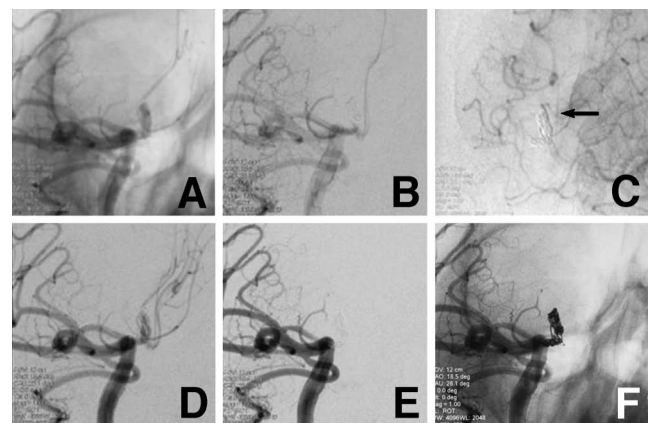


Fig. 4 Working angle view for embolization (A). The first coil formed the appropriate basket (D). After six coils were detached, the dilated portion of the dissection was almost obliterated (B). Complete obliteration of the dissection and parent artery was accomplished after 11 coils were deployed (E). The median artery of corpus callosum was not sacrificed (C, arrow). Live view after obliteration of the aneurysm indicating that the dissection and parent artery (A₁) were embolized (F).

tion was performed under both general anesthesia and heparinization. The right internal carotid artery was catheterized with a 6-French 90 cm Launcher guiding

catheter (Medtronic, Inc., Minneapolis, Minn., U.S.A.). Working angle for embolization was obtained using three-dimensional rotational angiography (Fig. 4A). An Echelon 10 microcatheter (ev3 Endovascular Inc., Plymouth, Minn., U.S.A.) was navigated into the true lumen of the dissecting aneurysm. The first coil (6 mm × 9 cm Trufill/Orbit coils; Cordis Neurovascular, Miami Lakes, Fla., U.S.A.) formed an adequate basket (Fig. 4D), and then five Ultipaq 10™ coils (Micrus, Sunnyvale, Calif., U.S.A.) were placed and detached. The dilated portion of the dissection was almost obliterated, but both the anterior communicating artery and median artery of corpus callosum still remained patent (Fig. 4B). The finding suggested the risk of rerupture, and one Guglielmi detachable coil (GDC®10-360 soft SR; Boston Scientific, Fremont, Calif., U.S.A.) and four Ultipaq 10™ coils were additionally deployed toward the proximal portion of ipsilateral A₁. Finally, right carotid angiography showed complete obliteration of the dissection and the origin of the parent artery (A₁) (Fig. 4E, F), and left carotid angiography showed patency of the median artery of the corpus callosum (Fig. 4C).

The patient remained neurologically stable after the procedure and was transferred to another hospital for rehabilitation 36 days after the admission. Eight months after the onset, he is an outpatient with mild monoparesis of the left lower extremity.

Discussion

Dissection of the intracranial arteries is rare, and about 90% of dissecting aneurysms occur in the territory of the vertebrobasilar systems.^{1,2,7,10,13,14} Intracranial dissection that involves the ACA is extremely rare, but recent advances in diagnostic modalities such as DSA and MR imaging have detected such dissection more frequently.^{3,4,8,9,11,12,15} An angiographic study of ACA dissection found arterial stenosis without dilatation occurred mainly in ischemic cases, whereas stenosis with dilatation occurred predominantly in hemorrhagic cases.^{9,11} Intracranial dissection can be divided into two types on the basis of the histological findings.¹⁶ Firstly, dissection between the internal elastic lamina and media (subintimal dissection) results in cerebral infarction caused by the stenosis or the occlusion with thrombosis of the true lumen.¹⁶ Secondly, dissection between media and adventitia (subadventitial dissection) leads to the rupture of the dissected arterial wall and hemorrhagic events.¹⁶

Previous cases of ACA dissection demonstrated similar characteristics: the patients were in middle age, serial angiographic changes were frequently detected, and almost all patients experienced good outcome.⁹ From the clinical point of view, dissection of the ACA can be categorized into three types of pathophysiology: cerebral infarction, hemorrhages such as SAH or cerebral hemorrhage, and combined types. About 60% of the patients presented with clinical manifestations of cerebral ischemia and 30% with hemorrhagic events.¹¹ Simultaneous occurrence of cerebral infarction and SAH was reported in only three cases (Table 1).^{4,5,15}

The optimum treatment of ACA dissection remains controversial, but patients presenting with ischemia are generally treated conservatively and patients with hemorrhage usually undergo surgery to prevent rebleeding.^{9,13,14} In particular, the treatment strategies are different for combined infarction and SAH (Table 1). In the combined group, both subintimal and subadventitial dissection possibly occur simultaneously due to significant hemodynamic stress to the vascular wall. The wall might spontaneously repair with collagen proliferation after the first week of onset, but the patients often suffer recurrence of infarction or hemorrhage.^{6,7} We initially treated our patient conservatively, but follow-up angiography revealed significant morphological changes of the ACA, which suggested reperfusion and hemodynamic stress to the fragile vascular wall. Therefore, we treated the dissection by endovascular trapping without bilateral A₂ bypass to prevent rerupture, as cerebral infarction in the area was fed by the right A₂, so any A₂-A₂ anastomosis would be useless. The aneurysmal dilatation was occluded by endovascular embolization with preservation of the median artery of the corpus callosum.

We recommend embolization of the ACA dissection with parent artery occlusion as a safe and a simple method to prevent rebleeding, as long as the vascular territory of the affected ACA has already become infarcted.

References

- 1) Berger MS, Wilson CB: Intracranial dissecting aneurysms of the posterior circulation. Report of six cases and review of the literature. *J Neurosurg* 61: 882-894, 1984
- 2) Chaves C, Estol C, Esnaola MM: Spontaneous intracranial internal carotid artery dissection: report of 10 patients. *Arch Neurol* 59: 977-981, 2002
- 3) Guridi J, Gállego J, Monzón F, Aguilera F: Intracerebral hemorrhage caused by transmural dissection of the anterior

Table 1 Cases of dissecting aneurysm of the anterior cerebral artery with simultaneous subarachnoid hemorrhage and infarction

Author (Year)	Age (yrs)/ Sex	Location of dissecting aneurysm	Symptoms	Treatment	Result
Yasukawa et al. (1993) ¹⁵	62/M	lt A ₂	rt hemiparesis, headache, dysarthria	bypass, surgical trapping	improved (CO)
Kato et al. (2000) ⁴	40/F	lt A ₂	rt hemiparesis, motor aphasia	medication	improved (PO)
Miyahara et al. (2001) ⁵	50/M	rt A ₂ -A ₃	lt lower limb weakness	surgical wrapping	improved (PO)
Present case	49/M	ACoA-rt A ₂	lt hemiparesis, headache	endovascular trapping	improved (CO)

ACoA: anterior communicating artery, CO: complete obliteration, PO: partial obliteration.

- cerebral artery. *Stroke* 24: 1400–1402, 1993
- 4) Kato N, Yamada Y, Hyodo A, Nose T: [A case of anterior cerebral artery dissection presenting subarachnoid hemorrhage and cerebral infarction]. *No Shinkei Geka Journal* 9: 157–161, 2000 (Japanese)
 - 5) Miyahara K, Sakata K, Gondo G, Kanno H, Yamamoto I: [Spontaneous dissection of the anterior cerebral artery presenting subarachnoid hemorrhage and cerebral infarction: a case report]. *No Shinkei Geka* 29: 335–339, 2001 (Japanese)
 - 6) Mizutani T, Kojima H, Asamoto S, Miki Y: Pathological mechanism and three-dimensional structure of cerebral dissecting aneurysms. *J Neurosurg* 94: 712–717, 2001
 - 7) Mizutani T, Miki Y, Kojima H, Suzuki H: Proposed classification of nonatherosclerotic cerebral fusiform and dissecting aneurysms. *Neurosurgery* 45: 253–260, 1999
 - 8) Mori K, Yamamoto T, Maeda M: Dissecting aneurysm confined to the anterior cerebral artery. *Br J Neurosurg* 16: 158–164, 2002
 - 9) Ohkuma H, Suzuki S, Kikkawa T, Shimamura N: Neuroradiologic and clinical features of arterial dissection of the anterior cerebral artery. *AJNR Am J Neuroradiol* 24: 691–699, 2003
 - 10) Pelkonen O, Tikkakoski T, Leinonen S, Pyhtinen J, Sotaniemi K: Intracranial arterial dissection. *Neuroradiology* 40: 442–447, 1998
 - 11) Suzuki I, Nishino A, Nishimura S, Numagami Y, Suzuki H, Utsunomiya A, Suzuki S, Uenohara H, Sakurai Y: [Nontraumatic arterial dissection of the anterior cerebral artery: six cases report]. *No To Shinkei* 57: 509–515, 2005 (Japanese)
 - 12) Thines L, Zairi F, Taschner C, Leclerc X, Lucas C, Bourgeois P, Lejeune JP: Hemorrhage from spontaneous dissection of the anterior cerebral artery. *Cerebrovasc Dis* 22: 452–456, 2006
 - 13) Yamaura A, Ono J, Hirai S: Clinical picture of intracranial non-traumatic dissecting aneurysm. *Neuropathology* 20: 85–90, 2000
 - 14) Yamaura A, Yoshimoto T, Hashimoto N, Ono J: [Nationwide study of nontraumatic intracranial arterial dissection: treatment and its result]. *Surgery for Cerebral Stroke* 26: 87–95, 1998 (Japanese)
 - 15) Yasukawa K, Kamijo Y, Momose G, Kobayashi S, Ikeda A: [A case of anterior cerebral artery dissecting aneurysm presenting subarachnoid hemorrhage and cerebral infarction at the same time]. *Surgery for Cerebral Stroke* 21: 461–466, 1993 (Japanese)
 - 16) Yonas H, Agamanolis D, Takaoka Y, White RJ: Dissecting intracranial aneurysms. *Surg Neurol* 8: 407–415, 1977

Address reprint requests to: Miki Fujimura, M.D., Ph.D., Department of Neurosurgery, Kohnan Hospital, 4–20–1 Nagamachi Minami, Taihaku-ku, Sendai 982–8523, Japan.
e-mail: fujimur@kohnan-sendai.or.jp