

Multiple mycotic aneurysms reveal *Staphylococcus lugdunensis* endocarditis in a young patient

Asmaa Tamdy, MD^{a,*}, Fedoua El Louali, MD^{a,†}, Manal Ounzar, MD^a,
Hanane Fettouhi, MD^a, Hanane Hajkacem, MD^b, Ibtissam Fellat, MD^a,
Jamila Zarzur, MD^a, Leila Sbihi, MD^b, Nawal Doghmi, MD^a, Latifa Oukerraj, MD^a,
Mouhamed Cherti, MD^a

^a Faculty of Medicine and Pharmacy, Department of Cardiology B, University Mouhamed V, Rabat, Morocco

^b Department of Radiology, University Mouhamed V, Rabat, Morocco

ARTICLE INFO

Article history:

Received 25 November 2009

Revised 09 May 2010

Accepted 21 May 2010

Online 1 August 2010

Keywords:

Mycotic aneurysm

Endocarditis

Staphylococcus lugdunensis

ABSTRACT

Mycotic aneurysms are rare, and depending on their location, can threaten functional prognosis. We report on a 17-year-old girl with no previous history of cardiovascular or infectious disease, referred to our Department of Cardiology with right hemiplegia and aphasia. A neurological evaluation revealed thrombosis of a mycotic cerebral aneurysm, complicated by ischemic and hemorrhagic infarction. Transthoracic echocardiography indicated huge, highly mobile mitral vegetation associated with a mitral regurgitation with a triple stream. Hemocultures isolated *Staphylococcus lugdunensis*. Shortly afterward, she developed bilateral tibial and pedal mycotic aneurysm. The patient received antibiotics, with minor neurological improvement initially, but she soon died because of a brain herniation. Based on our findings in this case, we discuss the features of endocarditis attributable to *S. lugdunensis*.

Cite this article: Tamdy, A., Louali, F. E., Ounzar, M., Fettouhi, H., Hajkacem, H., Fellat, I., Zarzur, J., Sbihi, L., Doghmi, N., Oukerraj, L., & Cherti, M. (2011, JULY/AUGUST). Multiple mycotic aneurysms reveal *Staphylococcus lugdunensis* endocarditis in a young patient. *Heart & Lung*, 40(4), 352-357. doi:10.1016/j.hrtlng.2010.05.048.

Staphylococcus lugdunensis is a coagulase-negative staphylococcus (CNS), first described by Freney et al in 1988.¹ It was named after Lyon (Latin adjectival form of Lugdunum), the French city where the organism was first isolated. *Staphylococcus lugdunensis* is commonly found on the human skin, and is rarely a contaminant in cultures.²

Staphylococcus lugdunensis is a relatively rare cause of endocarditis, but was previously described as causing

acute endocarditis with a very poor prognosis.³ Vandenesch et al reported a mortality rate of 70%.⁴ The first 3 cases of *S. lugdunensis* endocarditis were described in 1989.⁵ In total, 69 cases were reported up to 2005,⁶ and about three cases were reported between 2005 and 2009.^{3,7,8}

In this report, we describe a patient with native mitral valve endocarditis caused by *S. lugdunensis*, as revealed

* Corresponding author: Asmaa Tamdy, MD, Faculty of Medicine and Pharmacy, Department of Cardiology B, University Hospital Center IBN SINA, University Mouhamed V, Rabat 10000, Morocco.

E-mail address: tamyasmae@yahoo.fr (A. Tamdy).

† These authors contributed equally to this article.

0147-9563/\$ - see front matter © 2011 Elsevier Inc. All rights reserved.

doi:10.1016/j.hrtlng.2010.05.048

by the hemorrhagic rupture of mycotic cerebral aneurysms and complicated by mycotic peripheral aneurysms. Several cases in the literature involve embolic neurological complications attributable to endocarditis,⁹ but to our knowledge, this is the first observation of *S. lugdunensis* endocarditis associated with mycotic aneurysms and multiple peripheral aneurysms.

CASE REPORT

H.L., a 17-year-old girl without an individual or familial history of cardiac diseases, suffered with terrible headaches 2 weeks before her admission, with gradual right hemiplegia and aphasia. A neurological evaluation, including computed tomography (CT) and cerebral magnetic resonance imaging (MRI), identified a massive lesion of an ischemic and hemorrhagic infarction, complicating the rupture of a mycotic middle cerebral artery (MCA) aneurysm with an aneurysm of the hippocampal artery (Figures 1-4). The discovery of a mitral murmur justified her referral to the Department of Cardiology for cardiac evaluation before surgical treatment. Meanwhile, her medical treatment included synacthen and phenobarbital. Clinical examination on admission found an exhausted, febrile patient (38.2 °C), with a pulse of 120 beats per minute, blood pressure at 111/88 mm Hg, and right hemiplegia with facial involvement. Cardiac auscultation showed a 3/6 systolic mitral murmur, with its maximum at the apex, without signs of heart failure. Peripheral pulses were present and symmetrical, with spontaneous and induced pain in her left knee.

An electrocardiogram indicated a regular sinus rhythm at 90 beats/minute, without atrial or ventricular hypertrophy. A chest radiograph showed cardiomegaly (cardiothoracic ratio, 57%) with a bilateral hilar overload. Transthoracic echocardiography revealed a dilatation of the left ventricle and left atrium. A large mobile vegetation, measuring 17 mm/5 mm on the atrial side of the great mitral valve, was flopping in and out of the left atrium (Figures 5-7). Several other small vegetations were evident on both sides of this valve. A severe mitral regurgitation (MR) with a double perforation of the large and small valve arches multiple jets (Figure 7).

All blood cultures implicated *S. lugdunensis* as the causative agent. Antibiotics consisting of intravenously administered aminoglycosides (gentamycin, 80 mg per 12 hours) and oxacillin (2 g per 4 hours) were initiated. Clinical assessment did not find the origin of the microorganism. She reported a slight improvement in neurological symptoms, and remained hemodynamically stable, without fever. Six days later, she had an exacerbation of her left gonalgia. Clinical vascular testing of both lower limbs produced normal results. However, Doppler ultrasonography showed multiple, bilateral mycotic and thrombosed aneurysms in the

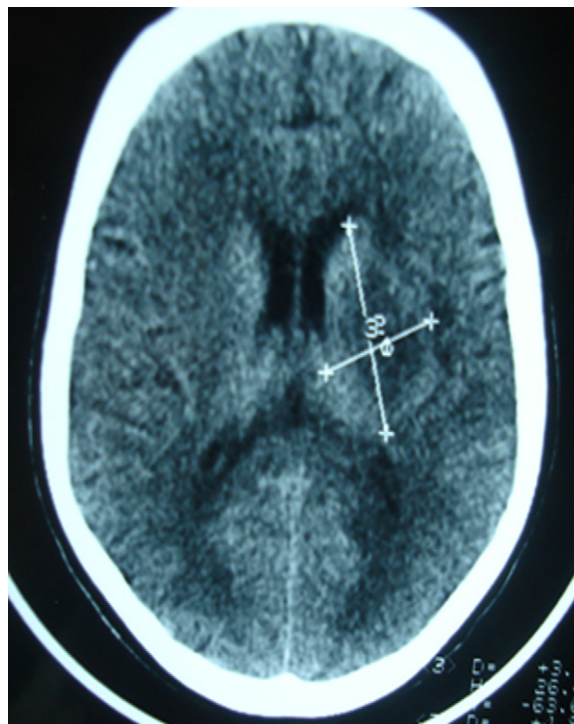


Figure 1 – Axial nonenhanced CT scan shows infarct with edema in deep territory of left MCA distribution.

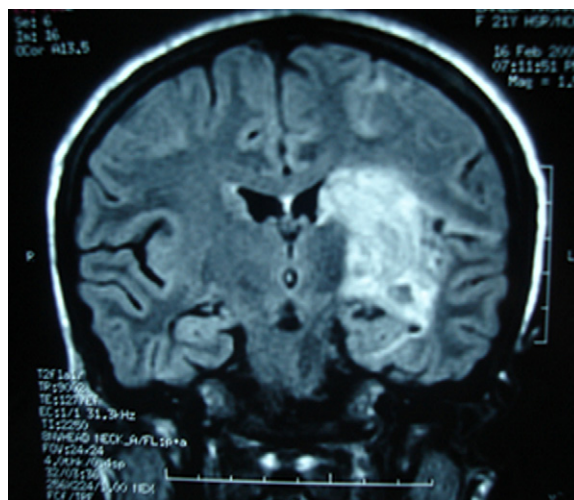


Figure 2 – Coronal MRI of the brain: T₂ flow attenuated inversion recovery sequence shows a left paraventricular hyperintense lesion, indicative of ischemic stroke with hemorrhage and edema in the deep territory of left MCA.

left pedal and popliteal arteries and the right posterior and anterior tibial arteries, without significant stenosis (Figures 8, 9). These lesions did not require urgent surgical treatment.

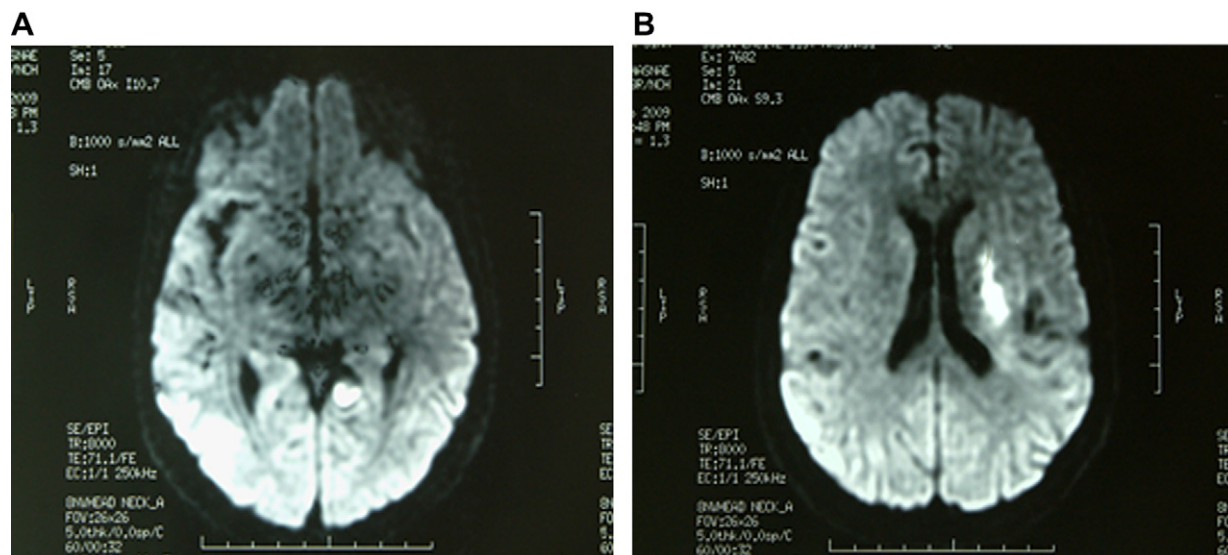


Figure 3 – Axial MRI of the brain. Apparent diffusion coefficient sequence shows hyperintense lesion in parahippocampal (A) and paraventricular (B) territory.

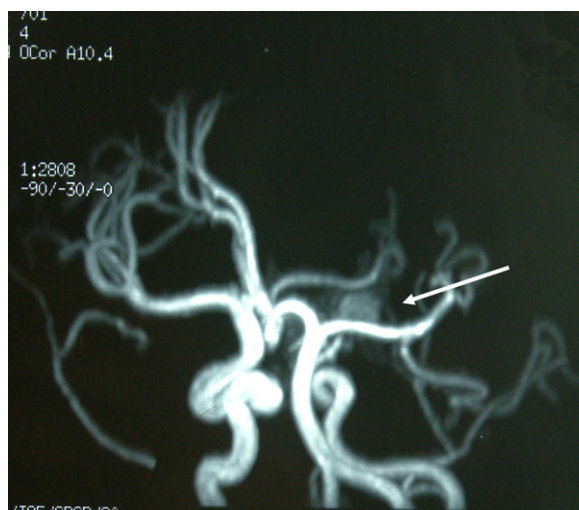

Figure 4 – Magnetic resonance angiography of cerebral arteries shows left MCA aneurysm (arrow).

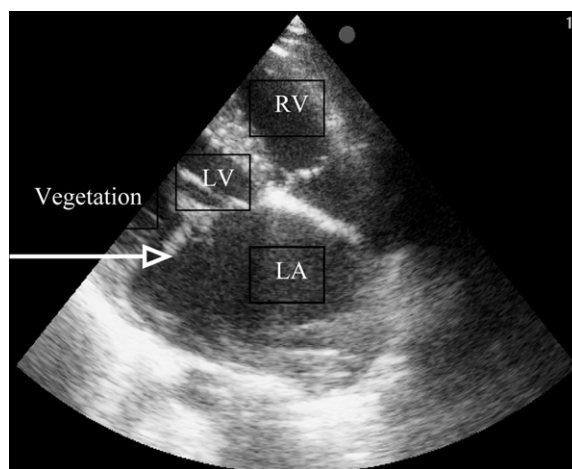


Figure 5 – Transthoracic echocardiography in apical 4-chamber view shows mitral valve vegetation. RV, right ventricle; LV, left ventricle; LA, left atrium.

Serum laboratory results showed increases in white blood cell count (from 13,800 cells/mm³ to 17,000 cells/mm³, with 87% neutrophils), sedimentation rate (35 to 67 mm/hour), and creatinine kinase protein (46 to 86 mg/L). Antibiotic therapy was switched to intravenous vancomycin 2 g per day, with gentamicin 160 mg per day. Mitral valve replacement could not be performed because of the patient's recent cerebral hemorrhagic stroke. A CT scan was performed because no improvement in neurological status was evident according to bedside examination. The CT scan identified an extension of hemorrhagic infarction of the ischemic stroke (Figure 10). Surgical intervention was indicated, but the Glasgow coma score of the patient deteriorated

quickly. Her rapid neurological decline made a surgical cure impossible. A cerebral scan indicated a worsening of the intracranial hemorrhage, with cerebral herniation (Figure 11). The patient died before an intracranial aneurysm repair could be performed. No autopsy was performed.

DISCUSSION

Since the advent of antibiotics, the incidence of mycotic aneurysm during infectious endocarditis is lower (6% of angiographic series and 10% of

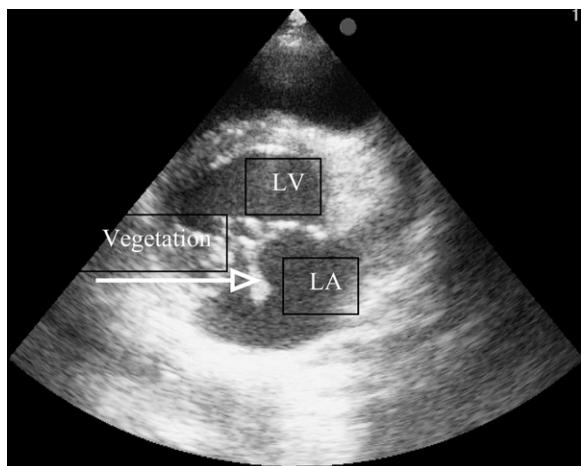


Figure 6 – Transthoracic echocardiography in parasternal short axis view shows large mitral valve vegetation. LV, left ventricle; LA, left atrium.

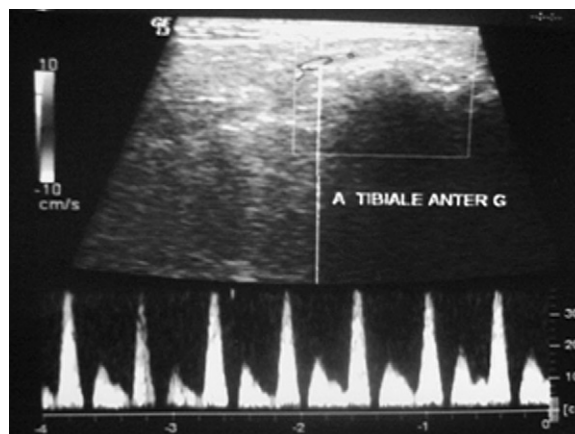


Figure 8 – Continuous Doppler ultrasonography shows acceleration of right anterior tibial flow, without significant stenosis.

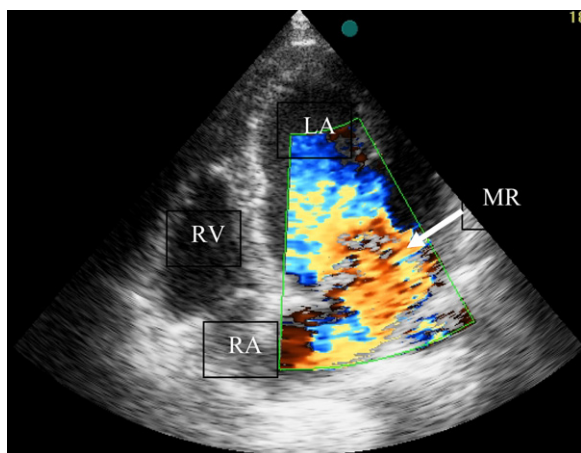


Figure 7 – Transthoracic echocardiography in apical 4 chambers shows color flow mapping of severe mitral regurgitation with multiple jets. LA, left atrium; RV, right ventricle; RA, right atrium; MR, mitral regurgitation.

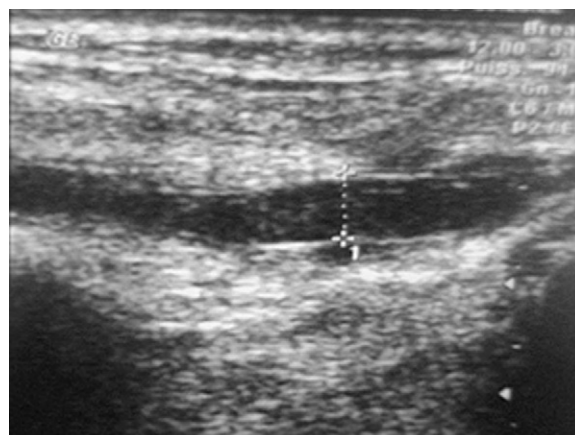


Figure 9 – Echo Doppler shows aneurysm of right anterior tibial arteries.

autopsies),¹⁰ with poor prognoses. Mortality reaches 80%.¹¹ The mechanisms of cerebral hemorrhagic in infective endocarditis include a hemorrhagic transformation of ischemic stroke, complications of septic arthritis, or the rupture of a mycotic aneurysm. *Staphylococcus lugdunensis* is an unusually virulent CNS, first identified in 1988,¹² and is known to be commensal in human skin.¹³ Although it resembles *S. aureus* in terms of a similar appearance and virulence factors, *S. lugdunensis* may be identified by the characteristic presence of ornithine decarboxylase activity.¹⁴ In a recent retrospective analysis, *S. lugdunensis* accounted for 18% of CNS causing infective endocarditis.¹⁵ Unlike other

CNS, which mainly affect the prosthetic valves, *S. lugdunensis* involves the native valves in 77% of patients described to date.⁷ To avoid missing an *S. lugdunensis* infection, Surinder et al¹⁶ recommended sequencing the 16 S ribosomal DNA specific to this bacterium for all patients presenting with endocarditis. This procedure is especially important in cases of endocarditis with negative culture, because *S. lugdunensis* is commonly missed by routine culture methodology.

Often presenting a very rapid and dramatic course, symptoms appear less than 3 weeks after the presumed exposure, with frequent appearances of valvular disruption, periannular abscess, and clinical evidence of congestive heart failure.⁷ In vitro antibiotic resistance is rare, and the most common treatment is a combination of penicillin or β -lactam with an aminoglycoside. Despite adequate antibiotic therapy, the mortality rate

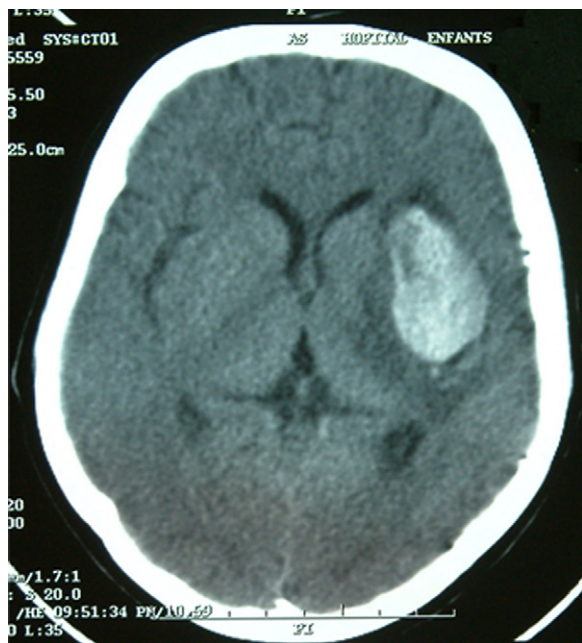


Figure 10 – Axial, nonenhanced CT scan shows hemorrhagic infarction of paraventricular infarct with edema.

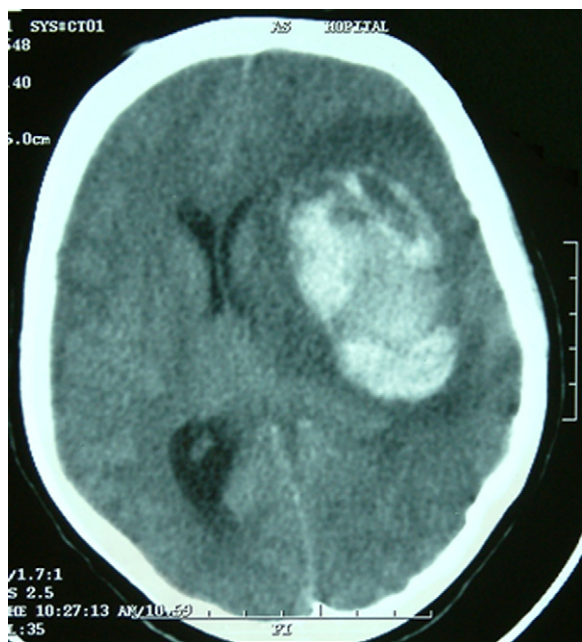


Figure 11 – Axial, nonenhanced cranial CT scan of spontaneous hyperdensity in left MCA territory suggests hemorrhagic transformation of ischemic stroke, and shows subfalcine herniation.

approaches 50%, and surgical valve replacement is currently the only measure that positively affects survival.^{6,7} Although an obvious portal of entry has not been identified in almost 50% of patients (as in our case),

the most likely appears to be the skin, and particularly the perineum. Clinical manifestations of infections because of CNS are extremely different from those of *Staphylococcus aureus*.³ In most reported cases, the clinical presentation is subtle and nonspecific, and the clinical course is more subacute or even chronic, without fulminant signs of infection.³ In our patient, neurological complications were the mode of revelation of native valves endocarditis, without an obvious portal of entry.

The management of mycotic aneurysm depends on multiple factors. Unruptured aneurysms are initially treated medically in conjunction with an angiographic survey. Ruptured aneurysms not involving eloquent vascular territory and without hematomas receive endovascular treatment. Patients with ruptured aneurysms are treated surgically when a hematoma or the risk of ischemic complications in an eloquent territory is present.¹⁷ Our patient had initially presented with a hemorrhagic infarction ischemic stroke reaching an eloquent territory. The presence of multiple aneurysms contributes one reason to proscribe surgical treatment. The patient's rapid succession of peripheral metastasis, the impossibility of achieving an urgent mitral valve replacement (attributable to hemorrhagic stroke), and the rapid worsening of her neurological status precipitated the death of the patient.

CONCLUSIONS

Staphylococcus lugdunensis endocarditis is rare, with high destructive and metastatic potential, making its prognosis unfavorable. The vague symptoms and bacteriological characteristics of this microorganism hinder its identification and delay treatment, despite its sensitivity to most antibiotics. These factors contribute to the poor prognosis.

REFERENCES

1. Freney J, Brun Y, Bes M, et al. *Staphylococcus lugdunensis* sp. nov. and *Staphylococcus schleiferi* sp. nov., two species from human clinical specimens. *Int J Syst Bacteriol* 1988;38:168-72.
2. Herchline TE, Ayers LW. Occurrence of *Staphylococcus lugdunensis* in consecutive clinical cultures and relationship of isolation to infection. *J Clin Microbiol* 1991;29:419-21.
3. Takahashi N, Shimada T, Ishibashi Y, Yoshitomi H, Sugamori T, Sakane T, et al. The pitfall of coagulase-negative staphylococci: a case of *Staphylococcus lugdunensis* endocarditis. *Int J Cardiol* 2009;137:15-7.
4. Vandenesch F, Etienne J, Reverdy ME, Eykyn SJ. Endocarditis due to *Staphylococcus lugdunensis*: report of 11 cases and review. *Clin Infect Dis* 1993;17: 871-6.
5. Etienne J, Pangon B, Leport C, Wolff M, Clair B, Perronne C, et al. *Staphylococcus lugdunensis* endocarditis. *Lancet* 1989;1:390.

6. Anguera I, Del Río A, Miró JM, Matínez-Lacasa X, Marco F, Gumá JR, et al. *Staphylococcus lugdunensis* infective endocarditis: description of 10 cases and analysis of native valve, prosthetic valve, and pacemaker lead endocarditis clinical profiles. *Heart* 2005;91:10.
7. Viganego F, Talat M, Nazir B, Ching YL, Hafnerd JP, Smith R. *Staphylococcus lugdunensis* endocarditis following lower extremity revascularization. *Int J Cardiol* 2007;116:4-6.
8. Winchester DE, Michael J. Not so innocuous. *Am J Med* 2008;121:855-7.
9. Koh TW, Brecker SJD, Layton CA. Successful treatment of *Staphylococcus lugdunensis* endocarditis complicated by multiple emboli: a case report and review of the literature. *Int J Cardiol* 1996;55: 193-7.
10. Le Bayon A, Lebourg O, Biard M. Hémorragie cérébrale par rupture d'anéurysme mycotique. *Rev Med Interne* 2002;23:469-73.
11. Brust JC, Dickinson P. The diagnosis and treatment of cerebral mycotic aneurysms. *Ann Neurol* 1990;27: 238-46.
12. Osler W. The Gulstonian lectures on malignant endocarditis. *Br Med J* 1885;1:467-9.
13. van der Mee-Marquet N, Achard A, Mereghetti L, Danton A, Minier M, Quentin R. *Staphylococcus lugdunensis* infections: High Frequency of Inguinal Area Carriage. *Clin Microbiol* 2003;41:1404-9.
14. Frank KL, Patel R. *Staphylococcus lugdunensis*: not the average coagulase-negative *Staphylococcus* species. *Clin Microbiol Newslett* 2008;30:57-61.
15. Patel R, Piper KE, Rouse MS, Uhl JR, Cockerill FR, Steckelberg JM. Frequency of isolation of *Staphylococcus lugdunensis* among staphylococcal isolates causing endocarditis: a 20-year experience. *J Clin Microbiol* 2000;38:4262-3.
16. Surinder P, Lye DC, Leo YS, Barkham T. Utility of 16S ribosomal DNA sequencing in the diagnosis of *Staphylococcus lugdunensis* native valve infective endocarditis: case report and literature review. *Int J Infect Dis* 2009;13:835-8.
17. Chun JY, Smith W, Halbach VV, Higashida RT, Wilson CB, Lawton MT. Current multimodality management of infectious intracranial aneurysms. *Neurosurgery* 2001;48:1203-13.