

## NOTE

# APRAXIA IN A PATIENT WITH LESION LOCATED IN RIGHT SUB-CORTICAL AREA. ANALYSIS OF ERRORS\*

Maria Mozaz<sup>1,3</sup>, J.F. Martí<sup>2,3</sup>, Edurne Carrera<sup>2</sup>, E. De la Puente<sup>2</sup>

(<sup>1</sup>Dpto. de Procesos Psicológicos Básicos, Facultad de la Psicología; <sup>2</sup>Dpto. de Neurología, Hospital "Nuestra Sra. de Aránzazu"; <sup>3</sup>Universidad del País Vasco, San Sebastián, Guipúzcoa, Spain)

## INTRODUCTION

Apraxia, an impairment of voluntary movements in the absence of paresis, sensory deficits, language comprehension disturbance or problems in intellectual and cognitive performance (Poock, 1985), has generally been reported in patients with lesions in the cerebral cortex.

Traditionally, apraxia has been associated with left-hemisphere lesions (Heilman and Gonzalez, 1985; Goodglass and Kaplan, 1963). However, the participation of both hemispheres in the organization of movements (Kimura and Humphrys, 1981) and the role of the right hemisphere in controlling the limbs (Wyke, 1971; Heap and Wyke, 1972; Zaidel, Zaidel and Sperry, 1975) has also been demonstrated. Byhemispheric representation of praxic functions has been corroborated by De Renzi, Motti and Nichelli (1980), Poock and Lehmkuhl (1980), Haaland and Flaherty (1984). Furthermore, several authors (e.g. Agostoni et al., 1983; Basso and Della Sala, 1986; De Renzi et al., 1986; Gonzalez Rothi et al., 1988) reported patients who suffered subcortical lesions and who showed evidence of apraxia. Only three of these patients (Agostoni et al., 1983) had lesions in the right sub-cortical areas; none of them showed apraxia for the use of objects.

The present study reports an apraxic patient with a subcortical right hemisphere infarct without cortical involvement. It describes her performance of different types of gestures and the type of errors she displayed.

## CASE REPORT

A.N. is a 74 year-old right-handed woman, who was admitted to the hospital with a 5 day history of weakness in the left side of the body and falling when getting out of bed. Past clinical history showed that she suffered from chronic gallbladder disease, peptic ulcer and hypertension. On admission she was alert but apathetic, and complained of bifrontal headache. The head and eyes were deviated to the left and she had a left-sided hemianaesthesia and hemiparesis. An EEG taken 2 days after admission showed moderate changes with slowing on the right fronto-temporal area, isolated delta wave and frequent theta wave discharges. On a CT scan taken 4 days after admission (Figure 1), there was decreased density in the right subcortical fronto-temporal area which involved the corona radiata, the anterior limb of the internal capsule, and the lenticular nucleus at the level of the head of the caudate.

A neuropsychological evaluation was performed 18 days after admission. The patient was alert but depressed. She was cooperative and able to perform the examination. There was no evidence of language impairment. She was able to follow simple and complex oral commands, could point to different parts of her body, identify and name pictures of objects, and there was no left-right disorientation. She was fairly well oriented for time, place and person. She repeated 4 digits forwards and 3 backwards. There was no clinical evidence of dementia or confusion.

Testing for apraxia was carried out on the right limb, which showed no paresis. The test

---

\* Presented at the Annual Meeting of the International Neurological Society, Belgium, July 1989.

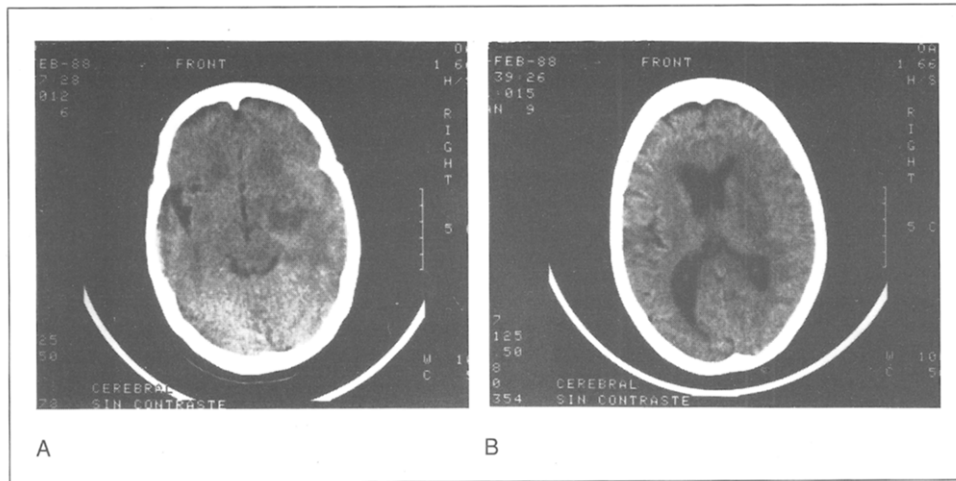


Fig. 1 (A and B) - CT scan demonstrating the right subcortical hypodense area.

followed roughly the plan proposed by De Renzi, Piezcuero and Vignolo (1966) and De Renzi et al. (1986). The patient was asked to execute the following gestures:

(1) *Ten symbolic common gestures* (e.g. salute, thumb your nose, snap your fingers...) under verbal command and then on imitation.

(2) *Imitation of ten meaningless postures* (e.g. rest chin on fist, point to left eye with right index, splay fingers palm down)

(3) *Demonstrate the use of ten objects* (e.g. brush teeth, hammer a nail, saw...) first under verbal command and then on imitation (both times without the objects). Finally, she was asked to handle the real object.

(4) *Ten oral gestures* (e.g. stick out your tongue, whistle, yawn... see De Renzi et al., 1966). The patient had to perform these movements under verbal command and on imitation.

Performance was scored on a scale from 0 to 2. Lack of response or obviously incorrect response were scored 0. A score of 1 was given for a partial response, an almost correct response, or if the patient used a body part as object. When the response was correct, a score of 2 was given. The maximum score was 20 for each subtest.

Table I contains the scores obtained by the patient. The cut-off point for symbolic common gestures (17 out of 20 on imitation) chosen by De Renzi, Piezcuero and Vignolo (1968) was used, because it has been confirmed in a Spanish control group (Mozaz, 1986). The items of our test were identical to those used by De Renzi et al. (1968) with one exception ("make

TABLE I  
*Patient's Scores on Praxis Test*

	Oral command	Imitation	Object use
1. Meaningful Movements	14/20*	17/20	
2. Meaningless Movements		18/20	
3. Object Use	14/20	16/20	15/20
4. Oral Movements	18/20	20/20	

\* The first number is the score obtained and the second the maximum score.

1. Maximum score: 20. Cut-off: 17 on imitation (De Renzi et al., 1968; Kertesz and Ferro, 1984; Agostoni et al., 1983).

2. Maximum score: 20. Cut-off: 17.

3. Maximum score: 20. Cut-off: 17 for verbal command and imitation, and 20 for real use of objects (see Agostoni et al., 1983; De Renzi et al., 1968; De Renzi et al., 1986).

4. Maximum score: 20. Cut-off: 16 (De Renzi et al., 1966; Agostoni et al., 1983).

the sign to come here" instead of "make the sign of the horns to designate a cuckold"). The patient's behaviour on performing this test on verbal command was poor, with a score of 14 out of 20. She said: "I don't know" when asked to "salute", "thumb your nose" and "snap your fingers". On imitation, she improved but her performance was not totally correct: on "salute" she applied the palm to the lateral side of the face and did not recognize the gesture when performed by the examiner; on "thumb your nose" she put her thumb in her mouth (this was scored as 1 point) while on "snap your fingers", she positioned her fingers correctly, but could not perform the movement (scored also as 1 point). Failure to recognize gestures has been described in some other reports (Heilman, Rothi and Valenstein, 1982; Gonzalez, Heilman and Watson, 1985; Ferro et al., 1983; Varney and Damasio, 1987) while the "raising into position but not doing the movement" response has been reported by Geschwind and Damasio (1985). In spite of being asked to avoid verbal comments, the patient showed vocal overflow.

According to quantitative criteria, the patient was not apraxic on the imitation of symbolic and meaningless postures. However, when demonstrating the use of objects, her performance was defective (see De Renzi et al., 1968, and Agostoni et al., 1983). For instance, she used body parts as objects (eg., used her hand as a saw or a hammer) both on command and imitation. When using real objects the patient showed a type of error that has not been reported before. This involved demonstrating the use of objects on her own body: for instance, she used a saw and a hammer on her thigh instead of an imaginary piece of wood or a nail, respectively, as if the body represented the complementary object. When handling a pencil and a tooth-brush, she took the objects and raised them into position but did not perform the gesture.

On oral gesture, the patient made only one error. She inhaled deeply in response to the oral command of yawning (a "parapraxic error" described by Sabouraud, 1976). She was, however, able to imitate all the movements correctly.

#### DISCUSSION

In this report we describe a patient with a right hemisphere subcortical lesion without cortical involvement who was apraxic. This case corroborates other findings (see Agostoni et al., 1983) and suggests that right subcortical structures may be associated with the organization of purposeful movements.

It has been suggested that subcortical apraxia might be secondary to other brain changes not detectable by CT Scan such as a diaschisis or oedema. But the fact that apraxia persists for several days or weeks after the stroke has been used as evidence to rule out this interpretation (Agostoni et al., 1983). It is also conceivable that subcortical apraxia is the outcome of interruptions of the cortico-subcortical connections. On the other hand, it has been shown that there is an ipsilateral control of voluntary movements (Wyke, 1971; Kimura and Humphrys, 1981) and also that deep neural structures can carry out functions which are normally attributed to the corpus callosum, (Sergent, 1986). This suggests the possibility that subcortical structures play a specific role in the organization of voluntary movements.

In examining the localization of the lesion in the 11 pure subcortical cases on which the side of the lesion has been reported in detail (Kertesz and Ferro, 1984, 2 cases; Basso and Della Sala, 1986, 1 case; De Renzi et al., 1986, 4 cases; Gonzalez Rothi et al., 1988, 3 cases, and the present case), it is of interest to note that the internal capsule was the only structure damaged in every case. However, it is not possible to specify which sector of the internal capsule is crucial.

The type of errors made by the patient in performing meaningful and use of objects gestures is reminiscent of an impairment of the "ideational component" of gestures, in Barbieri and De Renzi's terms (1988). "Body parts as object" (BPO) responses permit the apraxic patients to reproduce a movement outside a concrete context (Goodglas and Kaplan, 1963). According to Piaget (1950), the ability to demonstrate the use of implements is not present in children during the early stages of sensorimotor coordination. BPO responses may thus be interpreted as due to a loss of "symbolic formulation" (Ajuriaguerra, Muller and Tissot, 1960) or to a "defective propositional usage of objects" (Denny-Brown, 1958). The response "demonstrating the use of objects on one's own body" (DOB) is possibly another manifes-

tation of the same deficit. Ska and Nespoulos (1987) observed BPO responses in elderly normal subjects while Mozaz (in preparation) never found DOB responses in control subjects (40). Hence it is possible to conclude that the patient displayed a pattern of errors more akin to ideational apraxia. This reinforces the view (De Renzi et al., 1986) that subcortical regions participate in the organisation of purposeful movements and suggests that certain types of apraxic errors may be associated with subcortical structures.

#### ABSTRACT

This report describes a case of apraxia caused by a right sided sub-cortical lesion. Performance on test for apraxia was impaired. A new type of error which involved demonstrating the use of objects on one's own body is reported. Some theoretical interpretations of the findings are discussed.

*Acknowledgments.* The authors would like to thank Dr M.A. Wyke for her comments on the paper, and Dr J. Dawson (Maudsley Hospital) for interpreting the CT Scan. We would also to thank Universidad del País Vasco for their support.

#### REFERENCES

- AGOSTONI, E., COLETTI, A., ORLANDO, G., and TREDICI, G. Apraxia in deep cerebral lesion. *Journal of Neurology, Neurosurgery and Psychiatry*, 46: 804-808, 1983.
- AJURIAGUERRA, J., MULLER, M., and TISSOT, R.A. A propos de quelques problèmes posés par l'apraxia dans les démences. *L'encéphale*, 5: 775-401, 1960.
- BASSO, A., and DELLA SALA, S. Ideomotor apraxia arising from a purely deep lesion. *Journal of Neurology, Neurosurgery and Psychiatry*, 49: 458-465, 1986.
- BARBIERI, C., and DE RENZI, E. The executive and ideational components of apraxia. *Cortex*, 24: 535-543, 1988.
- DE RENZI, E., PIEZCURO, A., and VIGNOLO, L.A. Oral apraxia and aphasia. *Cortex*, 2: 50-73, 1966.
- DE RENZI, E., PIEZCURO, A., and VIGNOLO, L.A. Ideational apraxia: a quantitative study. *Neuropsychologia*, 6: 41-52, 1968.
- DE RENZI, E., MOTTI, F., and NICHELLI, P. Imitating gestures: a quantitative approach to ideomotor apraxia. *Archives of Neurology*, 37: 6-10, 1980.
- DE RENZI, E., FAGLIONI, P., SCARPA, M., and GRISI, G. Limb apraxia in patients with damage confined to the left basal ganglia and thalamus. *Journal of Neurology, Neurosurgery and Psychiatry*, 49: 1030-1038, 1986.
- DENNY-BROWN, M.D. The nature of apraxia. *The Journal of Nervous and Mental Disease*, 126: 9-32, 1958.
- FERRO, J.M., MARTINS, I.P., MARIANO, G., and CASTRO CALDAS, A. CT scan correlates of gesture recognition. *Journal of Neurology, Neurosurgery and Psychiatry*, 46: 943-952, 1983.
- GESCHWIND, N., and DAMASIO, A.R. Apraxia. In P.J. Vinken, G.W. Bruyn, H.L. Klawans (Eds.), *Handbook of Clinical Neurology, Vol 45, Clinical Neuropsychology*, 1985.
- GONZALEZ, L., HEILMAN, K.M., and WATSON, R. Pantomime comprehension and ideomotor apraxia. *Journal of Neurology, Neurosurgery and Psychiatry*, 48: 207-210, 1985.
- GONZALEZ ROTH, L.J.G., KOOISTRA, K., HEILMAN, K.M., and MACK L. Subcortical ideomotor apraxia. Abstract Poster. *Journal of Clinical and Experimental Neuropsychology*, 10: 1-48, 1988.
- GOODGLASS, H., and KAPLAN, E. Disturbance of gestures and pantomime in aphasia. *Brain*, 86: 703-720, 1963.
- HAALAND, Y.H., and FLAHERTY, D. The different types of limb apraxia errors made by patients with left vs right hemisphere damage. *Brain and Cognition*, 3: 370-384, 1984.
- HEAP, M., and WYKE, M. Learning of a unimanual motor skill by patients with brain lesions: An experimental study. *Cortex*, 8: 1-18, 1972.
- HEILMAN, K.M., ROTH, L., VALENSTEIN, E. Two forms of ideomotor apraxia. *Neurology*, 32: 342-346, 1982.
- HEILMAN, K.M., and GONZALEZ, L. Apraxia. In K.M. Heilman and E. Valenstein (Eds.), *Clinical Neuropsychology*. New York: Oxford University Press, 1985, pp. 131-150.
- KERTESZ, A., and FERRO, J.M. Lesions size and location in ideomotor apraxia. *Brain*, 107: 921-933, 1984.
- KIMURA D., and HUMPHYS, C.A. A comparison of left and right arm movements during speaking. *Neuropsychologia*, 19: 807-812, 1981.

- MOZAZ, M. Aspectos semiológicos de las apraxias de los miembros superiores. Resum de la tesi per assolir el grau de Doctor en psicología; Centre de Publicacions, Universidad de Barcelona, 1986.
- PIAGET, J. *La Construction du Réel chez l'Enfant*. Delachaux et Niestlé S.A., 1950.
- POECK, K., and LEHMKUHL, G. Ideatory apraxia in a left-handed patient with right-sided brain lesion. *Cortex*, 16: 273-284, 1980.
- POECK, K. Clues to the nature of disruptions to limb praxis. In E.A. Roy (Ed.), *Neuropsychological Studies of Apraxia and Related Disorders*. Elsevier Science Publishers, 1985, pp. 99-109.
- SABOURAUD, O.L. Du l'importance d'une boîte à outils pour examiner des malades atteints d'une lesion corticale. *Livre Jubilaire du Pro. P.F. Girard*. Lyon, 255-260, 1976.
- SERGEANT, J. Subcortical coordination of hemisphere activity in commissurotomy patients. *Brain*, 109: 357-369, 1986.
- SKA, B., and NESPOULOS, J.L. Pantomimes and aging. *Journal of Clinical and Experimental Neuropsychology*, 9: 754-766, 1987.
- VARNEY, N., and DAMASIO, H. Locus of lesion in impaired pantomime recognition. *Cortex*, 23: 699-703, 1987.
- WYKE, M. The effects of brain lesions on the performance of bilateral arm movements. *Neuropsychologia*, 9: 33-42, 1971.
- ZAIDEL, D., ZAIDEL, E., and SPERRY, R.W. Ipsilateral hand finger control in commissurotomy patients. *Biology Annual Reports*, 84. Pasadena: California Institute of Technology, 1975.

Maria Mozaz Garde, Facultad de Psicología, Universidad del País Vasco, Apto. 1249, San Sebastian, Guipúzcoa, Spain.