

Right Unilateral Spatial Neglect of the Left Brain-Damaged Patients

MASAAKI NAGAFUCHI

Division of Audiology and Speech Sciences, Faculty of Education, Tohoku University, Sendai 980

NAGAFUCHI, M. *Right Unilateral Spatial Neglect of the Left Brain-Damaged Patients.* Tohoku J. Exp. Med., 1990, **161**, Suppl., 131-138 — Right unilateral spatial neglect (USN) was investigated on three left brain-damaged patients suffering from the right homonymous hemianopsia and hemiplegia. A test battery consisted of visuo-constructive praxis; 1) putting blocks into a box, 2) bisecting a horizontal line, 3) figure drawing, 4) drawing of a dial plate and 5) copying drawing. The investigation revealed that USN of left brain-damaged patients resulted from 1) generally impaired mental function, 2) right unilateral sensory deprivation and 3) right hemiplegia. It was guessed that, as for a patient with right homonymous hemianopsia and hemiplegia, his attention would be attracted toward the left hand, and then he would be apt to neglect the right side. Right USN was not so prominent compared with the left one of right hemispheric lesion. However, it is suggested that if clinicians examine carefully the visuo-constructive function in addition to aphasia on left brain-damaged patients, right USN appears greater in some cases. ——— unilateral spatial neglect; visual spatial agnosia unilateral brain-damage; left hemisphere

The syndrome of unilateral spatial neglect (USN) consists of a tendency to neglect one half of extrapersonal space in such tasks as drawing and reading which require a symmetrical exploration of space. Hécaen (1962) reported that in his series of 59 patients with USN only one case was suffering from a left hemispheric lesion, and emphasized the relationship between USN and lesions of the right hemisphere. Gainotti (1968) attempted to study USN by means of a battery of tests simple enough to be administered to all patients, including severe aphasics. His results showed that USN is not only significantly more frequent, but also definitely more severe in patients suffering from lesions of the right hemisphere.

Costa et al. (1969) found that the incidence of USN is greater in patients with right hemispheric lesions, but that severity and patterns of deficit are alike in both right and left lesioned groups. According to Benson (1979), full anosognosia is considerably less common following left hemisphere than right hemisphere damage, possibly because the severely aphasic patient cannot readily express denial of bodily problems.

Left USN is common for right brain-damaged patients, as many investigators have reported. However, there are some cases of left brain damage showing right

USN. The purpose of the present study is aimed to show three cases with right USN of the left brain damage and to discuss them in relation to laterality of cerebral lesions.

CASE REPORTS

Cases were three left brain-damaged patients with right hemiplegia and right homonymous hemianopsia. All cases were examined with the visuo-constructive test. The test consisted of 5 parts; 1) block and box test: putting blocks into a box, 2) bisecting a line: marking the middle of a horizontal line, 3) figure drawing, 4) drawing of a dial plate and 5) copying a drawing.

Case 1.

The patient was a 37 year-old male who suffered from left brain damage due to a head injury occurring two years ago (Fig. 1). He suffered from a mild amnesic aphasia, but he

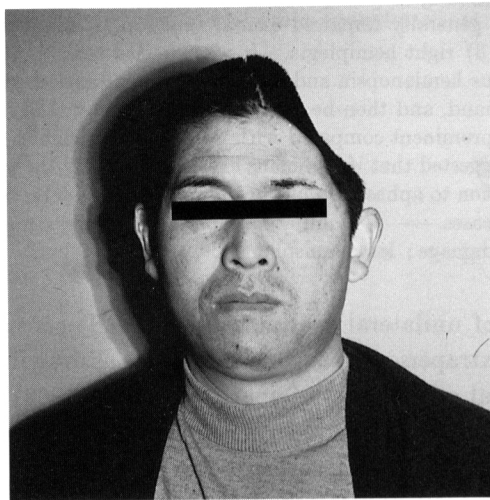


Fig. 1. Case 1 has the left head injury.

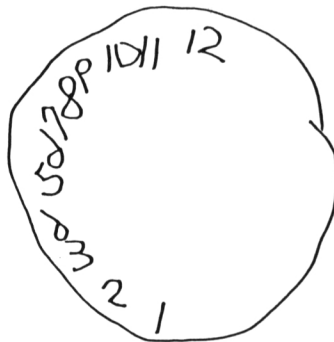

Fig. 2. The patient drew a dial plate without a model using his left hand.

could understand what to do at the test and to perform it with the left hand. Sometimes mirror writing appeared. Right homonymous hemianopsia revealed at the visual field test, but he had no trouble in daily life.

On the visuo-constructive test, he did not show any abnormality at the block and box test, bisection of a line and figure drawing. However, he showed an interesting abnormality at the drawing of a dial plate. When he was asked to draw a dial plate without a model, he neglected the right side and there were some mirror writings, 6 and 9, and a miss-spelling of 4. After finishing the drawing, he was unaware of the right side neglect and mirror writing until the mistakes were pointed out (Fig. 2).

Next, the examiner showed him the dial plate as a model and asked him to copy it. Then, he did not neglect the right side. But some mirror writing and miss-spelling still remained uncorrected (Fig. 3).

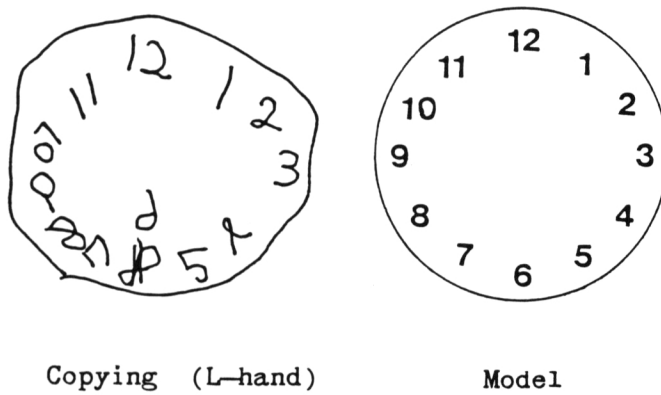


Fig. 3. The patient copied the model of a dial plate.

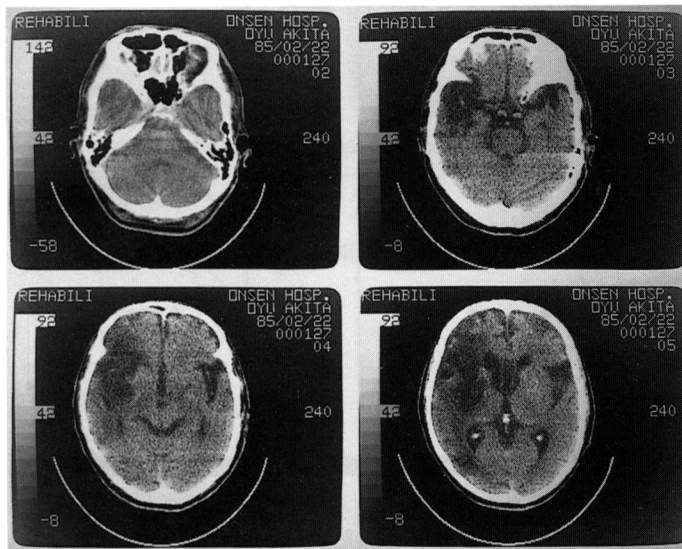


Fig. 4. CT of case 2 showed a low density area in the left front-temporal region.

His right USN appeared when he drew some pictures on command without a model. When a model was shown to him, he attended to the right side as well as the left side. At all events, his right USN was not consistent.

Case 2.

The patient was a 68 year-old male who suffered from a stroke occurring six months ago. CT showed a low density area in the anterior part of the left hemisphere. He suffered from motor aphasia, but his auditory comprehension was good (Fig. 4). In daily life, he used to neglect the right side often, especially during a meal. Left hand use was so clumsy that he was very slow in hand writing. The figure drawing (Fig. 5) took about 4 min and the copying (Fig. 6) took about 10 min.

As to figure drawing, he neglected an eyebrow and an ear on the right side. It was an incomplete USN. On the contrary, a complete right USN was revealed on copying. He succeeded on the block and box test and in bisecting the line. He often tried to look at the right side during the test. When the test was simple, it was easy for him to check the right side. But at the complex test, he tended to neglect the right side.




Fig. 5. The patient drew a face without a model using his left hand.

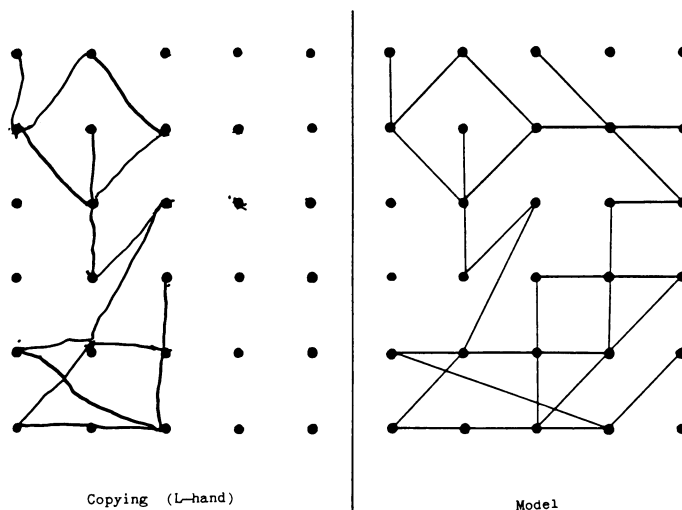


Fig. 6. The patient copied the model with his left hand.

Case 3.

The patient was a 61 year-old female. She had suffered from a stroke and mild dementia remained as sequela. CT showed a low density area in the left hemisphere (Fig. 7). She was in a state of mental deterioration one month after the stroke and the right USN was pronounced. But three months after the stroke, she began to attend to the right side. This patient was shown as a case of improvement in the right USN. As to bisection of a horizontal line, she put the bisection point at the extreme left-hand side of the line one month after the stroke. However, three months after the stroke, she put the mark further towards the right side. Fig. 9 is her figure drawing. One month after the stroke, she could draw only some small circles in the left-hand side of the large circle. Three months after the stroke, she could draw a face symmetrically (Fig. 9).

At first her right USN was pronounced, and then she consciously tried to attend to the right side. Six months after the stroke, her right USN had nearly disappeared.

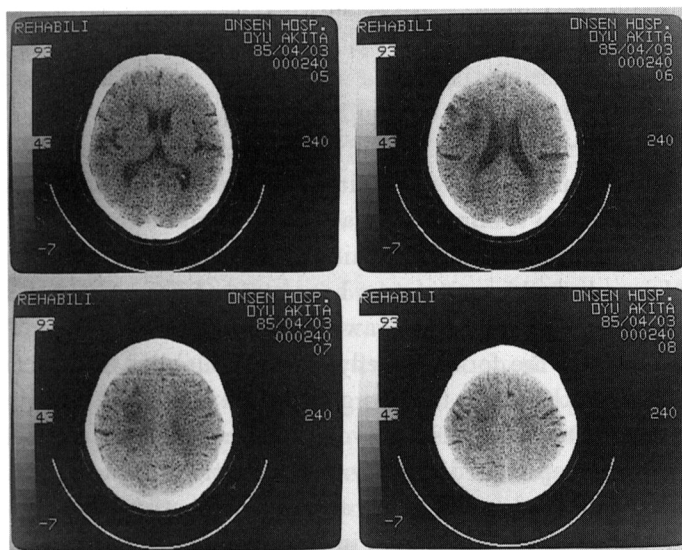


Fig. 7. CT of case 3 showed a low density area in the left putaminal region.

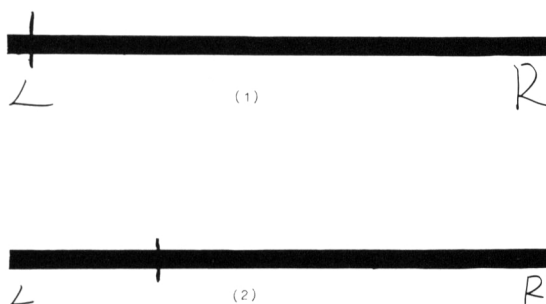


Fig. 8. The patient put the mark as the middle of the line. (1) 1 month after stroke, (2) 3 months after stroke.

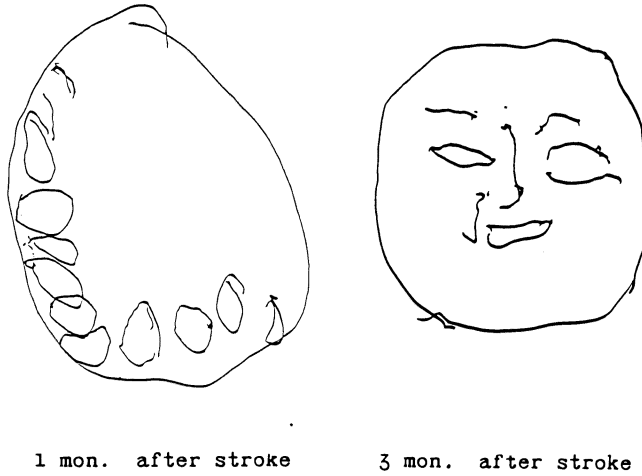


Fig. 9. The patient drew a face using her left hand.

DISCUSSION

The data of the neuropsychological literature allow us to state that unilateral spatial neglect (USN) is a syndrome characteristic of right brain damage. When similar disturbances are found in left brain-damaged patients, they are definitely less severe. Many clinical investigators have stressed the existence of clear-cut qualitative differences between the drawing disability of right and left brain-damaged patients, since the former chiefly show an inability to reproduce spatial relationships, whereas the latter tend to give coherent but simplified versions of the model. The right-sided constructive impairment has been regarded as a manifestation of "perceptive" disability, whereas the left-sided constructional apraxia has been conceived as reflecting a "motor-executive" disorder.

Table 1 shows the incidence of USN in respect of the side of the brain damage and it is agreed that the incidence is greater following right brain damage (Table 1).

Kinsbourne (1970) explained these phenomena as follows: "Patients usually think in words, and verbally communicate with the clinician. This activates the left hemisphere in most cases. It minimizes imbalance between the left and the right hemisphere when the left is damaged, amplifies imbalance with the right is damaged. Thus, clinically observed neglect is more frequent and substantive with right hemisphere lesions, because it is the resultant of the interaction between a pathologically induced hemispheric imbalance and the form taken by concurrent activity of the residual cerebrum."

Arena and Gainotti (1978) studied constructional apraxia resulting from the lesions of the right and left cerebral hemisphere. According to them, no differences were found between right and left brain-damaged patients with respect

TABLE 1. *Unilateral spatial neglect*

Reporter	Brain damage	
	Left side	Right side
Zangwill	1/ 8 (12%)	14/ 21 (67%)
Hecaen	4/206 (2%)	52/154 (34%)

to incidence and severity of visuo-constructive and visuo-perceptive disabilities. These findings suggest that the basis for visuo-constructive disturbances is a perceptual disorder, independently of the hemispheric side of lesion.

One recent study of over 100 acute stroke cases demonstrated some evidence of anosognosic phenomena in 87 percent with left paresis (right brain damage), while only about 24 percent of those with right hemiplegia had an abnormal attitude toward their paralysis (Cutting 1978). However, over half of the severe right hemiplegics were too aphasic to either admit or deny their paresis, and if all aphasics were considered to hold an abnormal attitude, the number of left brain-damaged patients in his group climbs to 81 percent (Benson 1979).

Benson (1979) suggested as follows: "If the patient tends to ignore persons on his right side, if there is a tendency to draw or to write on the left-hand side of the paper only, if close attention is paid to stimuli on the left but much stronger stimuli are needed to get attention on the right, then a significant unilateral inattention must be suspected." Left brain-damaged patients usually suffer from aphasia. That is why most clinicians examine such patients for aphasia only. If they had examined the visuo-constructive function on such patients carefully, they would have found right USN in more cases than expected.

Battersby et al. (1956) suggested that USN stems from decreased sensory input in patients with generally impaired mental function. In the present study, case 3 suffered from dementia due to stroke and her right USN was prominent at first, but it became milder gradually as the dementia improved.

Lhermitte and Beauvois (1973) reported that the combination of a severe hemianopic defect and of disease of the right parietal lobe are critical for USN. According to Heilman (1983), USN following anterior, left-sided or subcortical lesions has also been reported, but far less frequently. In the present investigation, all three cases suffered from right homonymous hemianopsia and right hemiplegia and the left anterior subcortical lesions were ascertained by CT.

As to a patient with right homonymous hemianopsia and right hemiplegia, the attention is attracted toward the left hand. That is why he is apt to neglect the right side. On the other hand, there is no neglect of the right-hand side in the case of patients who do not have right hemianopsia and right hemiplegia. Conclusively, USN of the left brain-damaged patients was derived from the following three factors; 1) mental deterioration or dementia, 2) right unilateral sensory deprivation such as somato-sensory deficit or hemianopsia and 3) right

hemiplegia.

References

- 1) Arena, R. & Gainotti, G. (1978) Constructional apraxia and visuoperceptive disabilities in relation to laterality of cerebral lesions. *Cortex*, **14**, 463-473.
 - 2) Battersby, W.S., Bender, M.B. & Pollack, M. (1956) Unilateral spatial agnosia in patients with cerebral lesions. *Brain*, **79**, 68-93.
 - 3) Benson, D.F. (1979) *Aphasia, Alexia and Agraphia*, edited by D.F. Benson, Churchill Livingstone, New York, pp. 161-162.
 - 4) Costa, L.D., Vaughan, G., Jr., Horwitz, M. & Ritter, W. (1969) Patterns of behavioral deficit associated with visual spatial neglect. *Cortex*, **5**, 242-263.
 - 5) Cutting, J. (1978) A study of anosognosia. *J. Neurol. Neurosurg. Psychiatry*, **41**, 548-555.
 - 6) Gainotti, G. (1968) Les manifestations de négligence et d'inattention pour l'hémispace. *Cortex*, **4**, 64-91.
 - 7) Hécaen, H. (1962) Clinical symptomatology in right and left hemispheric lesions. In: *Interhemispheric Relations and Cerebral Dominance*, edited by V.B. Mountcastle, John Hopkins Press, Baltimore, pp. 215-243.
 - 8) Heilman, K.M. (1983) Localization of lesions in neglect. In: *Localization in Neuropsychology*, edited by A. Kertesz, Academic Press, New York.
 - 9) Kinsbourne, M. (1970) A model for the mechanism of unilateral neglect of space. *Trans. Am. Neurol. Ass.*, **95**, 143-146.
 - 10) Lehmitte, F. & Beauvois, M.F. (1973) A visual-speech disconnection syndrome. *Brain*, **96**, 695-714.
-