

Occipital Lobe Infarction and Positron Emission Tomography

KOICHI TAGAWA, Ken NAGATA and FUMIO SHISHIDO*

Division of Neurology and Radiology Research Institute for
Brain and Blood Vessels, Akita 010*

TAGAWA, K., NAGATA, K. and SHISHIDO, F. *Occipital Lobe Infarction and Positron Emission Tomography.* Tohoku J. Exp. Med., 1990, **161**, Suppl., 139-153

— Even though the PET study revealed a total infarct in the territory of the left PCA in our 3 cases of pure alexia, it is still obscure which part of the left occipital lobe is most closely associated with the occurrence of the pure alexia. In order to elucidate the intralobar localization of the pure alexia, it is needed to have an ideal case who shows an pure alexia due to the localized lesion within the left occipital lobe. Furthermore, high-resolution PET scanner will circumvent the problem in detecting the metabolism and blood flow in the corpus callosum which plays an important role in the pathogenesis. We have shown that the occlusion of the right PCA also produced a left unilateral agnosia which is one of the common neurological signs in the right MCA infarction. To tell whether the responsible lesion for the unilateral spatial agnosia differs between the PCA occlusion and the MCA occlusion, the correlation study should be carried out in a greater number of the subjects. Two distinctive neuropsychological manifestations, cerebral color blindness and prosopagnosia, have been considered to be produced by the bilateral occipital lesion. The PET studies disclosed reduction of blood flow and oxygen metabolism in both occipital lobes in our particular patient who exhibited cerebral color blindness and prosopagnosia. ——— posterior cerebral artery occlusion; positron emission CT; pure alexia; visual and visuo-spatial agnosia

Lesions in the occipital lobe are known to cause the particular neuropsychological features in addition to the visual field defects. The dominant hemisphere lesion causes a pure alexia and color agnosia, whereas the bilateral involvement causes prosopagnosia, cerebral color blindness and/or object agnosia. The lesion in the non-dominant occipital lobe often causes a unilateral spatial agnosia. The occipital lobe is supplied by the posterior cerebral artery. By means of quantitative measurements of cerebral blood flow and metabolism utilizing the positron emission tomography (PET), the present study was endeavored to elucidate the pathophysiological mechanisms underlying the neuropsychological features due to the occlusion of the posterior cerebral artery.

Present address and reprint requests to: Koichi Tagawa, The Stroke Center, National Fukuoka-higashi Hospital, 1612 Kubo, Koga-machi, Kasuya-gun, Fukuoka 811-31, Japan.

SUBJECTS and METHODS

The present study included 7 patients with an occlusion of the posterior cerebral artery (PCA). Their ages ranged between 57 and 73 years; the mean age was 66.6 years. The left PCA was occluded in 4 patients, the right PCA was occluded in 1 patient, and both PCAs were occluded in 2 patients. Three out of 4 patients with the occlusion of the left PCA showed a pure alexia. A patient with the right PCA occlusion displayed a unilateral spatial neglect as to the right visual field. One of the two patients with the occlusion of both PCAs showed a prosopagnosia and cerebral color blindness (Tagawa 1978).

The PET was carried out with the HEADTOME III according to the oxygen-15 steady state method. Four different circulatory parameters were provided by this system: cerebral blood flow (CBF), cerebral metabolic rate of oxygen (CMRO_2), cerebral blood volume (CBV) and oxygen extraction fraction (OEF).

Pure alexia. In order to analyze the PET data for the pure alexia, 3 patients exhibiting a pure alexia (alexia group) were compared with 2 patients who did not exhibit a pure alexia in spite of an occlusion of the left PCA (non-alexia group) (Tagawa et al. 1985). Five patients with an infarct in the territory of the perforating arteries of the middle cerebral artery (MCA) were included as a control group for the PET data in the left occipital region. Their mean age was 57.6 years. Quantitative regional values were measured for CBF and CMRO_2 by placing the regions of interest (ROIs) in the left occipital lobe. The PET studies were performed in the chronic stage (later than 1 month of the onset). As shown in Fig. 1, the ROIs consisting of 135 pixels (18×30 mm) were established in each of 3 slices at 42.5, 50.0 and 57.5 mm above the orbitomeatal plane on the print-out PET images, respectively. We may call as a lower, middle and upper parts of the left occipital lobe, respectively. The regional values were calculated by averaging the pixel data at each ROI on the 3 different PET slices; regional CBF (rCBF) and regional CMRO_2 (r CMRO_2). The mean value for the occipital lobe was calculated by averaging the 3 regional values; mean CBF (mCBF) and mean CMRO_2 (m CMRO_2).

Unilateral spatial agnosia. The regional PET data were analyzed quantitatively in a patient who exhibited a left unilateral spatial agnosia due to the occlusion of the right PCA. The ROI was established at the right posterior parietal lobe which is called "a classical lesion for the unilateral spatial agnosia" on the print-out PET images. The results were compared with those obtained from the patients exhibiting a unilateral spatial agnosia due to the occlusion of the middle cerebral artery (MCA).

Prosopagnosia and cerebral color blindness. The distribution of the ischemic lesions was demonstrated by the PET studies in a patients who exhibited a prosopagnosia and cerebral color blindness.

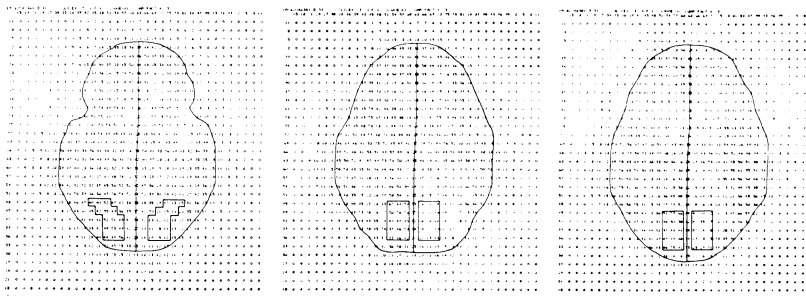


Fig. 1. Location of the regions of interest (ROIs) on the print-out PET data. The mean of the ROI values from the 3 slices served the occipital regional values.

RESULTS AND DISCUSSION

Pure alexia

Table 1 shows the rCBF and rCMRO₂ in the alexic group. Table 2 summarizes the PET data in 3 groups. Fig. 2 illustrates the relationship between the left occipital mCBF and mCMRO₂ among the alexic, nonalexia and control groups. The left occipital mCBF was 18.4 ± 2.2 (ml/100 ml/min) and the mCMRO₂ was 1.68 ± 0.11 (ml/100 ml/min) in the alexic group. In the control group, the left occipital mCBF and mCMRO₂ were, 43.0 ± 3.5 and 3.10 ± 0.18 , respectively. Both mCBF and mCMRO₂ of the left occipital lobe were significantly lower in the alexic group than in the control group ($p < 0.01$). The right occipital mCBF and mCMRO₂ were 36.0 ± 9.0 and 3.17 ± 0.58 in the alexic group, respectively, while they were 40.8 ± 3.6 and 3.00 ± 0.15 in the control group, respectively. No significance was found for the right occipital mCBF or mCMRO₂ between the two group.

In the control group, the rCBF and rCMRO₂ in the lower part of the left occipital lobe were 38.1 ± 4.4 and 2.82 ± 0.26 , respectively. Those of the middle part were 42.6 ± 2.7 and 3.08 ± 0.34 , respectively and those of the upper part were 41.6 ± 6.2 and 3.10 ± 0.38 , respectively. The similar regional data were obtained for the right occipital lobe. There was no predirection for the distribution of the rCBF or rCMRO₂ within the occipital lobe in the control group. In the alexic group, the rCBF and rCMRO₂ in the lower part of the left occipital lobe were 16.6 ± 3.4 and 1.49 ± 0.25 , respectively. Those of the middle part were, 18.8 ± 1.6 and 1.79 ± 0.21 , respectively, and those of the upper part were 19.7 ± 7.0 and 1.77 ± 0.51 , respectively. The rCBF and rCMRO₂ of the lower part of the right

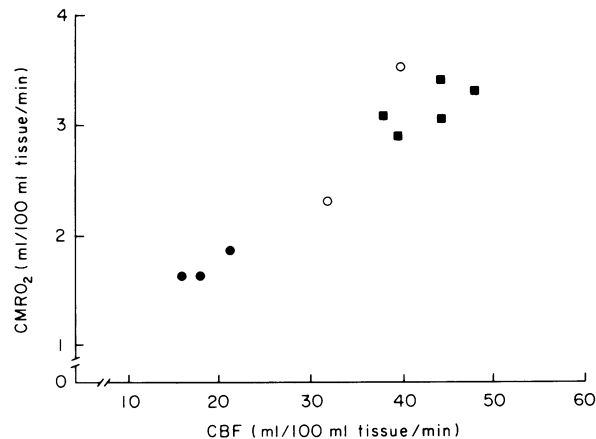


Fig. 2. Relationship between regional CBF and CMRO₂ in the left occipital lobe. Both CBF and CMRO₂ were lower in those with pure alexia than those without pure alexia. ●, left PCA occlusion with pure alexia; ○, left PCA occlusion without pure alexia; ■, control left basal ganglia infarction.

TABLE 1. *CBF and CMRO₂ in the occipital lobe in patients with pure alexia*

| Case | CBF (ml/100 ml tissue/min) | | | | CMRO ₂ (ml/100 ml tissue/min) | | | |
|------|----------------------------|--------|-------|------|--|--------|-------|------|
| | Lower | Middle | Upper | Mean | Lower | Middle | Upper | Mean |
| 1 | Left | 13.3 | 21.0 | 29.5 | 21.3 | 1.19 | 1.85 | 2.49 |
| | Right | 48.3 | 49.3 | 48.2 | 48.6 | 3.83 | 4.07 | 3.89 |
| 2 | Left | 15.3 | 18.3 | 14.0 | 15.9 | 1.46 | 2.01 | 1.33 |
| | Right | 23.9 | 27.6 | 32.9 | 28.0 | 2.13 | 2.67 | 2.76 |
| 3 | Left | 21.21 | 17.1 | 15.6 | 18.0 | 1.81 | 1.51 | 1.49 |
| | Right | 35.1 | 29.5 | 29.5 | 31.4 | 3.41 | 2.90 | 2.86 |

TABLE 2. *Comparison of CBF and CMRO₂ in the occipital lobe among 3 groups*

| Patient group | n | Mean age (year) | CBF (ml/100 ml tissue/min) | | | | CMRO ₂ (ml/100 ml tissue/min) | | | |
|---|---|-----------------|----------------------------|--------|-------|------|--|--------|-------|-------------|
| | | | Lower | Middle | Upper | Mean | Lower | Middle | Upper | Mean |
| I Left PCA occlusion with pure alexia | 3 | 68.7 | Left | 16.6 | 18.8 | 19.7 | 18.4 ± 2.2 | | 1.49 | 1.77 |
| | | | | 35.8 | 35.5 | 36.9 | 36.0 ± 9.0 | | 3.12 | 3.17 |
| II Left PCA occlusion without pure alexia | 2 | 63.0 | Left | 36.9 | 34.2 | 36.9 | 36.0 ± 4.1 | | 2.95 | 2.86 |
| | | | | 41.5 | 45.5 | 41.9 | 43.0 ± 3.5 | | 2.97 | 3.01 |
| III Left basal ganglia infarction | 5 | 57.6 | Right | 38.1 | 42.6 | 41.6 | 40.8 ± 3.6 | | 2.82 | 3.10 |
| | | | | | | | | | | 3.00 ± 0.15 |

occipital lobe were 35.8 ± 10.0 and 3.12 ± 0.72 , respectively. Those of the middle part were 35.5 ± 9.8 and 3.21 ± 0.61 , respectively, and those of the upper part were 36.9 ± 8.1 and 3.17 ± 0.51 , respectively. There was no specific tendency for the distribution of the rCBF or rCMRO₂ within the occipital lobe in this study.

One of the two patients who did not display an alexia in spite of the occlusion of the left PCA showed their mCBF and mCMRO₂ between those of the alexic group and those of the control group. This patient exhibited only a right homonymous hemianopsia. The mCBF and mCMRO₂ in the other patient who did not have a visual field defect were as high as those in the control group. In this patient, the x-ray CT showed that the infarct area was localized in the lower part of the left temporal lobe which was within the left PCA territory.

Summarizing the quantitative data derived by the PET studies in the patients with pure alexia, there was a significant reduction of both mCBF and mCMRO₂ of the left occipital lobe as compared with those of the other side. They were 51.1% and 53.0% of those of the right occipital lobe, respectively. As compared with the control group, there was a severe decrease of mCBF and mCMRO₂ of the left occipital lobe in the alexic group; the mCBF and mCMRO₂ were 42.8% and 54.2% of those of the control group, respectively.

No specific tendency was extracted from the occipital intra-lobar distribution of the rCBF or rCMRO₂ within the alexic intra-lobar distribution of the rCBF or rCMRO₂ either within the alexic group, or as compared with the control group. One of the two patients who did not exhibit a pure alexia in spite of the PCA occlusion showed his mCBF and mCMRO₂ between those of the alexic group and those of the control group. The other patient showed the mCBF and mCMRO₂ as high as those in the control group.

The pure alexia in which the reading ability was severely disturbed relative to the intact writing ability generally thought to be caused by the lesions in the left occipital lobe and the splenium of the corpus callosum, which areas were irrigated by the left PCA. Therefore, the pure alexia is frequently seen with the occlusion of the left PCA. The occlusion of the left PCA, however, does not always cause the pure alexia. Whether the pure alexia is present or not in the patient with occlusion of the left PCA is considered to depend upon the extension of the ischemic lesion and the development of the collateral circulation may play an important role in the genesis of the pure alexia (Tagawa et al. 1978). In the results of the present study with the PET studies which provided quantitative aspects of blood flow and metabolism, both blood flow and oxygen metabolism were markedly reduced in the left occipital lobe in the alexic group as compared with those with normal reading in spite of the PCA occlusion or with the control group including those with the basal ganglionic small infarcts. This indicates that a complete occlusion of the left PCA at its origin with a poor collateral circulation may produce a severe form of pure alexia.

It has been accepted that the lesion of the callosal splenium in addition to the

lesion of the inferior medial aspect of the left occipital lobe causes a pure alexia. Based on the pathological findings of 17 cases who exhibited this syndrome, Benson and Geschwind (1969) reported that, in addition to the callosal lesions, the occipital lesions located at the left lingual gyrus and/or the left fusiform gyrus with an expansion to the left cuneus and the left calcarine cortex by a various degree. Although they did not asserted that the callosal lesion was indispensable for the occurrence of the pure alexia, they concluded that there had been so far no other reported lesion than the left occipital lobe lesion and the callosal splenium that could cause a pure alexia. Greenblatt (1983) confirmed the same lesions responsible for the pure alexia in 10 autopsied cases. Recently, on the other hand, Greenblatt (1976) reported that subcortical lesions adjacent to the left angular gyrus caused a pure alexia. There is still a controversy about the responsible lesion for the pure alexia. It should be clarified with new diagnostic devices whether a even localized lesion can produce a severe form of pure alexia or extensive lesion can only cause a severe form of this syndrome. However, the results of the PET studies could not bring a conclusion to this question because the detection of the blood flow or metabolism in the corpus callosum was still beyond of the resolution of PET studies. Until now it is difficult to detect the regional values of CBF or $CMRO_2$ in the lingual gyrus or in the fusiform gyrus by the present procedure. It is needed to elucidate the intra-lobar localization with the PET studies in respect to the severity of pure alexia by accumulating of the

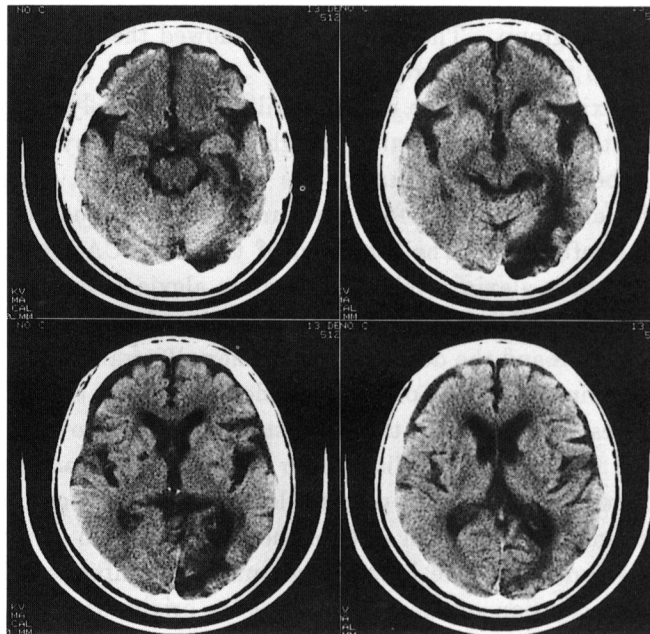


Fig. 3. CT findings of a patient with pure alexia. An extensive low density area is shown in the territory of the left PCA.

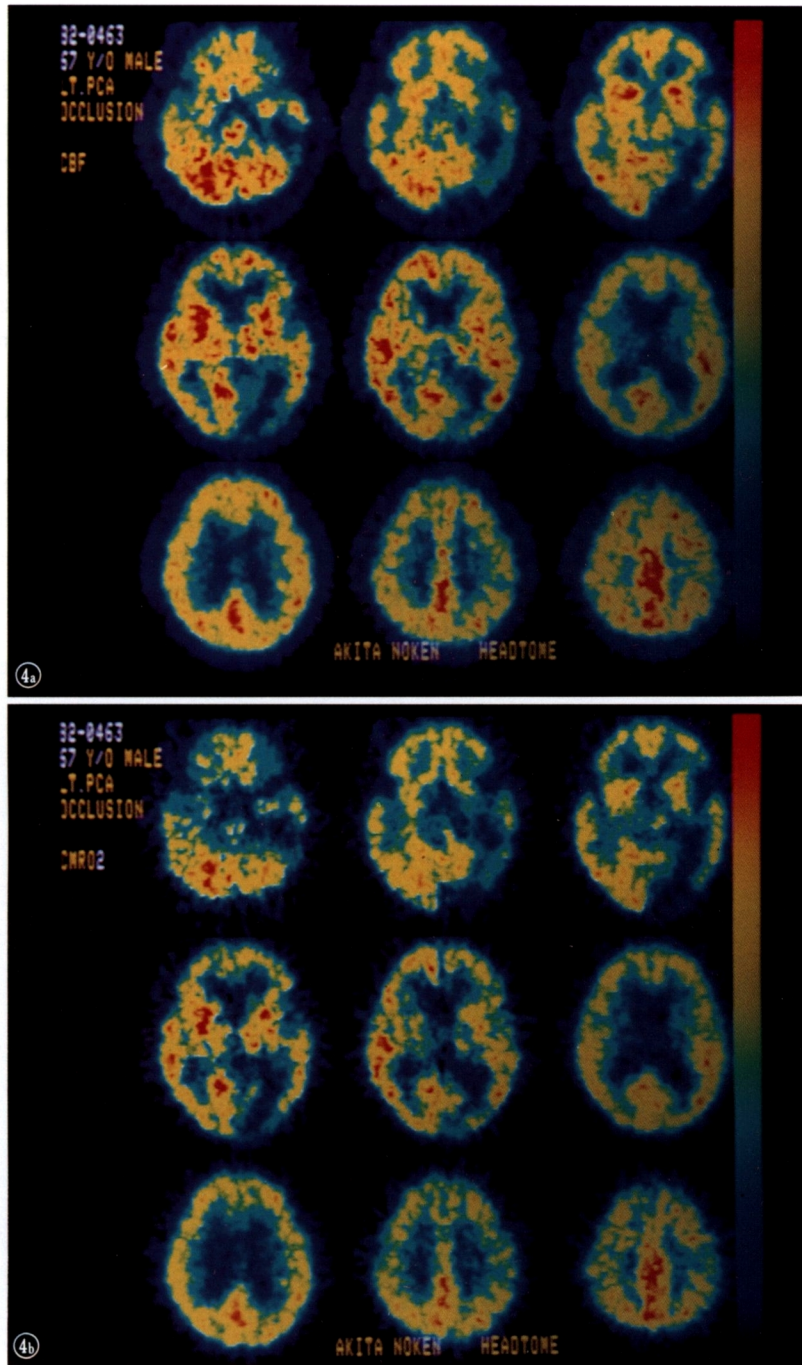


Fig. 4. PET findings of a patient with pure alexia. CBF images (a); CMRO₂ images (b). Corresponding to the CT lesion, both CBF and CMRO₂ were reduced markedly in the territory of the left PCA.

cases and improving of in ROI setting.

Illustrative case report. A 67-year-old right-handed man noticed a numbness in his right hand on March 3, 1982. There had been a progression in his neurological deficits and he became right hemiparetic with a right hemihypesthesia in a week. Then he complained of difficulty in seeing thing on his right side. He was hospitalized on March 18. On admission, he exhibited a right homonymous hemianopsia and a mild right hemiparesis with a right hemihypesthesia accompanied by a paresthesia. He also showed a severe impairment in reading, a mild sensory aphasia and color naming difficulty. Vertebral angiography revealed an occlusion of the left PCA at the crural segment. The x-ray CT showed a extensive low density area in the territory of the left PCA. After admission, he showed a rapid improvement in the aphasia and the motor and sensory disturbance. The neuropsychological evaluation performed after the recovery from the aphasia disclosed a severe form of pure alexia and a color agnosia. The reading was severely impaired for both Kanji and Kana at the level of letter, word and sentence and he was unable to carry out practical reading. Although his spontaneous writing or dictation were normal, the copying was

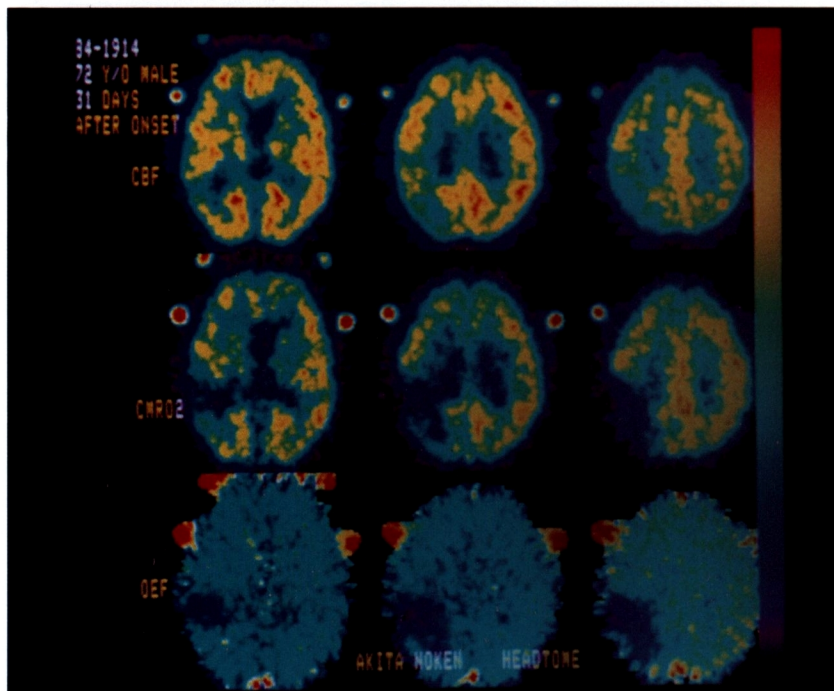


Fig. 5. PET findings of a patient exhibiting a left unilateral spatial agnosia due to the infarct in the territory of the right MCA. CBF images (top), $CMRO_2$ (middle) and OEF images (bottom). Both CBF and $CMRO_2$ were reduced at the junctional area among the temporal, parietal and occipital lobes on the right hemisphere.

severely impaired. There was no significant effects from the motor facilitation in reading (kinesthetic reading). The color naming difficulty disappeared within 3 months of onset. There was no change in the right homonymous hemianopsia throughout. His neuropsychological features has been followed for 4 years but the practical reading had not improved yet and he still exhibited a severe pure alexia. The PET studies performed 21 months after the onset disclosed a reduction of CBF and CMRO_2 in the territory of the left PCA, which corresponded to the lesion on the x-ray CT (Figs. 3, 4).

Left unilateral spatial agnosia

Fig. 5 shows the PET findings in a patient with left unilateral spatial agnosia due to the infarct in the right MCA territory. There was a reduction of CBF and CMRO_2 at the junctional area among the temporal, parietal and occipital lobes on the right hemisphere, which is known to be the classical lesion responsible for the left unilateral spatial agnosia. Fig. 6 shows a distribution of rCBF and r CMRO_2 measured at the posterior part of the right parietal lobe in 16 occasions in 11 patients with left unilateral spatial agnosia (Tagawa et al. 1986). When they were compared with those without left unilateral agnosia, the distribution of the two groups overlapped between 25 and 35 ml/100 ml/min for rCBF, and between 1.8 and 2.2 ml/100 ml/min for r CMRO_2 . The values around these levels were considered to be the threshold for the occurrence of the left unilateral spatial

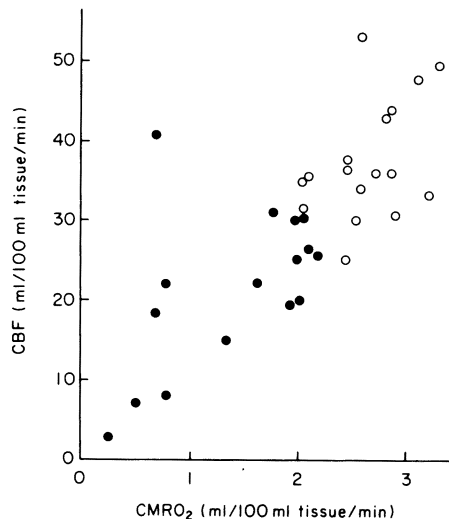


Fig. 6. Relationship between regional CBF and CMRO_2 in the posterior part of the right parietal lobe. Both CBF and CMRO_2 were lower in those with unilateral spatial agnosia than in the control group. The distribution of the two patient groups coexisted between 25 and 35 ml/100 ml/min for CBF, and between 1.8 and 2.2 ml/100 ml/min for CMRO_2 . ○, control; ●, unilateral spatial agnosia.

agnosia. Since the CBF values may vary according to the stage of cerebral infarction because of the luxury perfusion phenomenon, the CMRO_2 that is stable in the course of cerebral infarction can be the reliable indicator for brain function. The CMRO_2 below 2.0 ml/100 ml/min is considered to cause a left unilateral spatial agnosia. These results were compared with the PET findings in a patient who exhibited a left unilateral spatial agnosia due to the occlusion of the right PCA in respect to the pathogenetic mechanism of the left unilateral spatial agnosia.

Illustrative case report. A 61 year-old right-handed man became unable to return to his bedroom when he went to the restroom on October 4, 1983. He was hospitalized on October 7. On admission, the neurological examination revealed a left homonymous hemianopsia, a topographical disorientation and a left unilateral spatial agnosia. The vertebral angiography disclosed an occlusion of the right PCA at the ambient segment. Extensive infarct was seen at the right occipital lobe on x-ray CT (Fig. 7). The PET studies performed 13 days after onset showed a marked reduction of both CBF and CMRO_2 in the territory of the right PCA (Fig. 8). At the junctional area among the temporal, parietal and occipital lobes on the right hemisphere, the rCBF was 31.3 ml/100ml/min, which was included in the threshold range for the occurrence of the unilateral spatial agnosia, whereas the r CMRO_2 was 2.61 ml/100 ml/min, which was above the

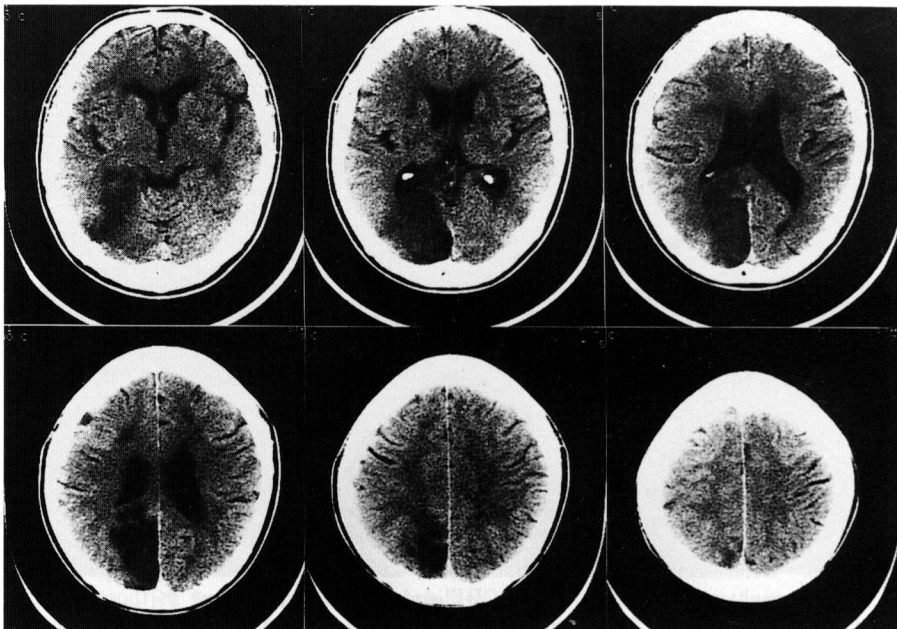


Fig. 7. CT findings of a patient with a left unilateral spatial agnosia due to the occlusion of the right PCA. An extensive infarct was seen in the right occipital lobe.

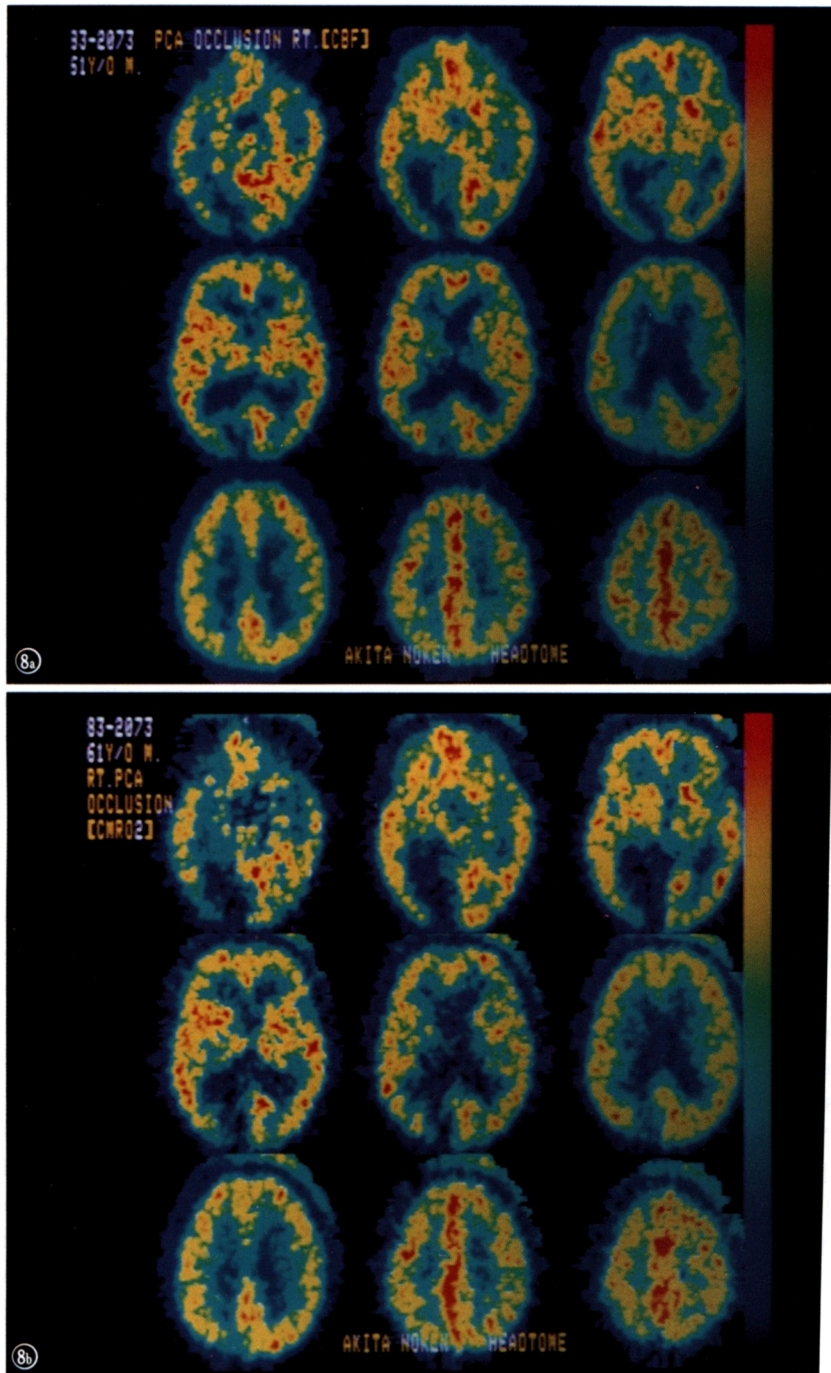


Fig. 8. PET findings in a patient with a left unilateral spatial agnosia due to the occlusion of the right PCA. CBF images (a); CMRO₂ images (b). Both CBF and CMRO₂ were markedly reduced in the territory of the right PCA.

threshold level.

The responsible lesion for left unilateral spatial agnosia has been believed to be located at the junctional area among the temporal, parietal and occipital lobes or the area between the parietal and occipital lobes on the right hemisphere (Brain and Domasio 1941; Paterson and Zangwill 1944). Since these areas are included in the right MCA territory, those patients who has an infarct in the territory of the right MCA frequently develop a left unilateral agnosia. In addition, a subcortical hemorrhage at the junctional area also may be causative of the left unilateral spatial agnosia and even a right putaminal hemorrhage which has an effect on the junctional area also causes a left unilateral spatial agnosia. Furthermore, a right frontal lobe lesion, an occlusion of the right PCA, a right thalamic hemorrhage and an occlusion of the right anterior choroidal artery were reportedly causative for the left unilateral spatial agnosia.

We previously reported a patient who displayed a left unilateral spatial agnosia due to the occlusion of the right PCA (Tagawa et al. 1978). The single photon emission CT (SPECT) was carried out on another patient with reference to the pathogenetic mechanism of the left unilateral spatial agnosia in the right PCA occlusion (Tagawa et al. 1982). Although the junctional area among the temporal, parietal and occipital lobe is in general considered to belong to the territory of the posterior branch of the MCA, this area can be also regarded as a border zone between the MCA territory and the PCA territory. Even if the MCA was occluded, the junctional area can be preserved and the left unilateral spatial agnosia does not occur when the collateral blood flow is sufficient from the PCA. In those with left unilateral spatial agnosia due to the occlusion of the right MCA, an occlusion of the MCA is the crucial factor in causing the left unilateral spatial agnosia but the poor collateral circulation from the PCA can be also the important factor from the hemodynamic point of view. In case with an occlusion of the PCA, the area supplied by the cortical branch can be preserved when the collateral blood flow is sufficient from the MCA. There is a possibility that the junctional area between the MCA and PCA became ischemic in a case with an occlusion of the PCA when the collateral blood flow is poor from the MCA. The SPECT study revealed an ischemic lesion at the border zone area between the right MCA and the right PCA territory in the patient who showed a left unilateral spatial agnosia with an occlusion of the right PCA. If it can be substantiated that an infarct occurs at the junctional area among the temporal, parietal and occipital lobes when the collateral blood flow is poor from the MCA in a case with an occlusion of the PCA, the classical lesion may account for the left unilateral spatial agnosia in a patient with an occlusion of the right PCA. In the present results with PET studies, however, the rCBF decreased as the threshold level whereas the rCMRO₂ was still preserved above the threshold level at the junctional area among the right temporal, parietal and occipital lobes. The left unilateral spatial agnosia due to the occlusion of the right PCA may differ from

that due to the right MCA occlusion in the deeper lesion involving the connecting fibers. The reduction of CBF at the classical region might participate at least in the genesis of the left unilateral spatial agnosia in our patient. Further systematic study is needed with a larger number of the subjects to elucidate the pathophysiological differences of the left unilateral spatial agnosia between the right PCA and the right MCA.

Cerebral color blindness and prosopagnosia

Illustrative case report. A 67-year-old ambidextrous man complained of difficulty in recognizing the faces of the familiar person and he often lost his way to his home when he went out in April, 1983. He complained of a visual disturbance and he was hospitalized on July 4, 1983. On admission, close examination disclosed a concentric restriction of the whole visual field and his visual acuity was mildly decreased in both fields. He exhibited a severe memory disturbance, prosopagnosia, color blindness and topographical disorientation. Color naming, color sorting and color matching were severely impaired. He also showed difficulties in coloring of outline drawings. Ishihara screening test and hue discrimination were severely abnormal. The cerebral angiography revealed a complete occlusion of the right PCF and the left PCA territory was poorly visualized. There were low density areas in both occipital lobes on CT (Fig. 9).

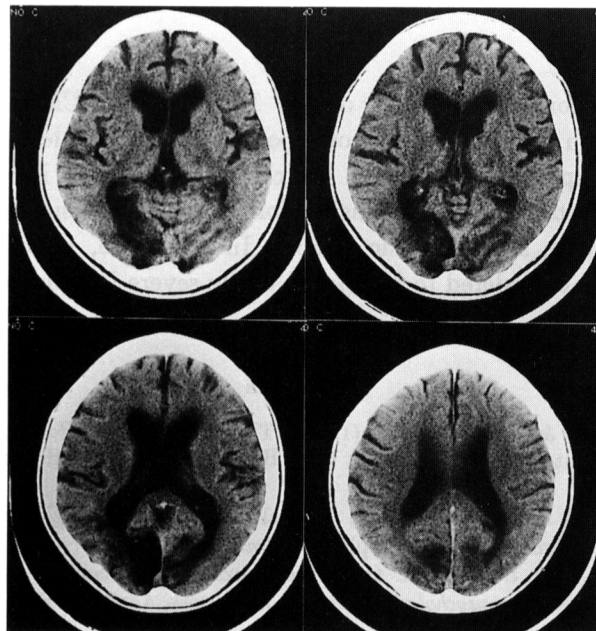


Fig. 9. CT findings of a patient with cerebral color blindness and prosopagnosia due to the infarction of both PCA territories. Low density areas were demonstrated in both occipital lobes.

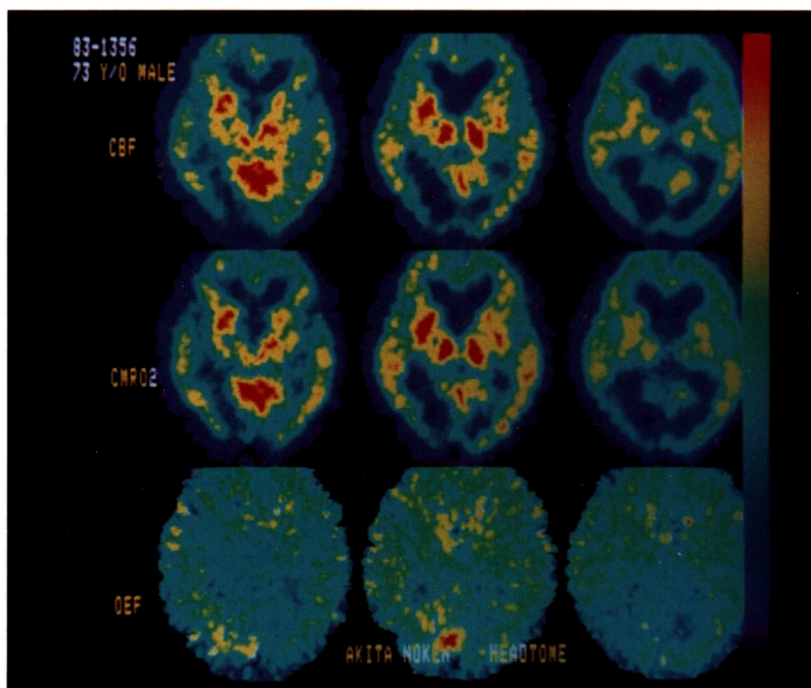


Fig. 10. PET findings of a patients with cerebral color blindness and prosopagnosia. CBF images (top), CMRO₂ images (middle) and OEF images (bottom). Reduction of CBF and CMRO₂ was marked in both PCA territories.

The PET was performed 9 day after onset. Both CBF and CMRO₂ were markedly reduced in both PCA territories corresponding to the CT lesions (Fig. 10).

It has been speculated based on the clinicopathological investigations that the bilateral occipital lesion is responsible for the prosopagnosia and cerebral color blindness (Damasio and Damasio 1983). In this case, color blindness and prosopagnosia are considered to be related to the severe ischemic damage in both PCA territories.

References

- 1) Benson, D.F. & Geschwind, N. (1969) The alexias. In: *Handbook of Clinical Neurology*, edited by P.J. Vinken & G.W. Bruyn, Vol. 4, North-Holland, Amsterdam, pp. 112-140.
- 2) Brain, A.R. & Damasio, A. (1941) Visual disorientation with special reference to lesion of the right cerebral hemisphere. *Brain*, **64**, 244-272.
- 3) Damasio, A.R. & Damasio, A. (1983) Localization of lesions in achromatopsia. In: *Localization in Neuropsychology*, edited by A. Kertesz, Academic Press, New York, pp. 417-428.
- 4) Greenblatt, S.H. (1976) Subangular alexia without agraphia or hemianopsia. *Brain Lang.*, **3**, 229-245.
- 5) Greenblatt, S.H. (1983) Localization of lesion in alexia. In: *Localization in*

- Neuropsychology*, edited by A. Kertesz, Academic Press, New York, pp. 323-356.
- 6) Paterson, A. & Zangwill, O.L. (1944) Disorders of visual space perception associated with lesions of the right cerebral hemisphere. *Brain*, **67**, 331-358.
 - 7) Tagawa, K. (1978) Neurological, neuropsychological and neuroradiological studies of posterior cerebral artery occlusion. *Tohoku Igaku Zasshi*, **91**, 197-217. (Japanese with English abstract)
 - 8) Tagawa, K., Kutsusawa, T. & Nagae, K. (1978) Pure alexia due to cerebrovascular diseases. *Neurol. Med.*, **9**, 355-365. (Japanese with English abstract)
 - 9) Tagawa, K., Uemura, K. & Kutsusawa, T. (1982) Single photon emission tomographic localization in left-sided unilateral spatial agnosia. *Higher Brain Function Res.*, **2**, 291-300. (Japanese with English abstract)
 - 10) Tagawa, K., Nagata, K. & Shishito, F. (1985) Cerebral blood flow and oxygen utilization in pure alexia due to occlusion of the left posterior cerebral artery. *Jpn. J. Neuropsychol.*, **1**, 97-104. (Japanese with English abstract)
 - 11) Tagawa, K., Nagata, K., Shishito, F. & Uemura, K. (1986) Positron emission tomographic localization of left-sided unilateral spatial agnosia. *Clin. Neurol.*, **26**, 300-308. (Japanese with English abstract)
-