

NOTE

AUDITORY SOUND AGNOSIA WITHOUT APHASIA FOLLOWING A RIGHT TEMPORAL LOBE LESION

Toshikatsu Fujii¹, Reiko Fukatsu¹, Shin-ichi Watabe², Ayumu Ohnuma², Kazumine Teramura¹, Itaru Kimura², Shun-ichi Saso², Kyuya Kogure¹

(¹ Department of Neurology, Institute of Brain Disease, Tohoku University School of Medicine, Sendai, and ²Department of Neurology, Miyagi National Hospital, Yamamoto, Japan)

Auditory sound agnosia has been defined as "the defective recognition of non-verbal sounds and noises". Cases of "auditory agnosia" have been described for more than a hundred years, but we could find only three cases (Nielsen and Sult, 1939; Wortis and Pfeffer, 1948; Spreen, Benton and Stockert, 1965) in the previous literature which demonstrated agnosia for non-verbal sounds without any evidence of agnosia for verbal sounds or aphasia. They had right unilateral lesions while when also aphasia or verbal sound agnosia were present, damage was bilateral or to the left hemisphere. We report here a patient showing auditory sound agnosia without aphasia or word deafness who had a small lesion in the posterior part of the right temporal lobe.

CASE REPORT

A 55-year-old male right-handed truck driver was admitted to the Neurology Service of Miyagi National Hospital on September 1, 1984. While driving a truck the previous day, he suddenly had difficulty driving straight and stopped the vehicle by the road. One hour later, he was found unconscious in the truck, and was sent to a nearby hospital. One hour after admission, he recovered consciousness. The admitting physician thought the patient had suffered a stroke and on the next day sent him to the Neurology Service of Miyagi National Hospital.

In the past, the patient had suffered hypertension but was not treated. His mother died of cerebral apoplexy. He was right-handed and had never suffered from central nervous system diseases in childhood. There were no left-handed relatives in his family.

Upon admission, his blood pressure was 164/96. He was oriented to time, place, and person. Digit span was four forward. Pupils, visual acuity, and visual field to confrontation were all normal. Ocular movements were full, with normal pursuit and saccadic versions. Slight arteriosclerotic changes in retinal vessels were present. The other cranial nerves were intact.

Motor and cerebellar function were normal. The right- and left- sided tendon reflexes were equal, and no Babinski response was elicited. He complained of paresthesia on the left side. Sensory examination was normal for pinprick and temperature, but slightly disturbed for vibration and joint sense on the left side. Graphaesthesia and stereognosis were normal.

Brain CT scan revealed a high-density area in the posterior quarter of the right temporal lobe that involved the lower half of the superior temporal gyrus and the upper half of the middle temporal gyrus (Figure 1).

No abnormality was found on angiography, and a diagnosis of right temporal hemorrhage was made.

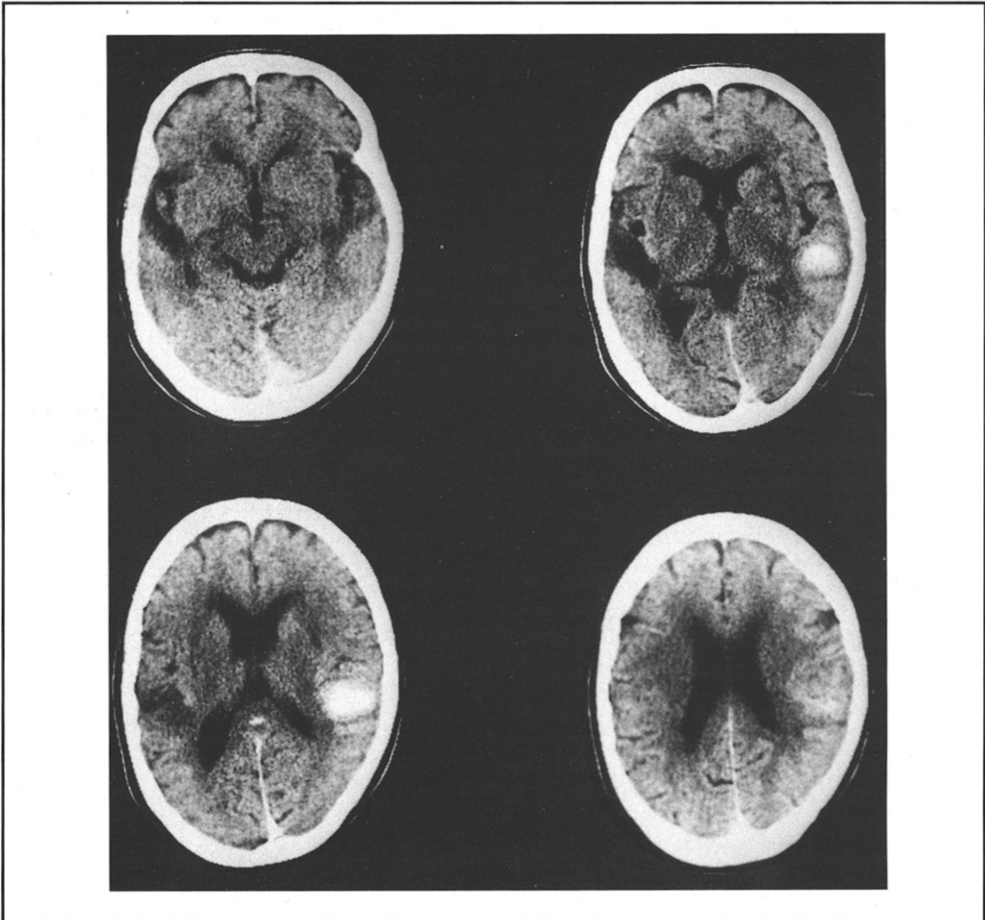


Fig. 1 – Brain CT scan one day after the onset of disease shows a high-density area in the posterior quarter of the right temporal lobe.

Higher Cortical Functions

The patient was a pure right-handed by Oller-Daurella and Maso-Subirana's handedness inventory (Oller and Maso, 1965). Spontaneous speech was fluent with normal prosody, and articulation was normal without any paraphasia. He could immediately name line-drawn pictures and objects with only three errors out of 78 responses (for "crocodile" he said lizard; for "knife", shoehorn; for "cake", no response). Repetition of syllables, word and sentences was perfectly performed. Comprehension of spoken language was normal on the Standard Language Test of Aphasia (Takeda, 1977), that is, his understanding of single words and sentences was perfect. He also showed no disturbances in his ability to read or write Kanji-Kana mixed sentences. Tactile naming was correct in both hands in ten presentations. Cortical function examination showed essentially normal results for right-left orientation, spatial orientation, finger recognition, topographic orientation, and calculation. Ideational apraxia and ideomotor apraxia were absent in both hands. His copy of a cross was recognizable but that of a cube was incomplete, which hinted at a mild constructional disability. His drawing of a clock without model was good.

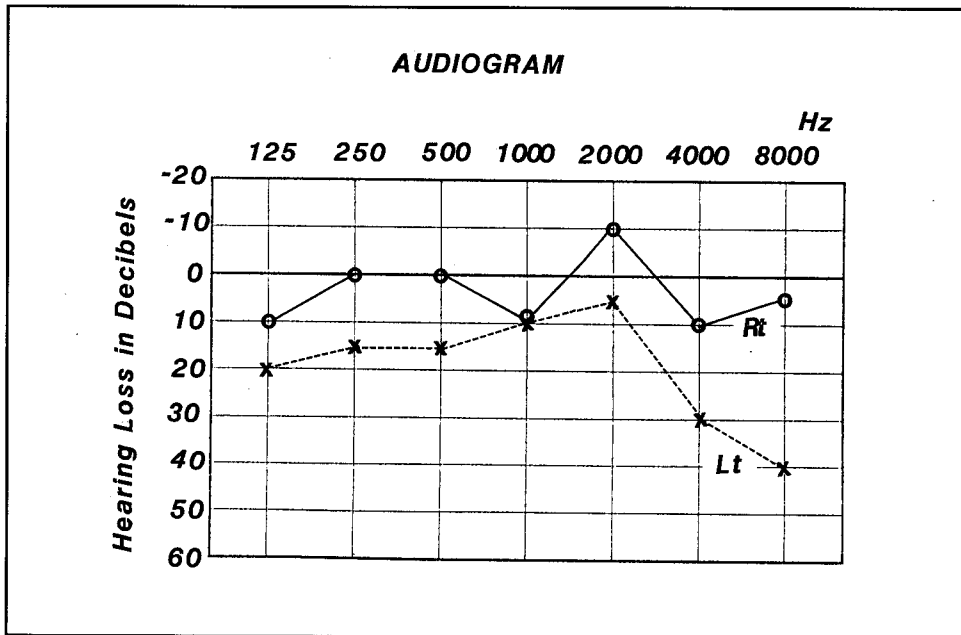


Fig. 2 - The audiogram performed seven days after the onset of disease.

He was unable to do more than the fourth design with Koh's blocks. His WAIS IQ was 73 with a VIQ of 83 and a PIQ of 66.

Audiological Examination

On day seven testing with pure-tone audiometry demonstrated that his hearing was within normal limits in spite of a 30 dB high-frequency loss in the left ear (Figure 2). He was given a dichotic listening test (only bisyllabic stimuli were used), presenting to both ears 20 pairs of digits and 10 pairs of words. The patient was required to report orally the numbers and words that he heard. The patient reported correctly 19 out of 20 digits and 7 out of 10 words in the right ear, but only 7 out of 20 digits and 1 out of 10 words in the left ear.

Auditory brain stem evoked responses were normal (Figure 3), and left-right sound localization tests (1 kHz, 40 dB, Wable tone, 8 trials) were correct.

He could sing the Japanese national anthem "Kimigayo" exactly. The sub-tests of the Seashore Measure of Musical Talents showed that pitch discrimination was 80% correct, while loudness, rhythm, time, timbre, and tonal memory were about 50% correct, which corresponds to a chance performance.

Recognition of Non-verbal Sounds

Two tapes, one presenting 10 and the other 40 familiar, meaningful non-verbal sounds (e.g. baby crying, applause, cat meowing) were given in three separate sessions, requiring the patient to name the sounds. The 10 sound tape was administered on the first and third session and the 40 sound tape (which also included the former 10 sounds) on the second session. Results are shown in Table I. On the first session (day 7), the patient named correctly only 3 out of 10 sounds and his errors mainly consisted of names of acoustically similar sounds (e.g. for the sound of a telephone, "sound of railroad crossing"; for car

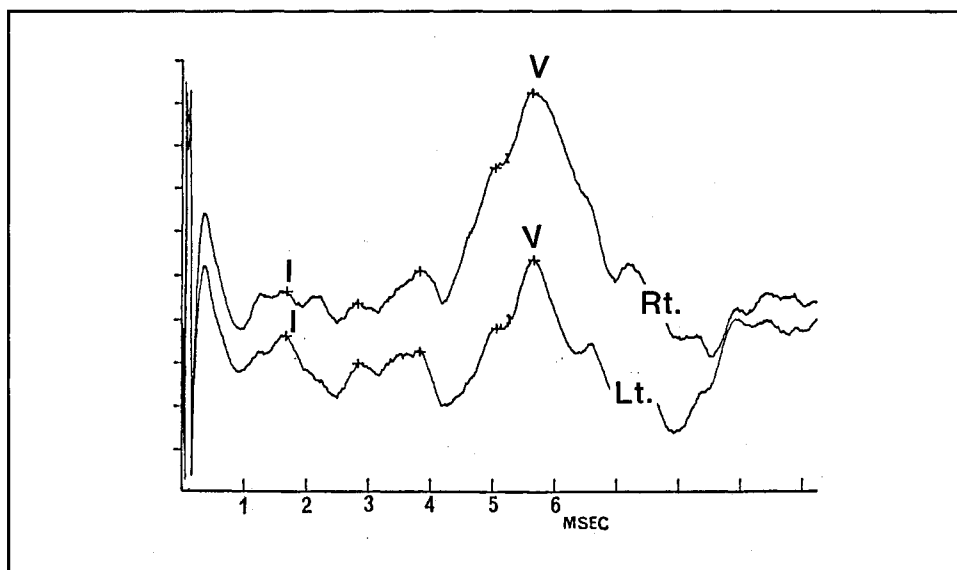


Fig. 3 - Auditory brain stem responses.

Left I: 1.660 - V: 5.660

Right I: 1.680 - V: 5.640 (msec)

TABLE I

Correct Responses to the Sound Recognition Test in Three Different Sessions

	Correct responses/trials
7th day	3/10 (30%)
11th day	28/40 (70%)
16th day	10/10 (100%)

trumpet, "hoot"; for thunder, "fire-works"). On the second session (day 11), his ability to name non-verbal sounds was remarkably improved, and on the third session (day 16), he could name correctly 10 out of 10 sounds. Before these sound recognition tests, the patient was not aware of his sound agnosia.

DISCUSSION

There is some confusion concerning the term "auditory agnosia". Some authors use it in a broad sense, covering misrecognition of all kinds of sounds, non-verbal sounds as well as speech and music, while others refer to the impairment of non-verbal sounds only. We follow the latter use and keep "pure word deafness" separate. Other causes of the patient's errors can be easily discarded. A patient with mild conscious disturbances or amnesic aphasia might have difficulties in naming sounds but his impairment would not be limited to one sense modality. The present patient showed no receptive or expressive defect of language on the Standard Language Test of Aphasia, and he correctly named almost all

objects presented visually and all by touch. Audiometry did not show any major deficit and his disability cannot be attributed to hearing disturbances. Therefore, it can be safely concluded that the patient suffered from "auditory sound agnosia".

There are two types of auditory sound agnosia, an impairment in discriminating the acoustic structure of the stimulus, and a inability in associating a well-perceived acoustic pattern with its meaning (Vignolo, 1982). Spinnler and Vignolo (1966) suggest that acoustic errors reflect a discriminative disorder, and semantic errors an associative disorder. Our patient mistook the sounds presented for acoustically similar sounds, which suggests that his sound recognition disorder was "discriminative" rather than "associative" in nature. The patient's poor performance on the sub-tests of the Seashore Test supports this interpretation. The question of whether he also suffers from amusia cannot be answered, because of his poor musical knowledge and interest, and of the many individual differences that exist in musical ability.

To date, almost all of the reported cases of auditory sound agnosia were associated with language disorders, and only three without language disorders have been reported (Nielsen and Sult, 1939; Wortis and Pfeffer, 1948; Spreen et al., 1965). Albert, Sparks, Stockert et al. (1972) reported a case of auditory sound agnosia who, however, initially had signs of posterior aphasia with predominant features of word deafness, and cannot, therefore, be considered an instance of pure sound agnosia. Most published case reports of auditory agnosia associated with word deafness had bilateral temporal lobe lesions (Albert, et al., 1972; Wohlfahrt, Lindgren and Jernelius, 1952; Lhermitte, Chain, Escourrolle et al., 1971; Oppenheimer and Newcombe, 1978; Sato, Yasui, Isobe et al., 1982; Chan and Hsi, 1984; Rosati, De Bastiani, Paolino et al., 1982). In the cases of pure auditory sound agnosia the location of damage was as follows: Nielsen and Courville's patient had a right thalamoparietal lesion, Wortis and Pfeffer's patient a right temporo-parieto-occipital lesion and Spreen et al.'s patient a right fronto-temporo-parietal lesion. Taken in conjunction with the above cases, the present one strongly indicates that a lesion confined to the right hemisphere can produce "auditory sound agnosia" without language disorders. Group studies have pointed out that semantic-associative disturbances in sound recognition tasks are mainly found in aphasics with left hemisphere lesion (Vignolo, 1969; Varney, 1980; Varney and Damasio, 1986), while perceptual-discriminative disorders are associated with lesions of the right hemisphere.

The sound recognition disorder of our case was discriminative rather than associative, in keeping with the findings of Spinnler and Vignolo (1966). Since verbal auditory input is analyzed almost exclusively in the left hemisphere (Kimura, 1961; Albert, 1972), and non-verbal auditory input is preferentially analyzed in the right hemisphere (Kimura, 1967), the right hemisphere may play a very important role in perceiving and discriminating non-verbal auditory input.

We tentatively propose that acoustic impulses, verbal as well as non-verbal, reach the temporal lobes of both hemispheres for initial auditory perceptual processing (Albert, 1972). The verbal stimuli which reach the right temporal lobe are transmitted via the corpus callosum to the left hemisphere, and the non-verbal sound stimuli which reach the left temporal lobe are transmitted to the right hemisphere, which deals with non-verbal sound stimuli in the auditory association area. The next step is associating the well-discriminated sound with other characteristics of objects and events stored in the sensory and plurisensory association areas of both hemisphere. In the present case, the neurological mechanism specialized to perceive and discriminate non-verbal sounds located in the right hemisphere (probably in the auditory association area) were destroyed. Discrimination of verbal stimuli was not disturbed because the left temporal lobe was intact.

The patient showed improvement on three successive repetitions of the sound recognition test and the defect disappeared in 16 days. Recovery may be due to the small size of the right temporal hemorrhage or to the latent ability of the left hemisphere to discriminate non-verbal input which allowed it to take over right hemisphere functions, when they were disrupted.

This hypothesis would explain why auditory sound agnosia is rare following right hemisphere damage.

ABSTRACT

A 55-year-old right-handed man showed inability to recognize the meaning of non-verbal sounds without impairment of language comprehension after a cerebrovascular accident. His auditory acuity was intact and no other sign of agnosia, apraxia or aphasia was detectable. His errors on a test of sound recognition were acoustic rather than semantic. Brain CT scan showed a small lesion in the posterior part of the right temporal lobe. This case suggests that auditory sound agnosia without language disorder can ensue a lesion confined to the right hemisphere, and that the deficit is discriminative rather than associative in nature.

REFERENCES

- ALBERT, M. Aspects de la comprehension auditive du langage. *Language*, 7: 37-51, 1972.
- ALBERT, M.L., SPARKS, R., and VON STOCKERT, T. A case of auditory agnosia: linguistic and non-linguistic processing. *Cortex*, 8: 427-433, 1972.
- CHAN, J.L., and HSI, M.S. Auditory agnosia. *Formosan Medical Association*, 83: 718-723, 1984.
- KIMURA, D. Cerebral dominance and the perception of verbal stimuli. *Canadian Journal of Psychology*, 15: 166-171, 1961.
- KIMURA, D. Functionary asymmetry of the brain in dichotic listening. *Cortex*, 3: 163-178, 1967.
- LHERMITTE, F., CHAIN, F., and ESCOURROLLE, R. Étude des troubles perceptifs auditifs dan les lésions temporales bilatérales. *Revue Neurologique*, 5: 329-351, 1971.
- NIELSEN, J.M., and SULT, C.W. JR. Agnosia and the body scheme. *Bulletin of the Los Angeles Neurological Societies*, 4: 69-81, 1939.
- OLLER-DAURELLA, L., and MASO-SUBIRANA, E. Semiologia clinica y EEG de la lateralidad preferencial. VIII Congress Nacional de Neuro-Psiquiatria. Madrid: Libro de Ponencias, 1965, pp. 165.
- OPENHEIMER, D.R., and NEWCOMBE, F. Clinical and anatomic findings in a case of auditory agnosia. *Archives of Neurology*, 35: 712-719, 1978.
- ROSATI, G., BASTIANI, P. and PAOLINO E. Clinical and audiological findings in a case of auditory agnosia. *Journal of neurology*, 227: 21-27, 1982.
- SATO, M., YASUI, N., and ISOBE, I. A case of pure word deafness and auditory agnosia associated with bilateral temporo-parietal lesions. *Brain and Nerve (Tokyo)*, 34: 939-945, 1982. (J.)
- SPINNLER, H., and VIGNOLO, L. Impaired recognition of meaningful sounds in aphasia. *Cortex*, 2: 337-348, 1966.
- SPREEN, P., BENTON, A.L., and FINCHAM, R.W. Auditory agnosia without aphasia. *Archives of neurology*, 13: 84-92, 1965.
- TAKEDA, K. Standard Language Test of Aphasia (SLTA): detailed description of construction of aphasia test in Japanese. *Advanced Neurological Science (Tokyo)*, 21: 1002-1013, 1977. (J.)
- VARNEY, N. Sound recognition in relation to aural language comprehension in aphasic patients. *Journal of Neurology, Neurosurgery and Psychiatry*, 43: 71-75, 1980.
- VARNEY, N., and DAMASIO, H. CT scan correlates of sound recognition defect in aphasia. *Cortex*, 22: 483-486, 1986.
- VIGNOLO, L.A. Auditory agnosia. In A.L. Benton (Ed.), *Contributions to Clinical Neuropsychology*. Chicago: Aldine, 1969, pp. 172-206.
- VIGNOLO, L.A. Auditory agnosia. *Phil. Transactions R. Soc. Lond., B* 298: 49-57, 1982.
- WOHLFAHRT, G., LINDGREN, A., and JERNELINS, B. Clinical picture and morbid anatomy in a case of "pure word deafness". *Journal of Nervous and Mental Disease*, 116: 818-827, 1952.
- WORTIS, S.B., and PFEFFER, A.Z. Unilateral auditory-spatial agnosia. *Journal of Nervous and Mental Disease*, 108: 181-186, 1948.

Toshikatsu Fujii, M.D., Department of Neurology, Institute of Brain Disease, Tohoku University School of Medicine, 1-1 Seiryomachi, Sendai, 980 Japan.