

Stroke in Early Childhood Due to Homocystinuria

Füsun Alehan, MD*, Semra Saygi, MD*, Şansal Gedik, MD[†], and Esra Meltem Kayahan Ulu, MD[‡]

A previously healthy girl, age 3 years 9 months, presented with right-sided hemiparesis and seizures. Ischemic infarction was confirmed through magnetic resonance imaging and magnetic resonance angiography. Extensive evaluation to discover the underlying etiologies and risk factors predisposing this patient to stroke included coagulation defects, cardiac anomalies, congenital inborn metabolism deficiency, and infections and trauma. Based on the clinical and laboratory results, a diagnosis of homocystinuria was made. Homocystinuria is an inherited disorder that affects the metabolism of the amino acid methionine. Although homocystinuria is usually associated with ischemic strokes, the sudden onset of stroke as the initial presentation of homocystinuria is very rare in early childhood. Based on this case, however, metabolic screening for hyperhomocystinemia is recommended in any child presenting with a stroke. © 2010 by Elsevier Inc. All rights reserved.

Alehan F, Saygi S, Gedik Ş, Kayahan Ulu EM. Stroke in early childhood due to homocystinuria. *Pediatr Neurol* 2010;43:294-296.

Introduction

Homocystinuria is a well known disorder of the metabolism of the amino acid methionine due to an enzyme deficiency; it affects multiple organ systems. This recessively inherited condition is by and large a rare disorder of methionine metabolism, with a reported incidence of

approximately 1 in 100,000-200,000 live births [1]. Complications of homocystinuria include thromboembolic stroke, visual loss due to ectopia lentis, osteoporosis, and mental retardation. Nonneurologic manifestations of homocystinuria tend to become more apparent during late childhood; these may include tall stature with a marfanoid habitus and arachnodactyly, osteoporosis with vertebral fractures and kyphoscoliosis, livedo reticularis, and a malar flush. Hypopigmentation and premature graying of the hair are also common. Neuropsychiatric symptomatology has also been reported, including affective disorders, obsessive compulsive symptomatology and personality disorders [2,3].

Described here is a case of acute stroke in early childhood due to homocystinuria. This condition has rarely been reported for cases in which the initial presentation is with stroke. The present case should raise awareness of the possibility of homocystinuria in any patient with acute hemiplegia in early childhood.

Case Report

A girl aged 3 years 9 months presented to a local hospital with acute onset right hemiparesis and subsequent generalized tonic-clonic seizures. She was transferred to the authors' child neurology clinic after detection of an acute infarct in the left cerebral hemisphere on cranial magnetic resonance imaging.

The patient was born at term after an unremarkable pregnancy and to consanguineous parents. Her past medical history was unremarkable, and developmental milestones were within normal limits. Family history was unremarkable.

At admission to the child neurology clinic, her weight, length, and head circumference were found to be concordant with her age. She was noted to have coarse facial appearance, mild malar flushing, livedo reticularis on the extremities, and bilateral carotid bruits. Neurologic examination revealed motor aphasia, right-central facial paralysis, and right hemiparesis. Plantar response was extensor on the right.

To discover the etiology of the stroke, the patient was given an extensive evaluation. Echocardiogram findings were unremarkable. Cranial magnetic resonance imaging revealed acute infarct areas in the left cerebral hemisphere, caudate nucleus, lentiform nucleus, and posterior thalamus (Fig 1). Selective cerebral magnetic resonance angiography revealed occlusions of both internal carotid arteries and the left middle cerebral artery (Fig 2). Hypercoagulable status, collagen vascular disease, vasculitis, and metabolic disease were considered in the differential diagnosis of vasculopathy. The coagulation profile was unremarkable, and the screening for autoimmune diseases yielded negative findings. Metabolic screening revealed elevated concentrations of serum homocysteine (50 $\mu\text{mol/L}$; reference range, 4.5-15 $\mu\text{mol/L}$) and methionine (72 $\mu\text{mol/L}$; reference range, 7-47 $\mu\text{mol/L}$) and a decreased serum concentration of vitamin B₁₂ (103 pg/mL; reference range, 193-982 pg/mL). Urine tested strongly

From the *Division of Child Neurology, [†]Department of Ophthalmology, and [‡]Department of Radiology, Baskent University Faculty of Medicine, Ankara, Turkey.

Communications should be addressed to:
Dr. Saygi; 6. cad, No: 72/3 Bahcelievler/Ankara, Turkey.
E-mail: semra_saygi@yahoo.com
Received January 5, 2010; accepted May 11, 2010.

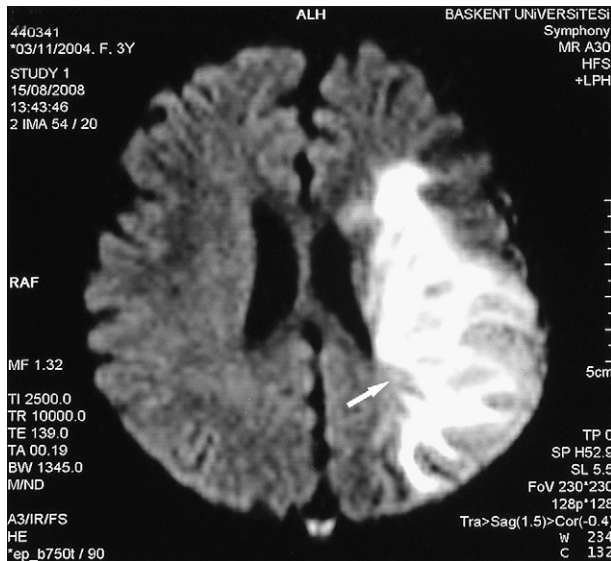


Figure 1. Cranial magnetic resonance imaging: Hyperintense acute infarction was seen in the left cerebral hemisphere on the axial fluid-attenuated inversion recovery image.

positive for sodium nitroprusside. Ophthalmologic examination revealed bilateral lens subluxation.

Based on clinical and laboratory results, a diagnosis of homocystinuria was made. The patient was treated with low methionine diet, folic acid, vitamin B₆ (pyridoxine) and vitamin B₁₂. The patient did not respond to high dose pyridoxine, and during the follow-up betaine was added to the treatment; only a partial response was obtained. The diagnosis was confirmed with enzyme analysis in fibroblast culture, which indicated cystathionine β synthase enzyme deficiency. Family screening for homocystinuria yielded negative findings.

At her last follow-up visit, 15 months after the diagnosis, she remained seizure free and her aphasia was partially resolved, with residual mild hemiparesis on the right.

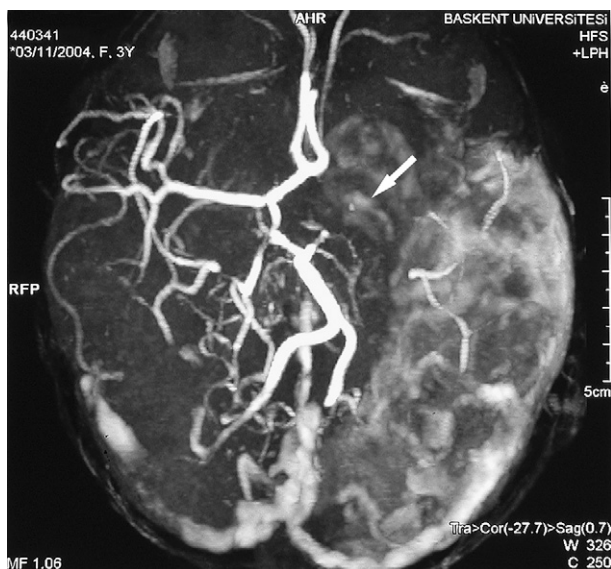

Figure 2. Cranial magnetic resonance angiography: Bilateral internal carotid arteries and left middle cerebral artery occlusion was detected.

Discussion

Stroke and cerebrovascular disorders are significant causes of morbidity and mortality in children. Recent epidemiologic data suggest annual incidence rates of 2-5/100,000 children, with ischemic causes being slightly more frequent than hemorrhagic causes [4]. Ischemic strokes are related primarily to cardiac causes and cerebral vascular disorders; less common causes include hematologic disorders, coagulopathies, metabolic disorders affecting cerebral perfusion, neurocutaneous disorders, and occasionally drug- or toxin-induced vasospasm or vascular inflammation [4].

In the present case, the diagnosis of homocystinuria was based on extensive evaluation, and it was confirmed by enzyme analysis. The homocystinuria was determined to be the cause of cerebral infarction.

Homocystinuria is an autosomal recessive condition caused by a defect in sulfur amino acid metabolism in which the homocysteine, homocysteine-cysteine mixed disulfide, and methionine accumulates in blood and appears in urine and cerebrospinal fluid; it is due to defects either in transsulfuration pathway to cystathionine or in remethylation pathways of methionine. Homocystinuria type I, due to a deficiency of the enzyme cystathionine synthase, is the most common inborn error of methionine metabolism. It is characterized by mental retardation, lens dislocation, skeletal abnormalities, and thrombotic vascular disease. Homocystinuria may also be due to defects in methyl cobalamin formation; homocystinuria type II is characterized by the triad of megaloblastic anemia, homocystinuria, and hypomethioninemia. Deficiency of the enzyme methyltetrahydrofolate reductase results in homocystinuria type III, which is characterized by homocystinuria and homocystinemia with low or normal blood methionine levels [5].

The clinical picture of homocystinuria is extremely heterogeneous, ranging from patients presenting with all of the complications to individuals with no overt clinical signs. Atypical presentations such as pancreatitis, hepatitis, psychosis, megaloblastic anemia, recurrent dystonia, multifocal bursitis, vasospasm, and cutis marmorata universalis have also been reported in case studies [3,5-8].

Early vascular occlusion is the most serious complication for patients with homocystinuria. Approximately 40% of patients with homocystinuria will have a thromboembolic vascular lesion, which is a cause of disability and mortality in patients before the age of 20 years [9].

Acute hemiplegia or focal motor or generalized seizure disorders may be presenting features of homocystinuria as well as of cerebrovascular thromboembolic events. There are rare reports of homocystinuria with initial presentation with stroke, although this type of presentation is extremely rare under the age of 5 years [10,11].

In the present case, the patient presented with arterial thrombosis in the absence of any of the classic phenotypic characteristics of homocystinuria, such as mental retardation, skeletal abnormalities, and marfanoid habitus. To

our knowledge, this is the third reported case of a patient with homocystinuria presenting with cerebral infarction under the age of 5 years.

The mechanisms by which thrombosis and atherosclerosis result from hyperhomocysteinemia are not clear, but probably involve endothelial injury and stimulation of platelet aggregation [12].

Accumulated evidence suggests that the homocysteine metabolite Hcy-thiolactone, a thioester, plays an important role in atherothrombosis. Additionally, blood-clotting abnormalities resulting from impaired synthesis or activities of clotting factors such as antithrombin III, factors VII and X, and β -thromboglobulin may also play a role [12].

No specific cure has been discovered for homocystinuria. Beyond the genotype-phenotype correlation, approximately 50% of patients are pyridoxine responsive and can be treated using high doses of vitamin B₆. For nonresponders, therapy consists of a low methionine diet, folic acid supplement, and trimethylglycine (also known as betaine) to lower plasma disulfide metabolites [13]. An early diagnosis is important, because timely dietary changes and medication can reverse oculo-cutaneous changes, stop progression of the disease, and avoid neurologic impairment [14].

The patient was treated with low methionine diet, folic acid (10 mg/day), vitamin B₁₂, and vitamin B₆ (400 mg/day). At the follow-up examination, betaine (2 g/day) was added to the treatment because of lack of response to the high dose pyridoxine treatment and a partial response to the betaine was obtained.

Patients with homocystinuria should be monitored for complications that may result if there is lack of response with the initial treatment. Family screening for homocystinuria should be conducted.

In conclusion, possible homocystinuria should be investigated in any patient presenting with stroke or vasculopathy, even in the absence of other classic features of the disease.

We thank Brian Fowler, PhD, for his assistance in the enzyme analysis.

References

- [1] **Mudd SH**, Levy HL, Skovby F. Disorders of transsulfuration. In: Scriver CR, Beaudet AL, Sly WS, Vale D, editors. *The metabolic basis of inherited disease*. 6th ed. New York: McGraw-Hill, 1989: 693-734.
- [2] **Rao TN**, Radhakrishna K, Mohana Rao TS, Guruprasad P, Ahmed K. Homocystinuria due to cystathionine β synthase deficiency. *Indian J Dermatol Venereol Leprol* 2008;74:375-8.
- [3] **Ryan MM**, Sidhu RK, Alexander J, Megerian JT. Homocystinuria presenting as psychosis in an adolescent. *J Child Neurol* 2002;17:859-60.
- [4] **Pappachan J**, Kirkham FJ. Cerebrovascular disease and stroke. *Arch Dis Child* 2008;93:890-8.
- [5] **Gomber S**, Dewan P, Dua T. Homocystinuria: a rare cause of megaloblastic anemia. *Indian Pediatr* 2004;41:941-3.
- [6] **Ekinci B**, Apaydin H, Vural M, Ozekmekçi S. Two siblings with homocystinuria presenting with dystonia and parkinsonism. *Mov Disord* 2004;19:962-4.
- [7] **Mack CL**, Emerick KM, Kovarik P, Charrow J. Early speech delay and hepatitis as presenting signs of homocystinuria. *J Pediatr Gastroenterol Nutr* 2001;33:221-3.
- [8] **Hong HS**, Lee HK, Kwon KH. Homocystinuria presenting with portal vein thrombosis and pancreatic pseudocyst: a case report. *Pediatr Radiol* 1997;27:802-4.
- [9] **Mudd SH**, Skovby F, Levy HL, et al. The natural history of homocystinuria due to cystathionine- β -synthetase deficiency. *Am J Hum Genet* 1985;37:1-31.
- [10] **Cardo E**, Campistol J, Carit J, et al. Fatal haemorrhagic infarct in an infant with homocystinuria. *Dev Med Child Neurol* 1999;41:132-5.
- [11] **Cruysberg JR**, Boers GH, Trijbels JM, Deutman AF. Delay in diagnosis of homocystinuria: retrospective study of consecutive patients. *BMJ* 1996;313:1037-40.
- [12] **Lu CY**, Hou JW, Wang PJ, Chiu HH, Wang TR. Homocystinuria presenting as fatal common carotid artery occlusion. *Pediatr Neurol* 1996;15:159-62.
- [13] **Chao CL**, Tsai HH, Lee CM, et al. The graded effect of hyperhomocysteinemia on the severity and extent of coronary atherosclerosis. *Atherosclerosis* 1999;147:379-86.
- [14] **Yap S**, Boers GH, Wilcken B, et al. Vascular outcome in patients with homocystinuria due to cystathionine β -synthase deficiency treated chronically: a multicenter observational study. *Arterioscler Thromb Vasc Biol* 2001;21:2080-5.