

Paradoxical Brain Embolism Induced by *Mycoplasma pneumoniae* Infection with Deep Venous Thrombus

Joe Senda¹, Mizuki Ito¹, Naoki Atsuta¹, Hirohisa Watanabe¹, Naoki Hattori¹,
Hiromichi Kawai² and Gen Sobue¹

Abstract

A 21-year-old man had sudden-onset right hemiplegia and aphasia with respiratory infection. A chest X-ray disclosed consolidation in both lungs and magnetic resonance imaging showed an embolism in the left middle cerebral artery. A pelvic computed tomography scan revealed deep venous thrombus in both femoral veins. Patent foramen ovale was detected by transesophageal echocardiogram. Antibodies to *M. pneumoniae* were highly elevated, and hypercoagulability was subsequently detected. This case suggests that the possible pathogenic mechanism for *M. pneumoniae* infection-related stroke might be paradoxical brain embolism with deep venous thrombus as a consequence of the hypercoagulability related to this infection.

Key words: paradoxical brain embolism, *Mycoplasma pneumoniae*, hypercoagulability, deep venous thrombus

(Inter Med 49: 2003-2005, 2010)

(DOI: 10.2169/internalmedicine.49.3570)

Introduction

Although *Mycoplasma pneumoniae* infection is considered one of the potential risk factors of stroke (1), the underlying process leading to the stroke remains unclear. We present the first report of a case of paradoxical brain embolism with deep venous thrombus clearly determined to be caused by temporary hypercoagulability related to *M. pneumoniae* infection.

Case Report

An otherwise healthy 21-year-old male university student experienced sudden-onset, right side hemiparesis and aphasia during a bowel movement. He reported having an upper respiratory tract infection with high fever and dry-cough as well as bilateral leg swelling and pain for one week before this attack. He was referred to the emergency room three hours after onset.

On admission, he had fever (38.5°C), tachypnea (35 breaths/min), expiratory wheezes, and rhonchi and rales

from both lungs. Expressive aphasia, lowered consciousness and severe hemiplegia on the right side were present. A chest X-ray revealed interstitial infiltration in both lungs. Four hours from onset, a diffusion-weighted magnetic resonance image showed large hyper-intense lesions in the left middle cerebral artery area (Fig. 1A). Magnetic resonance angiography disclosed complete occlusion of the left middle cerebral artery (Fig. 1B). A pelvic contrast-enhanced computed tomography scan revealed deep venous thrombus of both femoral veins (Fig. 1C). Transesophageal echocardiography examination using the contrast microbubble method (2) identified a patent foramen ovale as a right atrium to left atrium shunt only during the Valsalva maneuver (Fig. 1D). A Holter electrocardiogram and transthoracic echocardiography were negative, ruling out other potential causes of stroke, such as arrhythmia and valvular disease. The laboratory findings included elevated white blood cell count (9,900/ μ L) and elevated C-reactive protein (9.9 mg/dL). Platelet count was normal (24.4×10^4 / μ L). Blood coagulation studies showed the following abnormal values: prolonged prothrombin time (17.4 sec, normal 9.5-13.5), prolonged partial thromboplastin time (61.4 sec, normal 25-40),

¹Department of Neurology, Nagoya University Graduate School of Medicine, Aichi and ²Division of Neurology, Department of Internal Medicine, Shiga University of Medical Science, Shiga

Received for publication April 20, 2010; Accepted for publication June 30, 2010

Correspondence to Dr. Gen Sobue, sobueg@med.nagoya-u.ac.jp

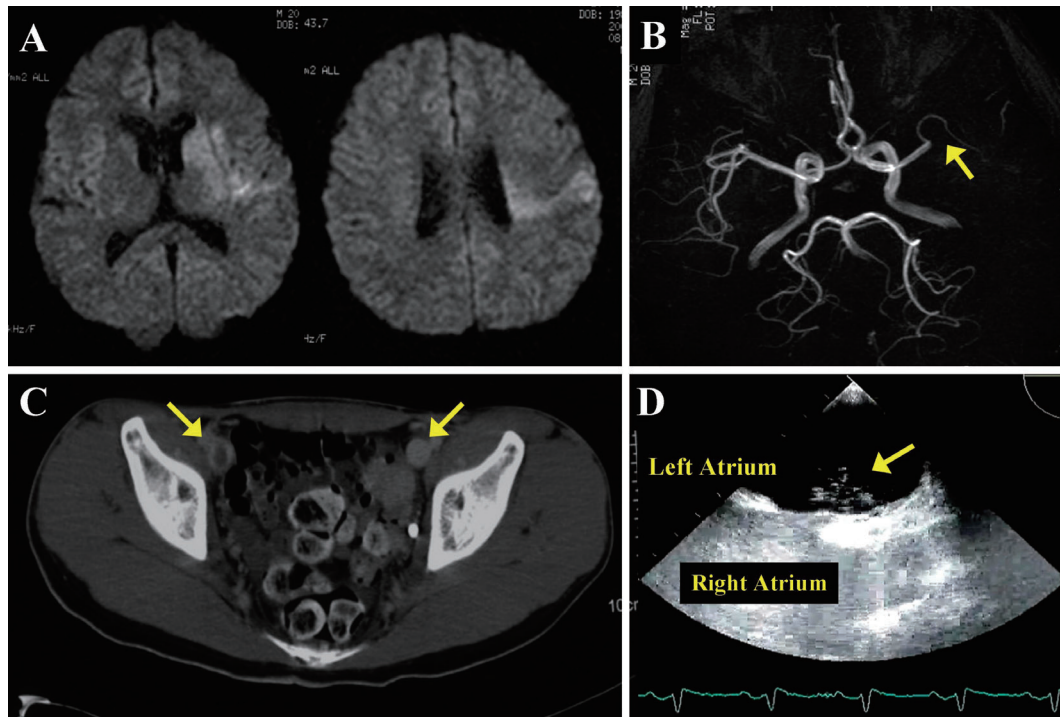


Figure 1. (A) Diffusion-weighted magnetic resonance image shows diffuse hyper-intense large lesions in left middle cerebral artery area. (B) Magnetic resonance angiogram discloses complete occlusion of the left middle cerebral artery (arrow). (C) Pelvic contrast-enhanced computed tomography scan reveals deep venous thrombosis in the femoral veins on both sides (arrows). (D) Contrast transesophageal echocardiogram during the Valsalva maneuver exhibiting the microbubble flow from the right atrium to left atrium due to a patent foramen ovale (arrow).

increased fibrin/fibrinogen degradation products (547 mg/dL, normal <100), increased thrombin-antithrombin III-complex (9.7 ng/mL, normal <3), increased D-dimer (30.6/ μ L, normal <1), increased antiphospholipid antibodies (16.5 U/mL, normal <10), increased IgM-anticardiolipin antibodies (220 MPL, normal <30), and slightly decreased protein C activity (66%, normal >70%). IgG-anticardiolipin, antiphospholipin, anticytoplasmic, antinuclear and anti-double/single stranded (ds/ss) DNA antibodies were not elevated. Cold agglutinins were positive ($\times 1,024$). The agglutination assay revealed strongly elevated *M. pneumoniae* antibodies ($\times 2,560$). Lumbar puncture showed a normal CSF leukocyte count (1×10^6 cells/L), total protein content (0.36 g/L), and glucose (0.51 g/L).

We diagnosed this case as paradoxical brain embolism with deep venous thrombus caused by hypercoagulability associated with *M. pneumoniae* infection. The patient was treated with minocycline and clarithromycin, and the anticoagulants heparin sodium and warfarin. The *Mycoplasma pneumoniae* disappeared completely within a week. At three weeks, however, the thrombus in both femoral veins remained despite strong anticoagulant treatments; thus, a permanent filter was implanted in the inferior vena cava to prevent recurrent thromboembolism and he continued to take warfarin.

Six months after onset, the right hemiparesis and fluency had improved. The complete blood cell count and all bio-

chemistry studies showed normal values including anti-phospholipid antibodies and IgM-anti-cardiolipin antibodies. A follow-up magnetic resonance angiography showed that the occluded middle cerebral artery was not re-canalized. Two years following the attack the patient could walk and returned to the university.

Discussion

Stroke related to *M. pneumoniae* infection has been reported in several cases (3-9), mainly in children (3-5, 8). These reports proposed that the association is due to direct damage of the central nervous system (3, 6), or other mechanisms such as vasculitis resulting from post-infectious immunological disorders (4). These cases all reported normal coagulation values, although it is uncertain whether the timing of the coagulation tests was appropriate for detecting abnormal values. In adults, cervical artery vessel dissection and recent bacterial infections, including *M. pneumoniae*, were significantly correlated, but the definite cause was only speculative, and incomplete at that (7). To date, only two cases of ischemic stroke were reported with hypercoagulability after *M. pneumoniae* infection: a 13-year-old boy with a methylenetetrahydrofolate reductase gene mutant type had ischemic stroke with hypercoagulability after *M. pneumoniae* infection (8), and a 30-year-old man with left middle cerebral artery occlusion detected in cerebral angiography

and associated with *M. pneumoniae* infection, showed hypercoagulability that suggested intravascular coagulation as a probable etiology (9). None of the above cases reported the presence of patent foramen ovale.

The present patient displayed severe hypercoagulability and increased IgM-anticardiolipin and antiphospholipid antibodies as well as femoral vein thrombosis on admission. Hypercoagulability associated with *M. pneumoniae* infection is not a rare phenomenon. It is suggested that the mechanism leading to hypercoagulability is related to the surface proteins, chemical mediators, and multiorgan proteins produced by *M. pneumoniae*, and that these molecules influence the role that hypercoagulability plays in molecular mimicry, postinfectious autoimmunity, and immune-mediated damage (10, 11). Similarly, the presence of transient antiphospholipid and anticardiolipin antibodies is well documented in the settings of many infections including *M. pneumoniae* (12-14). Recently, the coincidence of positive antiphospholipid and anticardiolipin antibodies, and hypercoagulability after *M. pneumoniae* infection was reported (14, 15). Antiphospholipid antibodies are a heterogeneous group of IgM and IgG antibodies directed against plasma proteins bound to phospholipid surfaces. The antiphospholipid antibody syndrome is used to describe patients who experience recurrent thrombosis in the setting of a persistent lupus anticoagulant or anticardiolipin antibodies. The precise mechanism by which these antibodies contribute to thrombosis is not fully understood (16, 17). In the present case, coagulation and increased antiphospholipid, IgM/IgG-anticardiolipin antibodies returned to normal six months following the stroke attack; thus, we hypothesize that the antiphospholipid and IgM-anticardiolipin antibodies induced by the *M. pneumoniae* infection resulted in a temporary hypercoagulable state which contributed to the production of deep venous thrombus.

Furthermore, patent foramen ovale was detected by transesophageal echocardiogram (18) in our case. As the stroke-attack occurred during a bowel movement, we suggest that the evacuation induced a situation similar to the Valsalva maneuver, which increases a right to left cardiac shunt (19). Taking these data together, we conclude that this stroke was induced by a paradoxical brain embolism via a patent foramen ovale from deep venous thrombus caused by *M. pneumoniae* infection. Development of thrombotic complications probably arose from antiphospholipid/anticardiolipin antibody formation associated with *M. pneumoniae* infection. The present case strongly suggests that other embolic stroke attacks seen particularly in young patients with *M. pneumoniae* infections may have similar mechanisms of paradoxical brain embolism and systemic hypercoagulability.

References

1. Guleria R, Nisar N, Chawla TC, Biswas NR. *Mycoplasma pneumoniae* and central nervous system complications: a review. *J Lab Clin Med* **146**: 55-63, 2005.
2. Homma S, Di Tullio MR, Sacco RL, Mihalatos D, Li Mandri G, Mohr JP. Characteristics of patent foramen ovale associated with cryptogenic stroke: a biplane transesophageal echocardiographic study. *Stroke* **25**: 582-586, 1994.
3. Lee CY, Huang YY, Huang FL, Liu FC, Chen PY. *Mycoplasma pneumoniae*-associated cerebral infarction in a child. *J Trop Pediatr* **55**: 272-275, 2009.
4. Leonardi S, Pavone P, Rotolo N, La Rosa M. Stroke in two children with *Mycoplasma pneumoniae* infection. A causal or casual relationship? *Pediatr Infect Dis J* **24**: 843-845, 2005.
5. Sotgiu S, Pugliatti M, Rosati G, Deiana GA, Sechi GP. Neurological disorders associated with *Mycoplasma pneumoniae* infection. *Eur J Neurol* **10**: 165-168, 2003.
6. Padovan CS, Pfister HW, Bense S, Fingerle V, Abele-Horn M. Detection of *Mycoplasma pneumoniae* DNA in cerebrospinal fluid of a patient with *M. pneumoniae* infection—"associated" stroke. *Clin Infect Dis* **33**: 119-121, 2001.
7. Grau AJ, Brandt T, Bugge F, et al. Association of cervical artery dissection with recent infection. *Arch Neurol* **56**: 851-856, 1999.
8. Ryu JS, Kim HJ, Sung IY, Ko TS. Posterior cerebral artery occlusion after *Mycoplasma pneumoniae* infection associated with genetic defect of MTHFR C677T. *J Child Neurol* **24**: 891-894, 2009.
9. Mulder LJ, Spierings EL. Stroke in a young adult with *Mycoplasma pneumoniae* infection complicated by intravascular coagulation. *Neurology* **37**: 1430-1431, 1987.
10. Baseman JB, Reddy SP, Dallo SF. Interplay between mycoplasma surface proteins, airway cells, and the protean manifestations of *Mycoplasma*-mediated human infections. *Am J Respir Crit Care Med* **154**: s137-s144, 1996.
11. Tanaka H, Narita M, Teramoto S, et al. Role of interleukin-18 and T-helper type 1 cytokines in the development of *Mycoplasma pneumoniae pneumonia* in adults. *Chest* **121**: 1493-1497, 2002.
12. Snowden N, Wilson PB, Longson M, Pumphrey RS. Antiphospholipid antibodies and *Mycoplasma pneumoniae* infection. *Postgrad Med J* **66**: 356-362, 1990.
13. Asherson RA, Cervera R. Antiphospholipid antibodies and infections. *Ann Rheum Dis* **62**: 388-393, 2003.
14. Espinosa G, Santos E, Cervera R, et al. Adrenal involvement in the antiphospholipid syndrome: clinical and immunologic characteristics of 86 patients. *Medicine (Baltimore)* **82**: 106-118, 2003.
15. Witmer CM, Steenhoff AP, Shah SS, Raffini LJ. *Mycoplasma pneumoniae*, splenic infarct, and transient antiphospholipid antibodies: a new association? *Pediatrics* **119**: e292-e295, 2007.
16. de Groot PG, Lutters B, Derksen RH, et al. Lupus anticoagulants and the risk of a first episode of deep venous thrombosis. *J Thromb Haemost* **3**: 1993-1997, 2005.
17. Galli M, Luciani D, Bertolini G, Barbui T. Lupus anticoagulants are stronger risk factors for thrombosis than anticardiolipin antibodies in the antiphospholipid syndrome: a systematic review of the literature. *Blood* **101**: 1827-1832, 2003.
18. Serafini O, Misuraca G, Greco F, et al. Prevalence of structural abnormalities of the atrial septum and their association with recent ischemic stroke or transient ischemic attack: echocardiographic evaluation in 18631 patients. *Ital Heart J Suppl* **4**: 39-45, 2003.
19. Clarke NR, Timperley J, Kelion AD, Banning AP. Transthoracic echocardiography using second harmonic imaging with Valsalva manoeuvre for the detection of right to left shunts. *Eur J Echocardiogr* **5**: 176-181, 2004.