

Clinicopathological Conference: A 71-year-old Female With Neurological Deficits, Chest Pain, and Electrocardiographic Changes

Aneesh T. Narang, MD, and Andrus Alian, DO

Abstract

The authors present a case of a 71-year-old female who presented to the emergency department with slurred speech, left sided facial droop, and right arm and leg weakness. During her ED stay, she developed left sided chest pain and right arm numbness in the setting of EKG changes. The patient's clinical course is outlined and a discussion of the potential etiologies as well as the clinical management is provided.

ACADEMIC EMERGENCY MEDICINE 2010; 17:e102–e109 © 2010 by the Society for Academic Emergency Medicine

Keywords: Takotsubo cardiomyopathy, stroke, vertebral artery dissection, myxoma, endocarditis, acute coronary syndrome

CASE REPORT

A 71-year-old female presented to our emergency department (ED) with slurred speech, right hemiplegia, and left facial droop. The patient's symptoms were present upon awakening after 8 hours of sleep. After being in the ED for 30 minutes, she developed left-sided chest pressure and pain in her mid-upper back. The patient had never experienced similar symptoms and had no symptoms on the previous night. The patient's medical history was significant for hypertension and gastroesophageal reflux. She did not take any medications because she felt "fine." She did not smoke, drink alcohol, or use illicit drugs and denied any allergies to medications.

On examination, she was awake, alert, and oriented. The patient appeared anxious, but was in no acute distress. Initial vital signs were a pulse of 102 beats/min, blood pressure of 195/95 mm Hg, respiratory rate of 18 breaths/min, oxygen saturation of 100% on room air, and a temperature of 36.8°C. The head and neck exam were unremarkable. The chest was clear to aus-

cultation. Cardiac examination revealed normal heart sounds without murmurs, rubs, or gallops. The abdomen was soft and nontender, and normoactive bowel sounds were present. The patient's neurological exam was remarkable for the following: dysarthria, left facial droop, 2/6 muscle strength in the right arm, and 3/6 muscle strength in the right leg. Muscle strength on the patient's left side was 5/5 in both the upper and the lower extremities. The patient's perception of pain and touch were normal. The skin examination was unremarkable, and the patient's peripheral pulses were bounding and equal. After 30 minutes in the ED, the patient's neurological symptoms resolved.

The patient's electrocardiogram (ECG; Figure 1) was remarkable for ST-segment elevation in the anterolateral leads with no reciprocal changes in the inferior leads. The rate was 96 beats/min and the axis was normal. The chest radiograph was normal, without mediastinal widening (Figure 2). Initial laboratory studies revealed a normal complete blood count and metabolic profile including renal function. The creatinine kinase (CK) was 72 U/L and the troponin T was below the detectable level (<0.06 ng/mL). A noncontrast computed tomography (CT) scan of the brain revealed age-appropriate atrophy, without evidence of intracranial pathology. The patient was given 325 mg of aspirin and 25 mg of oral metoprolol. Soon after, the patient underwent a diagnostic study that would help reveal the final diagnosis.

From the Department of Emergency Medicine, Boston Medical Center (ATN), Boston, MA; and the Department of Emergency Medicine, Long Island Jewish Medical Center (AA), New Hyde Park, NY.

Received February 8, 2010; revision received February 11, 2010; accepted February 12, 2010.

Presented at the Society for Academic Emergency Medicine annual meeting, New Orleans, LA, May 2009.

Supervising Editor: Mark B. Mycyk, MD.

Address for correspondence and reprints: Aneesh T. Narang, MD; e-mail: annarang@bmc.org.

FACULTY DISCUSSION

This is a challenging case in which there are a few key highlights that stand out in my mind. First, this is an

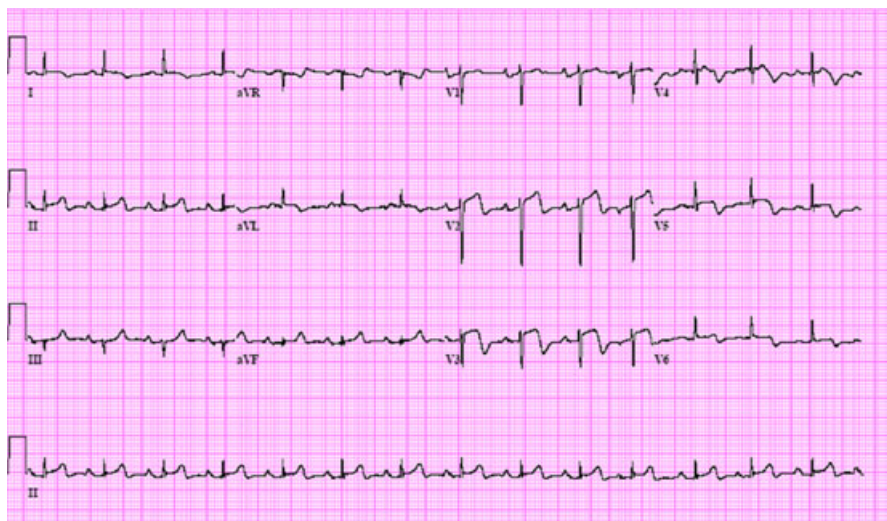


Figure 1. ECG obtained during patient's ED stay. ECG = electrocardiogram.

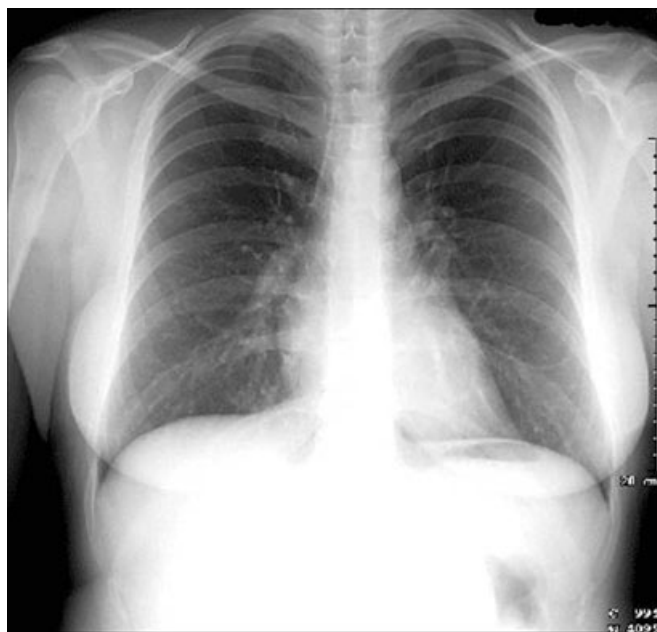

Figure 2. Chest radiograph of our patient.

elderly female presenting with focal neurological deficits that had been present upon awakening. Second, while in the ED, she has ischemic ECG changes in the setting of acute chest pain radiating to her upper back. Third, her examination is notable for dysarthria, left facial droop, and right-sided hemiparesis. She is also noted to have no pulse deficits and equal bilateral blood pressures. Finally, the rest of her diagnostic work-up, which included a noncontrast brain CT scan, chest radiograph, and laboratory work, are all essentially normal.

At first glance, it appears that this patient has two completely different clinical problems: a cerebrovascular accident and an acute coronary event. In cases in which there appears to be multiple different pathophysiological processes occurring, I employ the principle of

Occam's razor and use one entity that could account for her clinical presentation.¹ The real challenge of this case is explaining all of these patient's symptoms with a unifying diagnosis. However, it is important to examine each separately and consider potential causes and then decide if there is a unifying clinical process occurring.

First, we will address her neurological symptoms and try to best localize the vascular territory involved by the stroke. It is important to quickly review the different type of stroke syndromes and their clinical manifestations. An anterior circulation stroke involves the carotid arteries and causes contralateral hemiparesis, hemisensory loss, and visual field deficits. It could also cause gaze preference toward the site of the lesion, as well as aphasia or left-sided neglect symptoms depending on whether it involved the left or right cerebrum. Posterior circulation strokes that involve the vertebrobasilar system affect the brainstem and cerebellum and can present as hemiparesis or quadriplegia ("locked-in syndrome"), crossed deficits, diplopia, dysconjugate gaze, gaze palsy, nystagmus, dysarthria with dysphagia, vertigo, decreased level of consciousness, limb or gait ataxia, and intractable vomiting. The dysarthria as well as the crossed deficits observed in this patient (left facial droop and right hemiparesis) are strongly suggestive of a brainstem lesion. It is in the pons specifically where facial nucleus and nerves originate from; the corticospinal tract responsible for motor function also lies in close approximation. Based on her left facial droop and right sided hemiparesis, I suspect that this most likely represents a pontine infarct.

It is also important to consider the etiology of the stroke, which is difficult to determine because her symptoms are present upon awakening. We are not sure if it began suddenly or had a gradual onset. In general, we can divide potential etiologies into ischemic versus hemorrhagic causes. It is important to consider all ischemic causes including embolic, thrombotic, hypoperfusion, or venous thrombosis. Common causes of cardioembolic strokes include valvular diseases such as rheumatic heart disease, prosthetic valves, and endo-

carditis; left atrial thrombi such as in atrial fibrillation or flutter; left ventricular thrombi secondary to akinesis from antecedent cardiac ischemia; left ventricular aneurysm or nonischemic cardiomyopathy; and cardiac tumors. Other types of embolic strokes include fat and air emboli, but there is nothing in the history such as recent trauma, surgery, or recent central intravenous line placement to suggest that either of these is likely. Paradoxical emboli can also present if the patient has an atrial septal defect or patent foramen ovale. Conditions that can lead to hypoperfusion of the brain would include a dissection involving the carotid or vertebral arteries or any reduced cardiac output states. The patient's head CT scan was read as normal, essentially ruling out a hemorrhagic stroke to account for her clinical picture.

Now, we must address the second interesting part of her presentation, which includes ischemic ECG changes in setting of chest and back pain associated with right arm numbness that begins while in the ED. Her ECG is notable for ST-elevations in I, avL, and V2–V6. Based on the ECG itself, the first thought that comes to mind is whether this is acute coronary syndrome (ACS). Since V1 is not involved, she may have a left anterior descending artery lesion that does not involve the first septal branch. Since I and avL are affected, this implies that the left circumflex or high diagonal branch is also involved.

There are other conditions as well that may present with this ECG picture, including Wellens' syndrome. Wellens' syndrome is a pattern of ECG T-wave changes secondary to a critical proximal left anterior descending artery stenotic lesion. It is important for the emergency physician to recognize this, as typically, 75% of patients will develop an anterior wall myocardial infarction (MI) within days.² It is characterized by a history of chest pain, normal or mildly elevated cardiac enzymes, no precordial Q-waves, no pathological ST-elevation, and no loss of R-waves in precordium. Classically, the ECG findings of Wellens' occur during the pain free period. There are two types of ECG patterns in Wellens' syndrome involving T-wave changes in V2 and V3. In 75% of cases, the precordial T-waves are deeply inverted with symmetric contour. The less common variant, comprising 25% of cases, presents with biphasic T-waves, as demonstrated in our case.² If Wellens' syndrome is suspected, exercise stress testing should not be performed, as it can be fatal to the patient. Instead, the patient should undergo coronary angiography with the hope of avoiding an extensive anterior wall MI.

Another possibility is ventricular aneurysm, which is often seen as a complication of transmural MI and where ST-elevations from V1–V6, along with I and avL, are common. The T amplitude-to-QRS amplitude ratio in all leads, and especially from V1–V4, best distinguishes acute myocardial infarction (AMI) from a left ventricular aneurysm in ECGs that meet ST-segment elevation criteria for reperfusion therapy. A T/QRS ratio of < 0.36 , as well as significant Q-waves, is characteristic of LV aneurysm, whereas a high ratio is associated with an AMI.³ Ventricular aneurysm can occur as early as 48 hours after an acute MI, although there often can be stunning and transient aneurysmal formation earlier.⁴

Nonischemic conditions such as Takotsubo cardiomyopathy can also present with nonspecific ST-segment or T-wave abnormalities, including ST-elevation and/or QT prolongation with large negative T-waves. It is also important to remember that a primary intracranial process can also produce secondary ECG changes. Intracranial hemorrhage is often associated with deep T-wave inversions and bradycardia. Thromboembolic cerebrovascular accidents (CVAs) often are associated with ST- and T-segment abnormalities, as well as prolonged QT interval.⁵ While rare, aortic dissections can also involve the coronary arteries and mimic ST-elevation myocardial infarctions (STEMI). Based on the sudden onset of her symptoms, as well as the radiation to her back, could she be experiencing an aortic dissection that is involving her left main coronary artery, therefore accounting for the ECG findings?

After considering the potential causes for both her neurologic symptoms and the acute onset of her pain with the ECG changes, the most likely etiologies that could explain the entire clinical picture included aortic dissection, a cardioembolic event secondary to endocarditis (bacterial or nonthrombotic), cardiac tumors, Takotsubo cardiomyopathy, ventricular aneurysm predisposing to left ventricle mural thrombus and subsequent stroke, a primary central nervous system (CNS) event with secondary ECG changes, or a concomitant CVA and ACS.

The first diagnosis that immediately came to mind in this case due to the potential sudden onset as well as the multiorgan involvement was an aortic dissection. Whenever a patient has chest pain as well as neurological deficits, any emergency physician would put dissection high on the differential. Obviously, this is a condition you must diagnose in a timely fashion due to the high mortality rate. Based on the suspicion that this is brainstem ischemia, the vertebrobasilar circulation would have to be compromised in some way. The ECG findings suggest that the left main coronary artery is involved. Perhaps this patient is experiencing a vertebrobasilar dissection causing a pontine infarct that propagates in retrograde fashion to the left main coronary artery. This would certainly explain her crossed neurological deficits as well as the chest and back pain and concerning ECG findings. Normally the vertebral artery arises from the superoposterior aspect of the first part of the subclavian artery. Hence, any compromise to the subclavian artery that becomes the axillary artery will often cause upper extremity pulse asymmetry or blood pressure differentials. However, this is not observed in this patient, making my theory seem less plausible. A potential explanation to account for this is that the left vertebral is arising directly from the aortic arch, which is observed in 6% of the population. As a matter of fact, there have been some studies that have shown this anomalous vertebral artery origin is an independent risk and associated with a higher incidence of dissection.^{6,7} My initial thought was that this patient was experiencing a dissection of an anomalous vertebral artery, which therefore would not compromise perfusion of the upper extremities. This dissection would also involve the left main coronary artery to

explain the patient's symptoms and ischemic ECG findings.

After giving this diagnosis more thought, there were a few pieces of the puzzle that did not quite fit. The chest radiograph was completely normal and there is no evidence of mediastinal widening, abnormal or blunted aortic knob, or a ring sign (displacement of the aorta past a calcified aortic intima). There are also no other secondary signs of an aortic dissection on the radiograph such as a left apical cap, tracheal deviation, depression of the left mainstem bronchus, esophageal deviation, or loss of the paratracheal stripe. However, a normal chest radiograph does not rule out a dissection. As a matter of fact, the International Registry for Aortic Dissection revealed that more than 12% of the chest radiographs of patients with aortic dissection were read as normal.⁸ I am also heavily relying on the fact that this woman has an anomalous vertebral artery to explain the equal bilateral blood pressures and symmetrical pulses. This is not a common occurrence, as mentioned earlier. There is also no mention of a headache or neck pain, which patients will often complain of with a dissection involving the carotids or vertebrobasilar circulation. We also later learn that her neurological symptoms resolve while in the ED, making an aortic dissection less likely as the cause of her symptoms. Furthermore, a dissection of this kind to account for the ECG would extend to the mid-left anterior descending artery but not involve the first septal branch, which seems unlikely. There is also no valvular involvement based on the physical examination, for which this patient would be at high risk. Also, a dissection is much more likely to involve the right coronary artery and carotid, neither of which is the case in my theory.^{9,10} Finally, if this patient is having a dissection involving the left main artery, it is very likely that she would be near death or be much more hemodynamically unstable. Due to all of those following reasons, too many assumptions would have to be correct to make an aortic dissection fit this patient's clinical picture.

The next consideration is that this represented a thromboembolic event, which could account for an acute-onset presentation, normal chest radiograph, equal bilateral blood pressures and pulses, and multiple organ involvement. The four diagnoses that best fit this category are endocarditis, ventricular aneurysm and/or left ventricular mural thrombus, cardiac tumor, and Takotsubo cardiomyopathy. Infective endocarditis is a possibility, since systemic embolization is the hallmark of this disease, but with no known risk factors, fevers, or systemic symptoms, it seems less likely. There are also no suggestive physical exam findings such as petechiae, splinter hemorrhage, Osler nodes, or Janeway lesions. Nonbacterial thrombotic endocarditis can also cause symptoms secondary to multiple embolic events without the signs and symptoms suggestive of an infection. However, this condition is almost exclusively observed in patients with hypercoagulable states, chronic illnesses, malignancies, "wasting symptoms," or weight loss. There is no evidence that our patient has any of these underlying states.

Other considerations for this patient include systemic embolism from a left ventricular aneurysm or mural

thrombus. Both are recognized complications from previous MIs. Most emboli arise from the left ventricle as a result of wall motion abnormalities or aneurysms. The incidence of clinically evident systemic embolism after MI is less than 2%, and the incidence increases in patients with anterior wall MI. A left ventricular aneurysm can present as an acute embolic event as well within 48 hours. The overall incidence of mural thrombus after MI is approximately 20%. Large anterior wall MI may be associated with mural thrombus in as many as 60% of patients.^{11,12} Atrial fibrillation in the setting of ischemia may also contribute to systemic embolization. The most common clinical manifestation of embolic complications is stroke, although patients may have limb ischemia, renal infarction, or intestinal ischemia. Most episodes of systemic emboli occur in the first 10 days after AMI.¹³ Physical findings vary with the site of the embolism. Focal neurologic deficits occur in patients with CNS emboli. The evidence, however, renders this diagnosis unlikely as well. First, the ECG does not support a diagnosis of left ventricular aneurysm since there are no pathological Q-waves. Also, while a mural thrombus from ACS is a possibility, the onset is much more sudden than expected. With no known coronary artery disease, this diagnosis is highly unlikely.

Another possibility and a source of systemic emboli would be a cardiac tumor. Forty to 50% of all such tumors are atrial myxomas, and 75% to 85% of all involve the left atrium.^{14,15} Atrial myxomas are the most common cause of cardiac tumors in adults, and this is what most of this discussion will focus on. They tend to occur more frequently in women and between the third and sixth decades of life.¹⁶ There are various clinical manifestations that can be seen with cardiac tumors, with the most common being secondary to cardiac outflow obstruction. Symptoms are caused by obstruction at the mitral valve orifice, which may result in mitral regurgitation. Dyspnea on exertion progressing to orthopnea, paroxysmal nocturnal dyspnea, and pulmonary edema is also often observed. Symptoms of right-sided heart failure can also occur. Constitutional symptoms may include fever, weight loss, arthralgias, and Raynaud phenomenon and can be observed in 30% to 50% of patients. These symptoms may be related to overproduction of interleukin-6; laboratory findings may include anemia, elevated erythrocyte sedimentation rate and C-reactive protein, leukocytosis, and thrombocytopenia.¹⁴

The incidence of emboli from cardiac tumors is higher if they are polypoid or irregular or have a friable surface.^{17,18} They most commonly involve cerebral or retinal vessels, but limb, visceral, and coronary arteries have also been described. CNS manifestations include transient ischemic attack, cerebrovascular accidents, and seizures, and the middle cerebral artery and its associates branches are the most commonly involved. In a recent analysis of 113 cases of atrial myxoma with neurologic presentation, 83% of patients presented with ischemic stroke, most often in multiple sites (43%).¹⁹ Coronary embolization is very rare, occurring roughly 0.06% of the time, which involves the inferior part of the myocardium 64% of the time, anterior 23%,

and posterior 9%.^{20,21} It has been postulated that increases in heart rate, contractility, or blood pressure may increase risk of embolism.

The diagnosis of an atrial myxoma is difficult to make, but is often suggested by physical examination findings and a combination of other diagnostic modalities. A diastolic rumble or holosystolic murmur may be heard depending on the location of the myxoma. A large left atrial myxoma produces a diastolic sound that is referred to as a "tumor plop." This sound arises from obstruction to ventricular in-flow that occurs as the tumor comes to rest over the mitral annulus. It is the functional equivalent of mitral valve stenosis and may be associated with a low-frequency diastolic murmur. Other auscultation findings may include a loud S1 as well as S3 or S4. An ECG may show nonspecific changes, while a chest radiograph can show evidence of left atrial enlargement, congestive heart failure, or calcifications. Echocardiograms, CT scan, magnetic resonance imaging (MRI), and coronary arteriography have all been helpful to establish this diagnosis.¹⁵

Can a cardiac tumor explain our patient's clinical presentation? Theoretically, there could be multiple embolizations from a left atrial myxoma that involves the left vertebrobasilar system and mid-left anterior descending artery. The patient is severely hypertensive, which may increase her risk of embolism. This could certainly explain her ECG findings and neurologic deficits. There are, however, many factors that do not support this as the ultimate diagnosis. As mentioned previously, the middle cerebral artery and right coronary artery are much more likely to be involved in myxomatous embolic events. There are also no cardiac obstructive or constitutional symptoms. There are no cardiac murmurs heard, and the chest radiograph appears normal, although neither of these findings is particularly sensitive in ruling out this diagnosis. The age of the patient is also older than the typical patient diagnosed with atrial myxoma. While none of these rules out a cardiac tumor as being the ultimate diagnosis, the combination of all of these makes it an unlikely cause of her symptoms.

At this point, after considering many diagnoses that could account for our patient's clinical picture, I started back from the beginning and noticed something important mentioned in the patient's overall appearance. It is clear that this patient awoke with a stroke and she was asymptomatic the night before. The onset of her symptoms is unclear, and therefore this may represent a thrombotic or embolic event. It is noted a couple of times that the patient appeared anxious and scared. This leads me to the last of the thromboembolic diagnosis that was mentioned earlier as a possibility. Perhaps the anxiety and stress of having a stroke triggered a catecholamine surge in this patient that led to left ventricular neurocardiogenic stunning. This is known as Takotsubo cardiomyopathy. This condition is characterized by the following features: myocardial stunning, chest discomfort, coronary spasm, shortness of breath, palpitations from an arrhythmia, heart failure, and cardiogenic shock. Unlike the other diagnoses that were considered earlier, the history and ECG also fit this picture. Seventy to 80% of those affected are

postmenopausal women just like our patient. It is characterized by extreme physical or mental stress, which we can presume is occurring here as well. ST-elevations can be seen early on in this condition as well as QT prolongation, and eventually large negative T-wave inversions develop.²² Our ECG actually shows this transition, as you can see ST-elevations as well as the T-wave inversion starting to develop, giving it a biphasic appearance. The only part of this patient's presentation that is difficult to explain is her back pain. It is possible that there may be a referred component of the chest pain she is experiencing as part of Takotsubo cardiomyopathy, and it is a red herring when diagnosing this case.

Takotsubo cardiomyopathy can be a rare complication of acute ischemic strokes, as well as a potential cause of cardioembolic stroke. There have been many case reports linking these two. It is often unclear if it is the catecholamine surge from the physical and emotional stress of a stroke that leads to neurocardiogenic stunning. It is also possible that Takotsubo cardiomyopathy develops first and then becomes the source of a cardioembolic stroke. Left ventricular thrombus formation has been described as a complication in approximately 2.5% of patients with Takotsubo cardiomyopathy; one-third of these cases are cardioembolic.²³ There has also been suggestion that extensive brainstem ischemia may induce autonomic disturbances and cause Takotsubo cardiomyopathy.²⁴ Therefore, based on the history, physical examination findings, and ECG, the best unifying diagnosis that can explain the entire clinical picture is Takotsubo cardiomyopathy induced by an ischemic stroke.

CASE OUTCOME

While in the ED, a CT aortogram was performed that showed no evidence of an acute aortic dissection. Neurology and cardiology consults were called. Based on the patient's clinical presentation and ECG findings, there was unanimous agreement that the patient should undergo emergent cardiac catheterization. The patient's coronary angiogram showed no evidence of occlusive vascular disease or coronary vasospasm after provocative testing with acetylcholine. A left ventriculogram revealed apical ballooning (dyskinesia) and hypercontractility of the left ventricular base. Based on the cardiac catheterization findings, the patient was diagnosed with Takotsubo cardiomyopathy, a stress-related cardiomyopathy. The patient was admitted to the cardiac care unit. The second set of cardiac markers, 8 hours after the first, revealed a troponin T of 0.67 ng/mL and a CK of 372 U/L. The creatine phosphokinase MB isoenzyme (CK-MB) fraction was 40.25 (normal is < 4.8 ng/mL), and the CK-MB relative index was 9.1 (normal is < 2.5). There was no further rise in the serum levels of CK or troponin T. The patient had a transthoracic echocardiogram (TTE) that confirmed the wall motion abnormalities present on left ventriculogram. The patient's ejection fraction was estimated at 35%. No thrombus was seen on TTE. On the third hospital day, the patient had a brain MRI/magnetic resonance angiography that confirmed an acute ischemic stroke in

the left internal and external capsules of the basal ganglia. The patient was treated with aspirin, nitrates, furosemid, and fluid restriction. The rest of the patient's hospital course was unremarkable and she remained free of chest pain and neurological sequelae. On the fourth day of the patient's hospitalization, a repeat TTE revealed an ejection fraction of 45%. The patient was discharged from the hospital after 5 days and follow-up appointments were scheduled with neurology and cardiology. The patient remained asymptomatic and had another TTE after 1 month. The TTE showed symmetric left ventricular contractility and an ejection fraction 60%.

DISCUSSION

Takotsubo cardiomyopathy (also known as stress-induced cardiomyopathy, transient apical ballooning, and broken heart syndrome) is a pathological condition of the left ventricular myocardium triggered by intense physical or emotional stress. Takotsubo cardiomyopathy was first described by Sato et al.²⁵ in 1990 in Hiroshima, Japan. The clinical presentation of Takotsubo cardiomyopathy mimics ACS, and the most common presenting symptom in Takotsubo cardiomyopathy is chest pain, although dyspnea, syncope, and weakness are common.²⁶ In English the Japanese word "takotsubo" means octopus trap. During the systolic phase of the cardiac cycle, the left ventricle of a patient with Takotsubo cardiomyopathy closely resembles an octopus trap (Figure 3). In Takotsubo cardiomyopathy, left ventriculography or echocardiography reveals apical dyskinesia (ballooning) and compensatory hyperkinesis of the basal wall (Figure 4). There can be no evidence of arterial occlusion or acetylcholine-induced vasospasm. However, transient dyskinesia of the midventric-

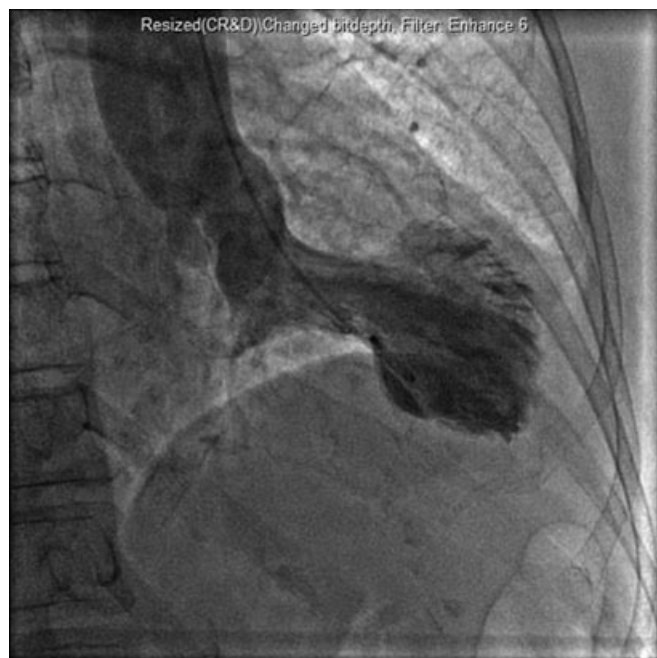

Figure 3. Ventriculogram of a patient with Takotsubo cardiomyopathy during systolic phase.

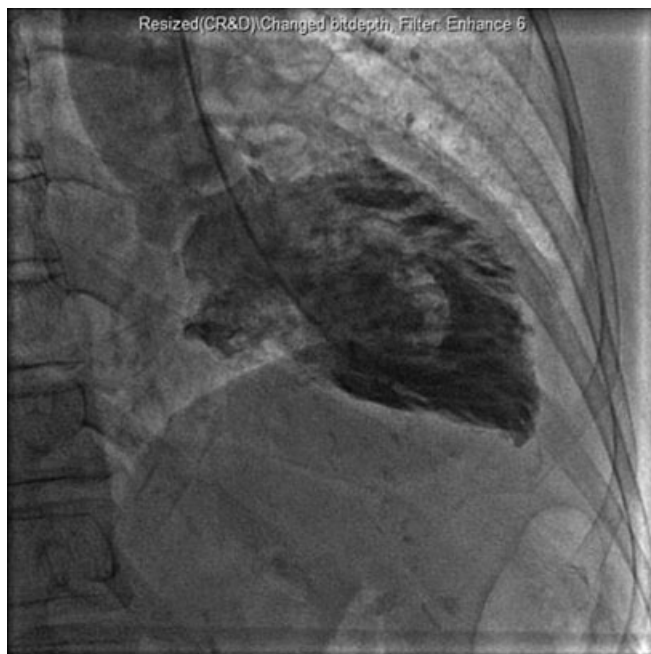

Figure 4. Ventriculogram reveals apical ballooning observed in Takotsubo cardiomyopathy.

ular portion of the left ventricle rather than the apex is seen in a minority of patients with Takotsubo cardiomyopathy.²² Usually, the troponin, CK, and CK-MB fractions are mildly elevated but will not reach the levels seen in a STEMI.²⁶ The cardiac markers may also remain normal for the course of the illness.

While the pathophysiological mechanism responsible for the development of Takotsubo cardiomyopathy is still unknown, it is thought that patients with Takotsubo cardiomyopathy have an excess release of catecholamines from the adrenal medulla in response to stress resulting in left ventricular wall motion abnormalities.²⁶ A small case series found serum catecholamine levels in patients with Takotsubo cardiomyopathy to be 7 to 34 times the normal reference values. In contrast, serum catecholamine levels in patients with a Killip class III MI were two to three times higher than normal reference values.²⁶ In Takotsubo cardiomyopathy, a sudden emotional stress or medical illness induces a surge of activity in the sympathetic nervous system. Sympathetic neurotransmission stimulates the release of catecholamines from the adrenal medulla into the systemic circulation. Evidence suggests that the apical myocardium is most sensitive to elevated catecholamine levels.²⁶ Therefore, it follows that the apex of the LV is the segment that is most susceptible to catecholamine induced cardiotoxicity. This may result from there being a higher density of beta-1 adrenergic receptors in the apex of the LV. The cardiotoxic effects of catecholamine excess are thought to occur by two distinct mechanisms. Catecholamine excess stimulates an influx of extracellular calcium into the cardiac myocytes. The calcium influx will induce cellular dysfunction and/or necrosis while catecholamines generate free radical oxygen species that are toxic to cardiac myocytes.

There is also evidence to support the theory that catecholamine excess can induce vasospasm in the coronary microcirculation, producing ischemia that cannot be detected by coronary angiography.²⁶ Nearly 90% of Takotsubo cardiomyopathy cases occur in postmenopausal females, suggesting a biological predisposition to the development of Takotsubo cardiomyopathy.²⁶

A systematic review of four small case series found that Takotsubo cardiomyopathy was responsible for 2% of all patients who were admitted to the hospital with a suspected diagnosis of ACS.²⁶ However, the true incidence and prevalence of Takotsubo cardiomyopathy remains unknown, although recent literature suggests it is underreported. In the past few years, there has been a surge of interest in Takotsubo cardiomyopathy as physicians are now recognizing the phenomena more often. Like acute exacerbation of congestive heart failure, treatment of Takotsubo cardiomyopathy is supportive with diuretics and vasodilators. Since serum catecholamine levels are already elevated in Takotsubo cardiomyopathy, the use of vasopressors and inotropes is discouraged. Intraaortic balloon pump insertion may be necessary in patients with severe hemodynamic compromise. If medical treatment is provided quickly, patients with Takotsubo cardiomyopathy have an excellent prognosis. Indeed, the average ejection fraction at 3-week follow-up in patients with Takotsubo cardiomyopathy is 60%, and the hospital mortality rate is 0%–8%.^{26,27}

In a prospective analysis of 569 patients with acute ischemic stroke, seven developed Takotsubo cardiomyopathy.²⁴ In this study, all the patients who developed Takotsubo cardiomyopathy were postmenopausal women with stroke acting as the culprit “stressor.” Published in November 2008, this was the first study to report the development of Takotsubo cardiomyopathy in patients with an acute ischemic stroke.²⁴ It is well known that patients with devastating neurological injuries often develop ischemic ECG changes and left ventricular wall motion abnormalities (e.g. subarachnoid hemorrhage).²⁸ The term for cardiac dysfunction secondary to brain injury is neurogenic stunned myocardium. There is strong evidence that a catecholamine surge is responsible for the development of cardiac dysfunction after neurological injury. Histologically, contraction band necrosis is a unique form of myocyte injury associated with a milieu of excess serum catecholamines, seen in neurogenic stunned myocardium, Takotsubo cardiomyopathy, pheochromocytoma, and in people who die a sudden frightening death (e.g. fatal asthma).²⁶ By contrast, polymorphonuclear inflammation is seen on histological staining of cardiac myocytes after an MI. This suggests that there is a link between emotional stress and cardiac dysfunction. Another similarity between Takotsubo cardiomyopathy and neurogenic stunned myocardium is that the overwhelming majority are post-menopausal women.²⁶ However, the majority of patients with neurogenic stunned myocardium develop left ventricular wall motion abnormalities that are identified at the basal and mid-ventricular segments, rather than the apical segment as seen in Takotsubo cardiomyopathy.²⁶ More studies will be necessary

to elucidate the relationship between catecholamine excess, Takotsubo cardiomyopathy, neurogenic stunned myocardium, and left ventricular wall motion abnormalities. Obtaining a greater understanding of the pathophysiology responsible for the development of neurogenic stunned myocardium and Takotsubo cardiomyopathy is essential, as this is the basis for development of therapies that can mitigate the severity duration of both conditions.

CONCLUSIONS

The patient received a final diagnosis of Takotsubo cardiomyopathy precipitated by an acute ischemic stroke. In postmenopausal females, recent literature suggests that the development of Takotsubo cardiomyopathy is not uncommon after an acute ischemic stroke.²⁴ There still remains much to learn about Takotsubo cardiomyopathy. Increasing recognition by physicians promises to make Takotsubo cardiomyopathy a topic of much future interest and fascination.

References

1. Sapira JD. On violating Occam's razor. *South Med J.* 1991; 84:766.
2. Mead NE, O'Keefe KP. Wellen's syndrome: an ominous EKG pattern. *J Emerg Trauma. Shock.* 2009; 2:206–8.
3. Smith S. T/QRS ratio best distinguishes ventricular aneurysm from anterior myocardial infarction. *Am J Emerg Med.* 2005; 23:279–87.
4. Lip G, Manning WJ, Weissman NJ. Left ventricular thrombus after acute myocardial infarction. Available at: <http://www.utdol.com/patients/content/topic.do?topicKey=~TmTyXs0z.eR0CA>. Accessed Jun 18, 2010.
5. Pollack M. ECG Manifestations of selected extracardiac diseases. *Emerg Med Clin N Am.* 2006; 24: 133–43.
6. Dudich K, Bhadelia R, Srinivasan J. Anomalous vertebral artery origin may be an independent risk factor for arterial dissection. *Eur J Neurol.* 2005; 12:571–2.
7. Komiyama M, Morikawa T, Nakajima H, Nishikawa M, Yasui T. High incidence of arterial dissection associated with left vertebral artery of aortic origin. *Neurol Med Chir (Tokyo).* 2001; 41:8–12.
8. Hagan PG, Nienaber CA, Isselbacher EM, et al. The International Registry of Acute Aortic Dissection (IRAD): new insights into an old disease. *JAMA.* 2000; 283:897–903.
9. Wiesenfarth JM. Dissection, Aortic. Available at: <http://emedicine.medscape.com/article/756835-overview>. Accessed Jun 19, 2010.
10. Gaul C, Dietrich W, Erbguth FJ. Neurological symptoms in aortic dissection: a challenge for neurologists. *Cerebrovasc Dis.* 2008; 26:1–8.
11. Stokman PJ, Nandra CS, Asinger RW. Left ventricular thrombus. *Curr Treat Options Cardiovasc Med.* 2001; 3:515–21.
12. Mollet NR, Dymarkowski S, Volders W, et al. Visualization of ventricular thrombi with contrast-

- enhanced magnetic resonance imaging in patients with ischemic heart disease. *Circulation*. 2002; 106:2873–6.
13. Griffin BP, Topol EJ. *Manual of Cardiovascular Medicine*, 3rd ed. Philadelphia, PA: Lippincott Williams and Wilkins, 2009, p. 64.
 14. Narasimhan S. Unexplained constitutional symptoms, weight loss and the heart. *J Med Sci Res*. 2007; 2:49–50.
 15. Sharma GK, Prisant LM. Atrial Myxoma. Available at: <http://emedicine.medscape.com/article/151362-overview>. Accessed Jun 19, 2010.
 16. Reynen K. Cardiac myxomas. *N Engl J Med*. 1995; 14:1610–17.
 17. Goswami KC, Shrivastava S, Bahl VK, Saxena A, Manchanda SC, Wasir HS. Cardiac myxomas: clinical and echocardiographic profile. *Int J Cardiol*. 1998; 63:251–9.
 18. Ha JW, Kang WC, Chung N, et al. Echocardiographic and morphologic characteristics of left atrial myxoma and their relation to systemic embolism. *Am J Cardiol*. 1999; 83:1579–82.
 19. Lee VH, Connolly HM, Brown RD Jr. Central nervous system manifestations of cardiac myxoma. *Arch Neurol*. 2007; 64:1115–20.
 20. Lehrman KL, Prozan GB, Ulyot D, et al. Atrial myxoma presenting as acute myocardial infarction. *Am Heart J*. 1985; 110:1293–5.
 21. Panos A, Kalangos A, Sztajzel J. Left atrial myxoma presenting with myocardial infarction. Case report and review of the literature. *Int J Cardiol*. 1997; 62:73–5.
 22. Tako-Tsubo Syndrome. Available at: <http://www.takotsubo.com/>. Accessed Apr 2, 2009.
 23. Lee W, Profitis K, Barlis P, Van Gaal WJ. Stroke and Takotsubo cardiomyopathy: is there more than just cause and effect? [Letter to the Editor]. *Int J Cardiol*. 2009 Mar 25 [Epub ahead of print].
 24. Yoshimura S, Toyoda K, Ohara T, et al. Takotsubo cardiomyopathy in acute ischemic stroke. *Ann Neurol*. 2008; 64:547–54.
 25. Sato H, Tateishi H, Uchida T, et al. Tako-Tsubo-like left ventricular dysfunction due to multivessel coronary spasm. In: Kodama K, Haze K, Hori M (eds). *Clinical Aspect of Myocardial Injury: From Ischemia to Heart Failure [in Japanese]*. Tokyo, Japan: Kagakuhyoronsha Publishing Co., 1990, pp 56–64.
 26. Wittstein IS, Thiemann DR, Lima JA, et al. Neurohumoral features of myocardial stunning due to sudden emotional stress. *N Engl J Med*. 2005; 352:539–48.
 27. Bahlmann E, Schneider C, Krause K, et al. Tako-Tsubo cardiomyopathy characteristics in long-term follow-up. *Int J Cardiol*. 2008; 124:32–9.
 28. Lemke D, Hussain S, Wolfe T, et al. Tako-Tsubo cardiomyopathy associated with seizures. *Neurocrit Care*. 2008; 9:112–7.