

# Internal carotid and ipsilateral type II proatlantal artery stenoses causing simultaneous hemispheric and vertebrobasilar transient ischemia

Ludovic Berger, MD, Djelloul Gouicem, MD, El Djoulene Lebied, MD, Aurélien Felisaz, MD, Olivier Coffin, MD, and Dominique Maiza, MD, *Caen, France*

A case of persistent proatlantal artery (PA) is described in a 60-year-old woman who presented with cerebellar ataxia, homonymous hemianopia, and aphasia. Both Doppler scan and magnetic resonance angiography (MRA) showed agenesis of both vertebral arteries, 80% stenosis of the left internal carotid artery (ICA), and an anastomotic vessel between the left external carotid artery (ECA) and the left vertebral artery (LVA) with a tight stenosis at the origin. It was thought to be a type II PA. Both lesions were successfully treated by ICA endarterectomy and common carotid artery to PA bypass. This case demonstrates the clinical significance of persistent PA in the evolution of an ischemic cerebrovascular disease. (*J Vasc Surg* 2011;53:475-7.)

Type II PA is an exceptionally persistent artery of the carotid-vertebral embryonic channel coming from the ECA.<sup>1</sup> This variation is often discovered incidentally during an angiography.

We present a case with symptomatic lesions of both left ICA and homolateral type II proatlantal vertebral artery's origin undergoing carotid endarterectomy and carotid to PA bypass.

## CASE REPORT

A 60-year-old right-handed woman was referred to our consultation because of symptomatic tight stenosis of the left ICA. She had a medical history of diabetes mellitus, dyslipidemia, hypertension, and bilateral saphenous vein stripping.

Cerebellar ataxia, homonymous hemianopia (left visual field), and aphasia occurred 3 weeks before, which resolved in less than 1 hour. A left severe ICA stenosis ( $V_{max}$ :  $3.2 \text{ m.s}^{-1}$ ) and no vertebral artery were shown by duplex scan.

MRA confirmed the 80% stenosis (North American Symptomatic Carotid Endarterectomy Trial criteria) of the left ICA, and revealed a PA persistence arising from the left ECA with a stenosis at its origin, and an agenesis of right vertebral artery (Fig 1). These lesions were associated with a slight irregularity of both carotid siphons and right middle cerebral artery occlusion.

Cerebral magnetic resonance imaging revealed brainstem, right occipital (correlated with the left hemianopia), and left cerebella infarctions.

From the Department of Vascular Surgery, Centre Hospitalier Universitaire Caen.

Competition of interest: none.

Reprint requests: Ludovic Berger, MD, Centre Hospitalier Universitaire Caen, Avenue de la Cote de Nacre, 14000 Caen, France (e-mail: berger-l@chu-caen.fr).

The editors and reviewers of this article have no relevant financial relationships to disclose per the JVS policy that requires reviewers to decline review of any manuscript for which they may have a competition of interest.

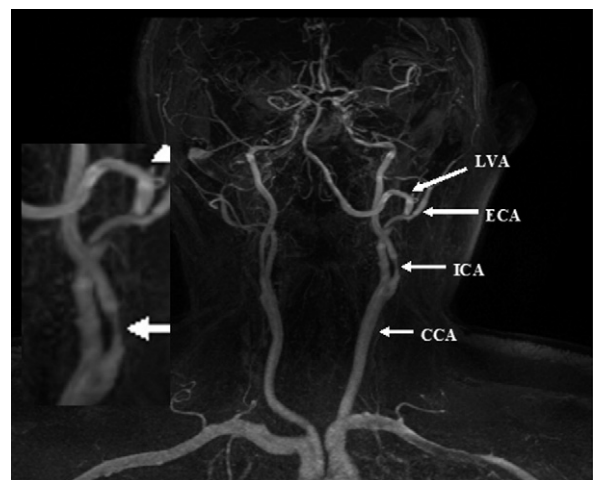
0741-5214/\$36.00

Copyright © 2011 by the Society for Vascular Surgery.

doi:10.1016/j.jvs.2010.08.017

Transcranial Doppler scan showed a decreased flow in the left middle cerebral artery (v:  $42 \text{ cm.s}^{-1}$ ), a normal flow in the basilar artery, and a functional circle of Willis.

We decided to perform a left ICA endarterectomy and a common carotid artery (CCA) to PA bypass by cervical longitudinal approach associated with a section of the biventer cervicis. Intravenous heparin (200 UI/kg) was injected prior to cross-clamping and was reversed by protamine-sulfate after completion of the procedure. The patient was operated on while under general anesthesia, without shunting or monitoring of cerebral functions, and we did no completion angiography after the procedure. The CCA to PA bypass was performed first with a 5 mm diameter polytetrafluoroethylene graft due to the absence of usable saphenous vein. With sequential clamping, we performed the proximal

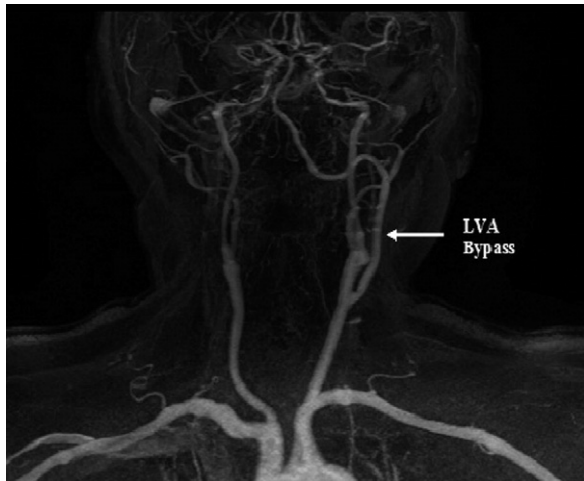


**Fig 1.** Magnetic resonance angiography (MRA) of a left proatlantal artery (PA) arising from the external carotid artery (ECA) with a tight stenosis at its origin, associated with a stenosis of the internal carotid artery (ICA). Note the loss of the right vertebral artery and the thrombosis of the right middle cerebral artery. CCA, Common carotid artery; LVA, left vertebral artery.

side-to-end anastomosis, then the distal end-to-end anastomosis on the vertebral artery after resection of its proximal part.

Back bleeding from the left carotid was sufficient under controlled hypertension (150 mm Hg systolic blood pressure). CCA was clamped downstream from the origin of the bypass to perform carotid endarterectomy using the eversion technique.

Hemispheric deficit (hemiplegia and aphasia) appeared 2 hours after the operation. A computed tomography scan showed CCA to PA bypass thrombosis, good aspect of the endarterectomy, and no additional cerebral lesion. Reoperation was performed with a bypass thrombectomy and revision.



**Fig 2.** Control magnetic resonance angiography (MRA) of the left common carotid artery (CCA) to proatlantal artery (PA) bypass and internal carotid artery (ICA) endarterectomy. LVA, Left vertebral artery.

The deficit disappeared 12 hours after reoperation, and transcranial Doppler scan demonstrated a posterior cerebral artery flow improvement.

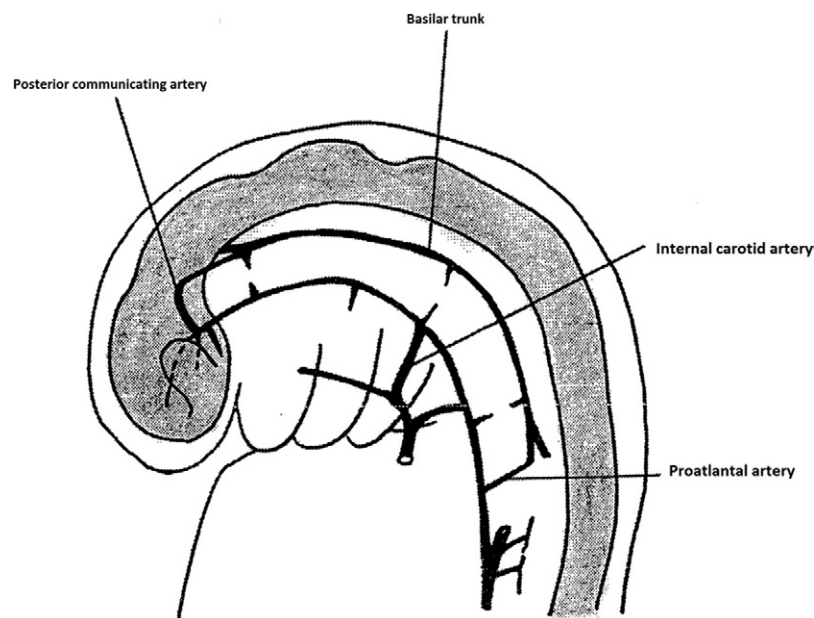
Postoperative MRA revealed a satisfying morphological result with a patent arterial reconstruction (Fig 2). The patient left the hospital 7 days postsurgery without any neurological deficit and no more adverse events after the reoperation.

## DISCUSSION

Carotid-basilar anastomosis between the ICA and vertebro-basilar system are temporarily present during embryogenesis. These communications may sometimes persist at adulthood and are occasionally found on angiography. PA persistence is a very rare abnormality. PA persists until the second phase of Padgett's classification (5- to 6-mm embryo; Fig 3).<sup>2</sup> In the third phase (7- to 12-mm embryo), after the development of VAs and connection with the basilar artery, the proatlantal intersegmental artery obliterates. According to embryological development, persistence of carotid basilar anastomosis is often associated with hypoplasia or agenesis of vertebral arteries as noted in this case.<sup>3,4</sup>

According to the Lasjaunias classification, there are two types of proatlantal intersegmental artery. Type I corresponds to the first segmental artery and arises from the cervical ICA. Type II arises from the ECA and corresponds to the second segmental artery.<sup>5</sup>

Thirty cases of PA type II are described in the literature.<sup>6</sup> Only 2 patients had symptomatic lesions and we did not find any case describing both symptomatic lesions of the ICA and ipsilateral PA. Furthermore, our patient suf-



**Fig 3.** Schematic showing embryonal cerebral circulation at the second phase of Padgett's classification. Note the proatlantal artery.

ferred both carotid and vertebrobasilar territory symptoms due to these lesions.

The anomalous carotid-vertebral anastomoses associated with ICA stenosis may be successfully treated by means of a carotid endarterectomy.<sup>7-10</sup>

This case is particularly technically challenging because of two-staged stenosis. The use of a shunt was anatomically difficult.<sup>10</sup> Even if routine use of cerebral monitoring and a shunt is recommended, in our experience, high blood pressure is sufficient in most cases, especially when a complete circle of Willis coexists.<sup>7,8,10</sup>

Some authors have reported ICA lesions with proatlantal intersegmental artery treated by an endovascular approach.<sup>11,12</sup> We found that this was not a good indication due to the high embolic risk with these symptomatic lesions during the catheterism or the ICA stenting covering the ECA. The surgical approach appeared to be safest and allowed a complete treatment of both lesions.

This is the first case reported of tandem lesions of ICA and type II PA responsible for symptoms in both anterior and posterior cerebral territories. We must keep in mind the interest of imaging in front of similar cases and that the presence of PA implies a challenging management for the choice of treatment of these lesions.

## REFERENCES

1. Lasjaunias P, Théron J, Moret J. The occipital artery. Anatomy-normal arteriographic aspects-embryological significance. *Neuroradiology* 1978;15:31-7.
2. Padget DH. The development of the cranial arteries in the human embryo. *Embryol Carnegie Inst* 1948;205:212-32.
3. Anderson RA, Sondheimer FK. Rare carotid-vertebrobasilar anastomoses with notes on the differentiation between proatlantal and hypoglossal arteries. *Neuroradiology* 1976;11:113-8.
4. Lui CC, Liu YH, Wai YY, Tsai CC. Persistence of both proatlantal arteries with absence of vertebral arteries. *Neuroradiology* 1987;29:304-5.
5. Lasjaunias P, Berenstein A. *Surgical neuroangiography*, vol 1. New York: Springer-Verlag; 1986. pp. 123-8.
6. Papon X, Pasco A, Villapadierna F, Brillu C, Picquet J, Jousset Y, et al. Variations et anomalies anatomiques du système vertébro-basilaire. In: Kieffer E, Rancurel G, Koskas F, editors. *Chirurgie de l'artère vertébrale*. Paris: AERC; 2001.
7. Ouriel K, Green RM, DeWeese JA. Anomalous carotid-basilar anastomoses in cerebrovascular surgery. *J Vasc Surg* 1988;7:774-7.
8. Pulli R, Gatti M, Pratesi C. Carotid endarterectomy in rare bilateral carotid-vertebral anastomosis. *J Vasc Surg* 2001;33:1122-4.
9. Thayer WP, Gaughen JR, Harthun NL. Surgical revascularization in the presence of a preserved primitive carotid-basilar communication. *J Vasc Surg* 2005;41:1066-9.
10. Grego F, Stramanà R, Lepidi S, Antonello M, Bonvini S, Zamarella M, et al. Primitive proatlantal intersegmental artery and carotid endarterectomy. *J Vasc Surg* 2004;39:691.
11. Bour P, Bracard S, Frisch N, Frisch R, Fiévé G. Persistent proatlantal artery associated with carotid artery stenosis treatment by percutaneous transluminal balloon angioplasty. *Ann Vasc Surg* 1991;5:38-40.
12. Morales M, Anacleto A, Berbert M, Mello M, Céntola C, Piccinato CE, et al. Endovascular treatment for recurrent carotid stenosis in a patient with proatlantal intersegmental artery. *J Vasc Interv Radiol* 2006;17(2 Pt 1):399-400.

Submitted May 27, 2010; accepted Aug 6, 2010.