

REVIEW

Supernumerary phantom limbs in spinal cord injury

A Curt¹, C Ngo Yengue¹, LM Hilti² and P Brugger²

¹Spinal Cord Injury Centre, University Hospital Balgrist, University of Zürich, Zurich, Switzerland and ²Department of Neurology, University Hospital, Zurich, Switzerland

Study design and objectives: Case report and review of supernumerary phantom limbs in patients suffering from spinal cord injury (SCI).

Setting: SCI rehabilitation centre.

Case report: After a ski accident, a 71-year-old man suffered an incomplete SCI (level C3; AIS C, central cord syndrome), with a C3/C4 dislocation fracture. From the first week after injury, he experienced a phantom duplication of both upper limbs that lasted for 7 months. The supernumerary limbs were only occasionally related to painful sensation, specifically when they were perceived as crossed on his trunk. Although the painful sensations were responsive to pain medication, the presence of the illusory limb sensations were persistent. During neurological recovery, the supernumerary limbs gradually disappeared. A rubber hand illusion paradigm was used twice during recovery to monitor the patient's ability to integrate visual, tactile and proprioceptive stimuli.

Conclusion: Overall, the clinical relevance of supernumerary phantom limbs is not clear, specific treatment protocols have not yet been developed, and the underlying neural mechanisms are not fully understood. Supernumerary phantom limbs have been previously reported in patients with (sub)cortical lesions, but might be rather undocumented in patients suffering from traumatic SCI. For the appropriate diagnosis and treatment after SCI, supernumerary phantoms should be distinguished from other phantom sensations and pain syndromes after SCI.

Spinal Cord (2011) 49, 588–595; doi:10.1038/sc.2010.143; published online 16 November 2010

Keywords: supernumerary phantom limb; traumatic quadriplegia; rubber hand illusion

Introduction

Following lesion of the central nervous system, phantom sensations may be reported beyond that of typical sensory deficits (that is, hypo/anesthetic and analgesic dermatomes) or pain syndromes (negative symptoms), but rather as peculiar sensory 'positive symptoms' (Figure 1; for review, see Ramachandran *et al.*¹). In cases of spinal cord injury (SCI), these symptoms range from non-painful referred sensations, phantom limb sensations, and position illusions to disabling and, sometimes, persistent conditions of phantom limb pain in deafferented areas of the body.² After peripheral nerve lesions, like in limb amputation, phantom sensations may be felt similar to the phantom phenomena experience of SCI, and be reported as either painful or non-painful perceptions.¹ After SCI, the dissociation of painful and non-painful phantom sensations (that is, phantom limb illusions) from neuropathic limb or whole-body pain syndromes (that is, bilateral neuropathic pain of the buttocks and lower limbs in deafferented areas of the body) is important for appropriately treating sensory deficits.

Besides these sensory alterations in lost or deafferented limbs, the appearance of additional, 'supernumerary' limbs is a well-known phenomenon in central nervous system disorders. Such illusions of additional body parts are frequently reported after cortical damage^{3–6} or subcortical lesions.^{7,8} The dissociations between motor intentions and executive abilities may lead to apparently bizarre and 'alien' behavior of the supernumerary limb.^{9–11} In contrast, supernumerary limb sensations represent a rather rare phenomenon after SCI. However, such a condition may be underreported, due in part to a combination of unawareness on the clinicians' behalf and a patient's reluctance to report something so unusual.

Here, we report about a patient with an incomplete quadriplegia after traumatic SCI, who developed a phantom duplication of the upper limbs. The course of the supernumerary phantoms of this individual case will be reviewed in relation to that known from other neurological disorders in general and in SCI in particular.

Case report

A 71-year-old man was involved in a ski accident resulting in an acute SCI due to cervical hyperextension. Apart from an

Correspondence: C Ngo Yengue, Spinal Cord Injury Centre, University Hospital Balgrist, University of Zürich, Forchstrasse 340, Zurich 8008, Switzerland.
E-mail: Christine.yengue@balgrist.ch
Received 22 June 2010; revised 31 August 2010; accepted 1 September 2010; published online 16 November 2010

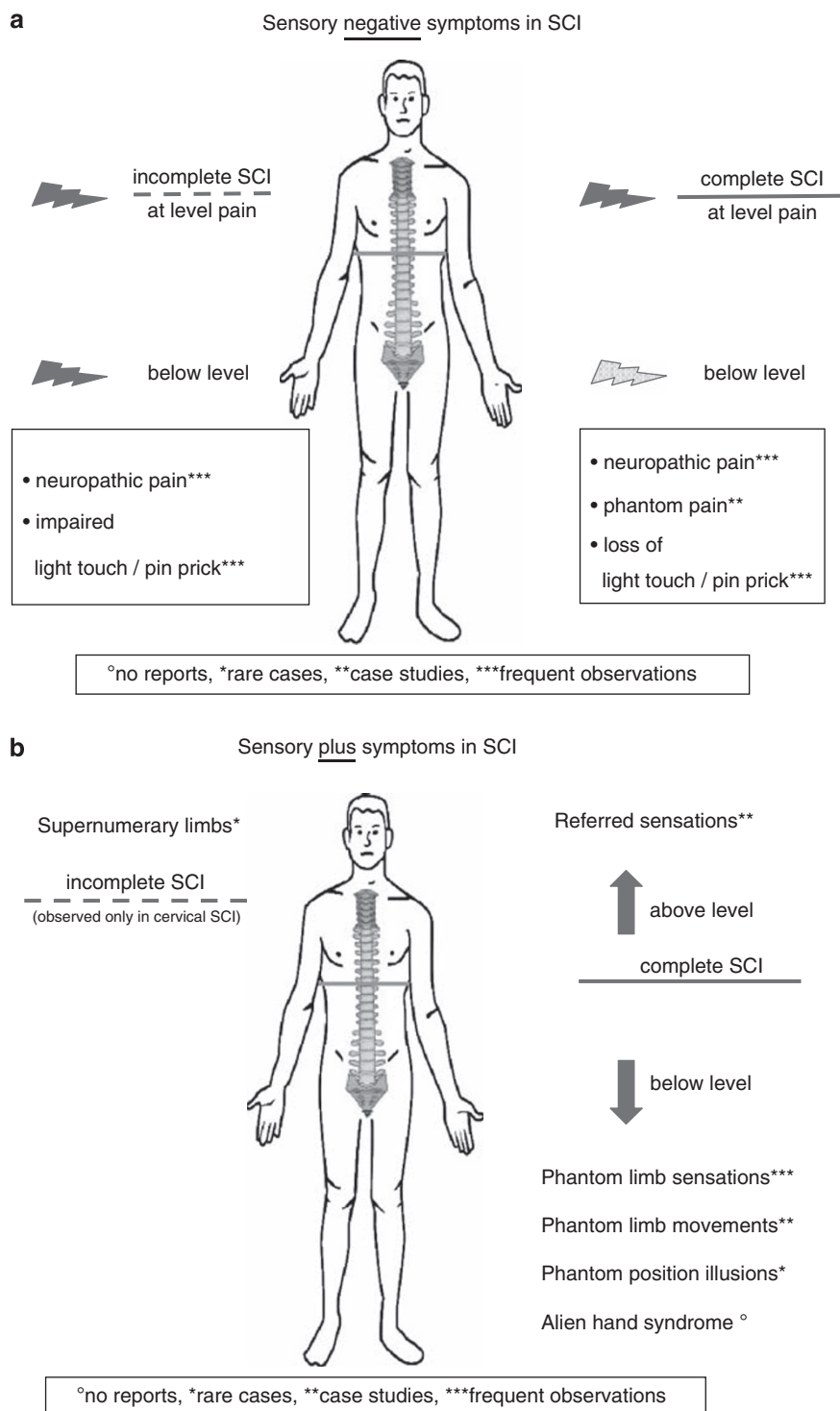


Figure 1 Distribution and relative frequency of symptoms regarding sensory deficits and pain syndromes (a, negative symptoms) and additional sensory perceptions (b, positive symptoms).

uneventful total hip joint replacement due to arthritis 1 year before the injury, previous medical history had been bland (no previous medication).

The major *spine trauma* consisted of a C3/C4 discoligamentous disruption and a fracture of the processus spinosus of the fourth cervical vertebra. Furthermore, there

was a dissection of the left vertebral artery without obvious neurological sequel like dysphasia, dysarthria, or any other brain stem symptoms (including dysmetric and ataxic movements) and a fracture of the nasal bone. On the day of injury, a ventral spondylodesis with the use of H-plate after C3/C4 discectomy and an autologous spongiosa plastic

was performed. The patient was ventilator-dependent for 2 weeks post operatively.

Neurologically (according to the International Standards for Neurological Classification of spinal cord injury), the patient suffered an incomplete and eventually spastic quadriplegia level C3.¹² Initially, the upper extremities motor score was 0 and the lower extremities motor score was 2. These scores improved to 31 and 46, respectively, at the end of rehabilitation, that is, 8 months. By clinical standards, the impairment was most severely affecting the upper limbs, thus corresponding to a diagnosis of central cord syndrome. Total light touch and pin prick scores were initially at 56 and 62, respectively, and remained rather unchanged on follow-up.

Somatosensory evoked potentials were initially abolished for the ulnar nerves and recordable, but severely deteriorated for the tibial nerves. Follow-up recordings at 3 and 6 months after injury revealed an improvement of all Somatosensory evoked potentials, but the latencies remained severely delayed (Figure 2). Motor nerve conduction studies of the ulnar and tibial nerves revealed no signs of peripheral neuropathy, but slightly reduced amplitudes of the ulnar nerves, corresponding to a mild alpha-motoneuron lesion (ventral horn damage). The nerve conduction studies of the tibial nerves remained normal.

Neuro-imaging 3 and 7 months after the injury of the cervical cord showed a well-defined post-traumatic cyst at the level C3/C4 that remained stable between examinations (Figure 3). The MRI of the brain was without any pathological findings.

Phantom sensations appeared on day 7 after trauma and primarily consisted of an illusory additional pair of upper limbs originating from the shoulder joints and extending at normal length laterally to the patient's paralyzed arms. These sensations changed during the course of the day, hardly noticeable in the morning and perceived with increasing vividness during the afternoon and evening. The sensations of the phantom limbs depended on body posture; most prominent in a horizontally reclined position and rarely

present during sitting. Regardless, the supernumerary arms were not usually associated with pain and the patient was not complaining about any neuropathic pain within the upper limbs. When the supernumerary phantom arms were experienced, the patient was not able to remove them completely from his trunk or to make them disappear. When trying actively to touch the phantom limb with his real limbs, the phantom limb would move away in the same direction and always parallel to the real limb. The supernumerary phantoms were never visualized. Looking at the place where they were experienced did not diminish the phantom percept. At times, the phantom arms were not experienced as parallel to the real arms, but were felt to be crossed over the trunk. This sensation was very vivid, always disagreeable to the patient and, occasionally, painful. During such periods of painful sensations, the administration of morphine (5 mg subcutaneous injection) reduced the pain intensity but did not change the posture of the illusory limbs. The same was true for a variety of non-steroidal anti-inflammatory drugs and neuropathic pain medications (that is, pregabalin).

During the course of recovery, that is parallel to the improvement of motor (and less so of sensory) functions, the breach-off, size and vividness of the phantom limbs changed. Initially after SCI, the point of origin had been the shoulder joints and the patient felt the left phantom limb more intense than the right. By 4 months, only phantom forearms originating at the elbow joints were reported, and by 5 months after injury, a mere pair of phantom hands protruded from the wrists and the right phantom hand was now more vivid than the left. In general, the intensity of phantom sensations had weakened over the 5 months since the SCI and by 7 months, the left phantom hand sensations had completely subsided and the awareness of the right phantom hand was still fainter. At discharge, 8 months after the SCI, the patient reported no illusory limb sensations.

A rubber hand illusion (RHI) paradigm was applied to assess the patient's illusory displacement of his

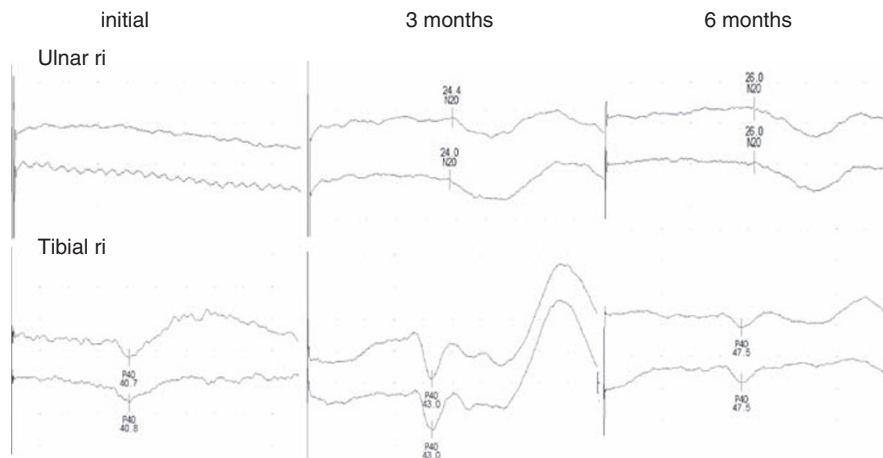


Figure 2 Follow-up recordings of ulnar and tibial nerve somatosensory evoked potentials (only right site displayed) initially after injury until 6 months disclosing a significant recovery of spinal cord function.

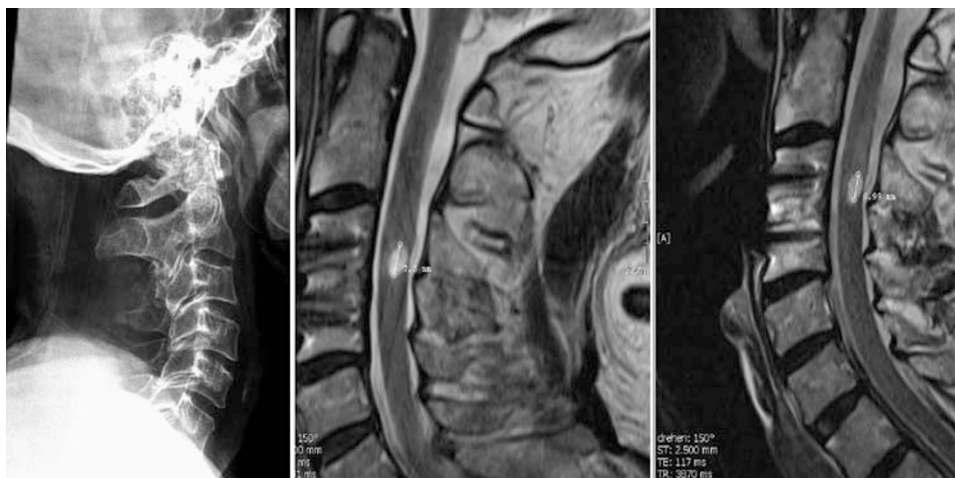


Figure 3 Initial cervical X-ray with minimal dislocation C3/C4 and follow-up MRIs of the cervical spinal cord 3 and 7 months after SCI. Sagittal T2-weighted SE images showing a post-traumatic cyst at level C3/C4.




Figure 4 Experimental set up for the RHI. The seen rubber hand, lying in front of the subject, and the unseen real right hand, lying parallel next to it, are stimulated by brushing the fingers either synchronously on identical parts or asynchronously with a time delay.

touched hand. In the RHI, tactile stimulation is provided simultaneously to the same location on a participant's invisible hand and visible rubber hand (see Figure 4). The visual observation of a rubber hand being touched at a corresponding location to the real hand leads to a proprioceptive drift towards the rubber hand. Ultimately, the real hand of the participant appears to be displaced towards the visible rubber hand.^{13,14} Based on our clinical findings, we predicted enhanced illusion susceptibility because of the breakdown in proprioceptive-tactile integration, presumably at the basis of the supernumerary phantom limbs. The local Ethics Committee had approved the study and informed consent was obtained from the patient before testing. It was repeated in identical form 3 months from the initial examination. At both test times, the critical illusion-inducing condition (synchronous visual-tactile stimulation) was accompanied by a control condition (asynchronous

stimulation). In the control condition, owing to asynchronous stimulation, an illusion should not be reported.^{13–16}

The patient was tested in a sitting position, in which he hardly ever reported experiencing phantom sensations (see Figure 4 for the set up). Both arms were stretched out, and the right hand was covered from his view. A right rubber hand was placed in the same orientation 20 cm to the left of the patient's real right hand, and the patient was requested to observe the examiner brush the rubber hand. Before the illusion induction procedure, it was established that touch to the patient's hand alone (that is, without visual observation of touch) could be reliably detected.

Illusion strength was quantified by measuring proprioceptive drift and by the patient's responses to a brief questionnaire, according to published standards.^{13,14} Proprioceptive drift was assessed by having the patient indicate the felt position of his invisible middle finger by means of rulers with arbitrary scaling (four trials before and after each of the two conditions). The questionnaire required the patient to provide a Likert-type rating (-3 for 'strongly disagree' to +3 for 'strongly agree') to three critical and six control questions as introduced by Botnivick and Cohen.¹³

On first testing (4 months after SCI), the patient reported the sudden appearance of his right phantom arm a few minutes after onset of the vision-touch procedure. Testing was nevertheless continued in a standard way, but the assessment of proprioceptive drift and questionnaire data was not possible as the location of the right hand was felt in front of the patient's chest (the usual position of his supernumerary phantom limb). The occurrence of the supernumerary phantom limb was of particular interest given that the patient was sitting. The phantom hand was felt throughout the RHI paradigm (not only during observed touch of the real hand), but disappeared within seconds after removing the rubber hand. No left phantom arm was felt during the procedure.

On second testing (7 months after SCI), identical RHI testing conditions did not elicit the emergence of a supernumerary limb during testing procedures, and consequently,

the proprioceptive drift and questionnaire data could be adequately assessed. Although the initial exam could not show any evidence of a RHI (mean drift = 1.0 cm, s.d. = 0.82 away from the rubber hand) owing to illusory sensations, the latter examination did reveal a marked effect that was not present in the control condition (mean rating for critical items = 2.67, s.d. = 0.58; for control items 0.50, s.d. = 1.64).

Discussion

In patients suffering from SCI, the occurrences of referred and phantom sensations are mainly reported when associated with pain. The overall incidence of non-painful phantom sensation is probably underreported, owing in part to the absence of standardized clinical assessment protocols for diagnosis and follow-up observation. Although patients with SCI might be seriously bothered by these mis-sensations, the underlying mechanisms of supernumerary limbs are not fully disclosed and standardized treatment protocols are not available.

Painful phantom sensations in SCI

Phantom sensations accompanying pain is well recognized in patients suffering from SCI, and neuropathic pain syndromes represent one of the most disabling sequels of SCI.^{17–19} In such conditions, SCI patients otherwise with complete loss of sensory input (proprioception, thermoception and nociception) can suffer severe pain within the dermatomal boundaries of deafferented limbs. The incidence and prevalence of neuropathic pain syndromes in distinction to musculoskeletal pain syndromes have been studied in patients suffering from both incomplete and complete chronic SCI.²⁰ Consistent with clinical experience, these studies confirmed that neuropathic pain syndromes are rather long lasting (often persist over many years), and, in general, difficult to treat.²¹

Phantom limb sensation can range from 'non-painful to an awkward experience of the limb' and even 'a continuous severe painful sensation'.^{22,23} Some of these sensations in SCI can manifest themselves very similarly to those in patients after lower limb amputation. However, prospective studies specifically interested in the occurrence and course of phantom pain sensation have rarely been performed in SCI. Based on clinical experience, the incidence seems to be significantly higher in amputees, more than 80% of whom report some kind of phantom sensation mainly associated with a pain syndrome.²⁴

Non-painful phantom sensations in SCI

Painful phantom sensations should be distinguished from non-painful phantom sensations, like illusory limb position and limb sensation that are much less frequently reported in SCI. In contrast to amputees, SCI patients rarely report perceived morphological changes (deformation and telescoping) of their phantom limbs. Nevertheless, the occurrence of phantom limbs in patients suffering from spinal cord disorders has been well established already in the middle of the last century.^{19,25} Onset of unilateral phantom

limb sensation in chronic traumatic SCI patients, who were undergoing unilateral limb amputation for the treatment of non-healing bone infections (2.5–4 years after injury), has been previously described in two patients.²⁶ Bilateral lower limb phantom sensations have also been reported in a non-traumatic SCI patient suffering from transverse myelitis (a supra spinal involvement was not evident by clinical means and brain MRI²⁷), who experienced rather static phantoms, like crossed legs or, occasionally, postural peculiarities (for example, standing on tiptoes). In one case study, a female patient suffering from transverse myelitis D2-D4 described phantom limb sensation and movements of only the right leg.²⁸ These symptoms were transiently present for about 7 days and eventually the spinal deficits partially disappeared over a period of approximately 4 months. In this patient, MRI of the brain was unremarkable and during follow-up exams over a period of about 3 years no further neurological symptoms (that is, no potential signs of multiple sclerosis) were observed.

Position illusions²⁹ are specific phantom sensations presenting as rather static limb positions. These position illusions can last for years after injury and be associated with pain, but mostly leave the complete paraplegic patient with the impression that the limb is 'frozen' in a given position, often as they experienced at the moment of injury. These impressions can be suppressed by vision, but may re-occur spontaneously. They have been described only rarely in the literature and their clinical relevance remains unclear.

Supernumerary phantom limbs in SCI

Beyond phantom limb sensation is the experience of additional limbs, either as single limbs (upper or lower limb) or even as a pair of limbs. These phantom sensations are referred to as supernumerary limbs. Frequently observed in patients suffering from brain disorders,^{3–6,9} supernumerary limbs have only rarely been reported in SCI patients, and predominantly described after incomplete quadriplegia. However, the first description of supernumerary limbs in traumatic SCI³⁰ involved the case of a C5 complete SCI patient reporting an extra pair of legs. More, specifically, the patient experienced tied-up legs with a relaxation after passive leg movements. In 1989, a comparable case of supernumerary limb experience was reported in a 64-year-old male patient sustaining a traumatic (that is, traffic accident) incomplete SCI (that is, quadriplegia) subsequent to a petit mal seizure.³¹ After recovery from the initial medical complications, the patient felt that another pair of upper and lower limbs had grown from his body, which eventually disappeared after about 2 months. Although the authors discussed a number of different aetiologies, obviously the mechanisms related to the supernumerary limb symptoms in this case is confounded by both the apparent seizure disorder and potential sequel of head injury incurred in the accident. Furthermore, their speculation about 'wishful thinking' and a long hospitalization as a potential cause of the phantoms seems unwarranted in light of more recent clinical data. In the literature on non-traumatic spinal cord damage, only two further case studies

could be identified. They concerned two patients, both suffering from a high cervical intramedullary ependymoma, with unilateral supernumerary arms emerging after surgery.^{32,33} In one case, the supernumerary phantom limb persisted over several months, and, interestingly, both patients presented clinically with incomplete focal spinal cord damage without evidence of brain involvement.

Supernumerary limbs in distinction to the alien hand syndromes do appear as a rather static sensation and less dynamic illusions of compulsive limbs with uncontrolled movements.³⁴ In contrast, alien hand syndrome is characterized by involuntary, uncontrollable and purposeless movements that, to our knowledge, have not been reported in patients with quadriplegia.³⁵

Mechanisms underlying phantom sensations and supernumerary phantom limbs

Physiological kinesthetic illusory limb movements can be induced in healthy subjects (for example, by tendon vibration), and activate complex sensory-motor networks (as assessed by functional MRI activation of cortical and subcortical areas) with a limb specific somatotopic representation similar to real movements.³⁶ Phantom limb sensations after traumatic amputation are assumed to originate within the central neural networks inducing these sensations.³⁷ The development of phantom pain, in contrast to non-painful 'normal' phantom limb sensation, is assumed to be based on maladaptive reorganizational changes within the neural networks.³⁸ Interestingly, the representation of hand movement remains intact in upper limb amputees, while an extensive reorganization of adjacent motor areas becomes apparent and might be involved in the preservation of phantom sensations.³⁹ PET/functional MRI studies in amputees with phantom limb pain able to perform controlled virtual movements confirms the preservation of corresponding sensory-motor areas, as well as pain-processing networks (thalamus, anterior and posterior cingulate cortex).^{40,41} Accordingly, Karl *et al.*⁴² showed that non-painful phantom sensations, as well as residual limb sensation were unrelated to motor cortical reorganization in contrast to phantom limb pain. The extent of cortical reorganization was reduced with intensified upper limb training (as measured by the amount of time amputees used the prosthetic devices), which potentially indicates a positive effect of limb activity on phantom limb pain.

In both amputees and SCI patients, the ability to command motor function in limbs being physically lost (amputees) or completely disconnected (complete SCI) remains intact,⁴³ even after long-lasting (several years of complete SCI) non-use of the lower limbs.⁴⁴ The patients often feel they have full motor control over the limb (opening and closing, positioning, movement), which to some extent can be objectively measured by neuropsychological testing and be shown to induce a specific activation pattern of the brain (for example, functional MRI studies).⁴⁵⁻⁴⁷

Although the involved circuits have not been delineated with sufficient preciseness, supernumerary phantom limb sensations are similarly associated with changes in the brain.

The phenomenon has been mainly observed after brain damage by stroke or traumatic brain injury. Halligan *et al.*³ described a case of supernumerary phantom limb with a severe left hemiplegia, sensory loss, hemianopia and neglect after a hematoma within right basal ganglia. One hypothesis suggested that the supernumerary phantom was a direct result of brain damage in the somatosensory areas and adjacent parietal cortex. As a second hypothesis, the authors discussed the phenomenal experience of the phantom as mediating the way the patient comes to represent the effects of hemiplegia.³ A functional MRI study in a stroke patient with a complete hemiplegic-anesthetic upper limb, but supernumerary limb revealed regular activation of the primary sensory-motor cortex areas during imagination of the movement of real and phantom hand.⁴⁸ The mismatch between a central (cortical) movement sensation and compromised thalamocortical feedback loops for the correction between an expected and effective movement has been considered as a basic neurophysiological mechanism underlying phantom limbs.

Course and treatment of phantom and supernumerary limbs

The duration of supernumerary phantoms is clinically unpredictable (persistence varies from months to several years). In the present case, the temporal relation between neurological recovery and eventual ceasing of the supernumerary phantoms is not actually indicating a direct causal relationship. In SCI patients, standardized and internationally recognized treatment protocols are not yet available to appropriately follow phantom sensations. Based on the postulations that maladaptive processes within the neural network (neuromatrix) could be underlying the development of phantom pain, different strategies aiming to normalize the cortical organization have been applied. Visuomotor training (8 weeks) in a cohort of three patients after upper limb amputation and the emergence of phantom limb sensation showed a normalization of the contralateral M1 sensory-motor activation (assessed by functional MRI), paralleled by a reduction of pain (two out of three patients showed a VAS reduction), in comparison to a non-responding patient (that is, no change in VAS), who demonstrated no normalization of the cortical activation pattern.⁴⁹ However, in a recent study applying movement imagery in complete thoracic SCI patients, pain or non-painful phantom sensation became either increased or induced for the first time, and such interventions potentially bear the risk of severe adverse events.⁵⁰

RHI paradigm

The RHI paradigm, to our knowledge applied for the first time in a patient with SCI, may prove useful for monitoring the course of supernumerary phantom limb sensations. Against the background of the patient's central cord syndrome, we predicted a diminished integration of proprioceptive, tactile and visual information, that is, elevated illusion susceptibility. This hypothesis was borne out in initial testing, during which time upper extremities motor score values were still close to zero. Interestingly, the

standard induction procedure of the illusion elicited vivid supernumerary phantom limb sensations in a body posture that was not associated with spontaneous supernumerary limbs (that is, sitting). The perceived position of the phantom did not coincide spatially with the rubber hand, indicating that vision did not 'capture' tactile sensation. This is in line with the patient's report that looking at his paralyzed limbs (or the place where the phantom was perceived) did not interfere with proprioceptive or postural impressions. On second testing (upper extremities motor score around 30), the patient indicated a RHI according to the critical questionnaire items ('It seemed as if I were feeling the touch of the paintbrush in the location where I saw the rubber hand touched'; 'It seemed as though the touch I felt was caused by the paintbrush touching the rubber hand'; 'I felt as if the rubber hand were my hand'). However, no proprioceptive drift was found towards the rubber hand. This again is compatible with the finding that visual input was ineffective in changing the patient's spontaneously occurring phantom limb percept. To summarize, although prospective SCI studies with the RHI paradigm are clearly needed, this procedure could be valuable in disentangling and quantifying the most deficient components of limb awareness (tactile, proprioceptive and visual) and their interactions.

Conclusion

In SCI patients, manifold changes in sensory function can be observed (negative and positive symptoms) and although the emergence of phantom sensations with or without pain are well appreciated, supernumerary phantom limbs have been rarely reported. Although the clinical relevance of the latter phenomena is rather unclear, it might be worthwhile to take notice of these symptoms in order to be responsive to these and other potentially strange and complex sensory complaints by patients.

Conflict of interest

The authors declare no conflict of interest.

Acknowledgements

We are thankful to John Kramer for editorial services.

References

- Ramachandran VS, Hirstein W. The perception of phantom limbs. The D. O. Hebb lecture. *Brain* 1998; **121**(Part 9): 1603–1630.
- Burke DC, Woodward JM. Pain and phantom sensation in spinal paralysis. In: Vinken PJ, Bruyn GW (eds). *Injuries of the spine and spinal cord; Part II*. North-Holland Publishing Company: Amsterdam, 1976 pp 489–499.
- Halligan PW, Marshall JC, Wade DT. Three arms: a case study of supernumerary phantom limb after right hemisphere stroke. *J Neurol Neurosurg Psychiatry* 1993; **56**: 159–166.
- Vuilleumier P, Reverdin A, Landis T. Four legs. Illusory reduplication of the lower limbs after bilateral parietal lobe damage. *Arch Neurol* 1997; **54**: 1543–1547.
- Khateb A, Simon SR, Dieguez S, Lazeyras F, Momjian-Mayor I, Blanke O *et al*. Seeing the phantom: a functional magnetic resonance imaging study of a supernumerary phantom limb. *Ann Neurol* 2009; **65**: 698–705.
- Brugger P. Supernumerary phantoms: a comment on Grossi, *et al.*'s (2002) spare thoughts on spare limbs. *Percept Mot Skills* 2003; **97**: 3–10.
- Donnet A, Schmitt A, Poncet M, Graziani N, Grisoli F. Hallucinations de membres surnuméraires, héminégligence gauche et hypersexualité dans un cas d'hématome capsulo-lenticulaire. *Rev Neurol* 1997; **153**: 587–590.
- Tanaka H, Arai M, Kadowaki T, Takekawa H, Kokubun N, Hirata K. Phantom arm and leg after pontine hemorrhage. *Neurology* 2008; **70**: 82–83.
- Weinstein EA, Kahn RL, Malitz S, Rozanski J. Delusional reduplication of parts of the body. *Brain* 1954; **77**: 45–60.
- Hari R, Hänninen R, Mäkinen T, Jousmäki V, Forss N, Seppä M, Salonen O. Three hands: fragmentation of human bodily awareness. *Neurosci Lett* 1998; **240**: 131–134.
- McGonigle DJ, Hänninen R, Salenius S, Hari R, Frackowiak RS, Frith CD. Whose arm is it anyway? An fMRI case study of supernumerary phantom limb. *Brain* 2002; **125**(Part 6): 1265–1274.
- Maynard Jr FM, Bracken MB, Creasey G, Ditunno Jr JF, Donovan WH, Ducker TB *et al*. International standards for neurological and functional classification of spinal cord injury. American spinal injury association. *Spinal Cord* 1997; **35**: 266–274.
- Botvinick M, Cohen J. Rubber hands 'feel' touch that eyes see. *Nature* 1998; **391**: 756.
- Tsakiris M, Haggard P. The rubber hand illusion revisited: visuotactile integration and self-attribution. *J Exp Psychol: Hum Percept Perform* 2005; **31**: 80–91.
- Ehrsson HH, Rosén B, Stocksélius A, Ragnö C, Köhler P, Lundborg G. Upper limb amputees can be induced to experience a rubber hand as their own. *Brain* 2008; **131**(Part 12): 3443–3452.
- Giummarra MJ, Georgiou-Karistianis N, Nicholls ME, Gibson SJ, Bradshaw JL. The phantom in the mirror: a modified rubber-hand illusion in amputees and normals. *Perception* 2010; **39**: 103–118.
- Strömer S, Gerner HJ, Grüniger W, Metzmacher K, Föllinger S, Wienke C *et al*. Chronic pain/dysaesthesiae in spinal cord injury patients: results of a multicentre study. *Spinal Cord* 1997; **35**: 446–455.
- Widerstrom-Noga E, Biering-Sorensen F, Bryce T, Cardenas DD, Finnerup NB, Jensen MP *et al*. The international spinal cord injury pain basic data set. *Spinal Cord* 2008; **46**: 818–823.
- Bors E. Phantom limbs of patients with spinal cord injury. *AMA Arch Neurol Psychiatry* 1951; **66**: 610–631.
- Siddall PJ, McClelland JM, Rutkowski SB, Cousins MJ. A longitudinal study of the prevalence and characteristics of pain in the first 5 years following spinal cord injury. *Pain* 2003; **103**: 249–257.
- Barrett H, McClelland JM, Rutkowski SB, Siddall PJ. Pain characteristics in patients admitted to hospital with complications after spinal cord injury. *Arch Phys Med Rehabil* 2003; **84**: 789–795.
- Woodhouse A. Phantom limb sensation. *Clin Exp Pharmacol Physiol* 2005; **32**: 132–134.
- Wilkins KL, McGrath PJ, Finley GA, Katz J. Prospective diary study of nonpainful and painful phantom sensations in a preselected sample of child and adolescent amputees reporting phantom limbs. *Clin J Pain* 2004; **20**: 293–301.
- Schley MT, Wilms P, Toepfner S, Schaller HP, Schmelz M, Konrad CJ *et al*. Painful and nonpainful phantom and stump sensations in acute traumatic amputees. *J Trauma* 2008; **65**: 858–864.
- Li CL, Elvidge AR. Observations on phantom limb in a paraplegic patient. *J Neurosurg* 1951; **8**: 524–527.
- Cook AW, Druckemiller WH. Phantom limb in paraplegic patients; report of two cases and an analysis of its mechanism. *J Neurosurg* 1952; **9**: 508–516.
- Bakheit AM. Phantom limb sensations after complete thoracic transverse myelitis. *J Neurol Neurosurg Psychiatry* 2000; **69**: 275–276.
- de Andres C, Gil R, Lopez L, Salinero E, Bittini A. Nonpainful phantom sensation, illusory limb movement in a patient with

- dorsal myelitis. Neuropathological and SPECT findings. *J Neurol* 2002; **249**: 930–932.
- 29 Ettl TM, Seiler W, Kaeser HE. Phantom and amputation illusions in paraplegic patients. *Eur Neurol* 1980; **19**: 12–19.
- 30 Davis R. Pain and suffering following spinal cord injury. *Clin Orthop Relat Res* 1975; **112**: 76–80.
- 31 Ohry A, Gur S, Zeilig G. Duplicate limbs' sensation in acute traumatic quadriplegia. *Paraplegia* 1989; **27**: 257–260.
- 32 Reichert K, Sewekow K. A man with 3 arms. Phantom limb perception in intramedullary ependymoma]. *Nervenarzt* 2002; **73**: 548–551.
- 33 Potzl O. Theory of the mechanism involved in the pathogenesis of the phantom limb.]. *Wien Med Wochenschr* 1950; **100**: 564–569.
- 34 Biran I, Chatterjee A. Alien hand syndrome. *Arch Neurol* 2004; **61**: 292–294.
- 35 Kikkert MA, Ribbers GM, Koudstaal PJ. Alien hand syndrome in stroke: a report of 2 cases and review of the literature. *Arch Phys Med Rehabil* 2006; **87**: 728–732.
- 36 Naito E, Nakashima T, Kito T, Aramaki Y, Okada T, Sadato N. Human limb-specific and non-limb-specific brain representations during kinesthetic illusory movements of the upper and lower extremities. *Eur J Neurosci* 2007; **25**: 3476–3487.
- 37 Melzack R. Phantom limbs and the concept of a neuromatrix. *Trends Neurosci* 1990; **13**: 88–92.
- 38 Giummarra MJ, Gibson SJ, Georgiou-Karistianis N, Bradshaw JL. Central mechanisms in phantom limb perception: the past, present and future. *Brain Res Rev* 2007; **54**: 219–232.
- 39 Mercier C, Reilly KT, Vargas CD, Aballea A, Sirigu A. Mapping phantom movement representations in the motor cortex of amputees. *Brain* 2006; **129**(Part 8): 2202–2210.
- 40 Willoch F, Rosen G, Tolle TR, Oye I, Wester HJ, Berner N *et al*. Phantom limb pain in the human brain: unraveling neural circuitries of phantom limb sensations using positron emission tomography. *Ann Neurol* 2000; **48**: 842–849.
- 41 Roux FE, Lotterie JA, Cassol E, Lazorthes Y, Sol JC, Berry I. Cortical areas involved in virtual movement of phantom limbs: comparison with normal subjects. *Neurosurgery* 2003; **53**: 1342–1352; discussion 1352–1353.
- 42 Karl A, Muhlneckel W, Kurth R, Flor H. Neuroelectric source imaging of steady-state movement-related cortical potentials in human upper extremity amputees with and without phantom limb pain. *Pain* 2004; **110**: 90–102.
- 43 Reilly KT, Mercier C, Schieber MH, Sirigu A. Persistent hand motor commands in the amputees' brain. *Brain* 2006; **129**(Part 8): 2211–2223.
- 44 Kokotilo KJ, Eng JJ, Curt A. Reorganization and preservation of motor control of the brain in spinal cord injury: a systematic review. *J Neurotrauma* 2009; **26**: 2113–2126.
- 45 Hotz-Boendermaker S, Funk M, Summers P, Brugger P, Hepp-Reymond MC, Curt A *et al*. Preservation of motor programs in paraplegics as demonstrated by attempted and imagined foot movements. *Neuroimage* 2008; **39**: 383–394.
- 46 Halder P, Curt A, Brem S, Lang-Dullenkopf A, Bucher K, Kollias S *et al*. Preserved aspects of cortical foot control in paraplegia. *Neuroimage* 2006; **31**: 692–698.
- 47 Alkadhi H, Brugger P, Boendermaker SH, Crelier G, Curt A, Hepp-Reymond MC *et al*. What disconnection tells about motor imagery: evidence from paraplegic patients. *Cereb Cortex* 2005; **15**: 131–140.
- 48 Staub F, Bogousslavsky J, Maeder P, Maeder-Ingvar M, Fornari E, Ghika J *et al*. Intentional motor phantom limb syndrome. *Neurology* 2006; **67**: 2140–2146.
- 49 Giroux P, Sirigu A. Illusory movements of the paralyzed limb restore motor cortex activity. *Neuroimage* 2003; **20**(Suppl 1): S107–S111.
- 50 Gustin SM, Wrigley PJ, Gandevia SC, Middleton JW, Henderson LA, Siddall PJ. Movement imagery increases pain in people with neuropathic pain following complete thoracic spinal cord injury. *Pain* 2008; **137**: 237–244.