

Neurological complications without eclampsia during pregnancy in Turkey

Deniz Yerdelen and Mehmet Karataş

Department of Neurology, Baskent University Faculty of Medicine, Adana, Turkey

Abstract

Aim: Some neurological diseases associated with pregnancy may develop initially during gestation, pregnancy may predispose the patient to some of these diseases or some may occur only with pregnancy. The aim of this study is to draw attention to the rare neurological diseases – other than eclampsia – that develop during pregnancy or the diseases initially described as associated with pregnancy.

Methods: Our sample comprised of 16 pregnant women who developed neurological disorders that are rarely encountered or initially reported during this phase, eclampsia excluded.

Results: The proportion of cerebrovascular diseases was 56%. The others included intracranial hypotension accompanied by seizures, cerebral primitive neuroectodermal tumor, ophthalmoplegic migraine, hemiplegic migraine, spinal segmental myoclonus, acute motor axonal neuropathy and acute motor axonal neuropathy associated with ophthalmoplegia.

Conclusion: Our results suggest that by adopting a careful and correct approach and accurate neurological diagnosis, most of these patients could be treated successfully with good prognosis of the newborns.

Key words: acute motor axonal neuropathy, cerebral primitive neuroectodermal tumor, cerebrovascular diseases, neurological diseases, pregnancy.

Introduction

Some physiological changes, such as the type of circulating steroid hormones and their concentration, during pregnancy could influence the expression of neurological disease. Neurological disorders that affect women of child-bearing age can lead to maternal morbidity and mortality. During diagnosis and therapy of these diseases, some restrictions or even a contraindication might be encountered because of the pregnancy itself. Some diseases, such as migraine, multiple sclerosis, myasthenia gravis, epilepsy, brain tumors, or Guillain-Barré syndrome, could exist already before the onset of pregnancy or may appear merely by chance during this phase. Moreover, pregnancy itself is a predisposing factor for a variety of thromboembolic disorders. Pre-eclampsia/eclampsia, hemolysis, elevated liver enzyme

and low platelet (HELLP) syndrome, amniotic fluid embolism, and pituitary apoplexy are diseases with neurological symptoms that occur only with pregnancy.^{1,2}

In this study, neurological disorders rarely seen or reported for the first time and that developed initially during pregnancy are presented, eclampsia excluded.

Methods

The study, encompassing the years 2005–2008, involved 16 pregnant women who were consulted prospectively because of neurological complications; eclampsia was excluded. All the patients and/or their families were asked to provide the history of their diseases. After detailed neurological examinations,

Received: September 23 2009.

Accepted: March 8 2010.

Reprint request to: Associate Professor Deniz Yerdelen, Baskent University Faculty of Medicine, Adana Teaching and Research Center, Dadaloğlu Mah. 39 Sok., Yüreğir, Adana 01250, Turkey. Email: yerdelend@gmail.com

necessary study tests were conducted. Patients or their relatives gave informed consent for the examinations. Besides routine biochemical tests, tests for total blood count, urine analysis, and sedimentation were done for all of the patients. For patients with clinical findings of stroke and intracranial hypertension, cerebral magnetic resonance imaging (MRI) and cerebral venography were performed. Where the MRI did not show any mass lesion and if visual disturbances and papilloedema were documented, cerebrospinal fluid pressure (CSF) was measured by lumbar puncture.

Nerve conduction studies of patients with signs and symptoms of polyneuropathy and measurements of visual evoked potentials of patients with visual disturbances and papilloedema with blurring of the disc margins were performed using a two-channel electromyography machine.

To investigate further causative factors apart from pregnancy, infectious tests for polyneuropathies and coagulation tests for cerebrovascular diseases were carried out.

Results

The mean age of the sample of 16 pregnant women was 27.8 ± 7.4 years and pregnancy duration was 22.5 ± 11.2 weeks. The percentage of the patients with cerebrovascular diseases apart from eclampsia was 56%. Cerebral venous sinus thrombosis (CVST) constituted 33% of these cerebrovascular diseases. Nine patients (Cases 1–9) diagnosed with cerebrovascular diseases were as follows: two cases of CVST and intracranial hypertension, two of transient ischemic attack (TIA), one of CVST and cerebral infarct, one of cerebral infarct, one of cerebellar infarct, one of reversible ischemic neurological deficit (RIND), and one of bilateral jugular and subclavian vein thrombosis. The remaining seven patients had other neurological diseases as follows: Case 10 had cerebral primitive neuroectodermal tumor (Figs 1,2), Case 11 had intracranial hypotension and seizures, Case 12 had ophthalmoplegic migraine, Case 13 had hemiplegic migraine, Case 14 had spinal segmental myoclonus, Case 15 had acute

Figure 1 A cystic mass (size: $5.5 \times 4.5 \times 2.5$ cm) lying from inferior gyrus of the left frontal lobe to the temporal lobe causing 1.5-cm subfalcine herniation, revealing slight contrast and accompanied by a solid component on the posteolateral is observed on the preoperative T1-weighted magnetic resonance images of the brain of Case 10.

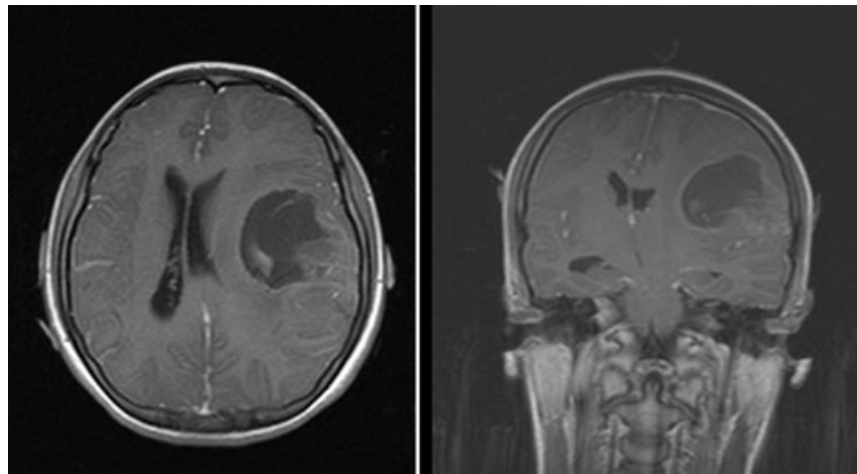
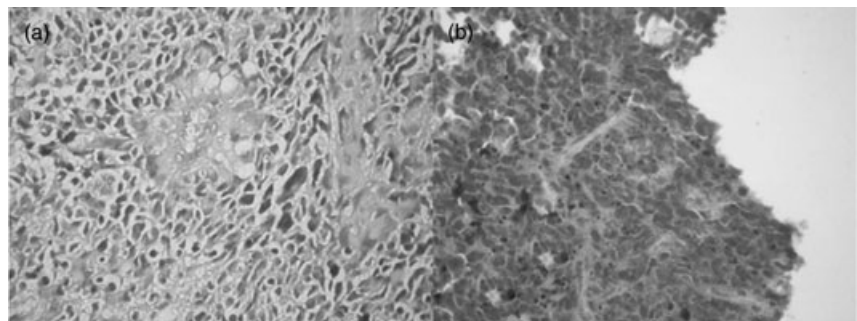


Figure 2 (a) The arrangement of the tumor cells with pleomorphic and hyperchromatic nucleus in perivascular rosette formation (hematoxylin–eosin $\times 400$). (b) The positivity of synaptophysin in the cytoplasm of tumor cells ($\times 400$).



motor axonal neuropathy, and Case 16 had acute motor axonal neuropathy and ophthalmoplegia (Table 1).

Case 2 (diagnosed with CVST) and Case 9 (with jugular venous thrombosis) had become pregnant by *in vitro* fertilization (IVF). Case 1 with CVST also had 5,10-methylenetetrahydrofolate reductase (MTHFR) C677T heterozygote mutation, protein S deficiency and activated protein C resistance (Fig. 3). Case 3 with cerebellar infarct was older, and Case 6 with cerebral infarct had mitral valve repair (MVR) with irregular anticoagulant therapy usage; one of the two patients with TIA was found to have von Willebrand factor (vWF) deficiency (Case 4), and the other had MTHFR homozygote mutation (Case 5).

Seven patients (Cases 1–5, 7 and 8) were treated with low-molecular-weight heparin. Case 9 with jugular venous thrombosis had missed abortion. She underwent embolectomy, and then treatment was continued with warfarin. The gestation age of Case 6 with cerebral infarct and MVR was 30 weeks, and she had irregular anticoagulant therapy usage. Warfarin was continued until the last 3 weeks of pregnancy, and she was treated with heparin in the last 3 weeks according to the advice of the cardiologist and the obstetrician.

Because of medical indications, term labor was induced in nine patients, and preterm labor in five patients. One suffered missed abortion and one abortion was performed at the patient's request. The 14 newborns delivered were healthy; however, those delivered preterm were hospitalized in a newborn unit for a while. Twelve patients recovered completely, and three with mild-to-moderate sequel findings. The patient with neuroectodermal tumor died due to complications associated with the tumor (Table 1).

Clinical Courses in Specific Cases

Case 10 (primitive neuroectodermal tumor): Our patient had undergone surgery for the resection of the tumor. Three months later, because of the deterioration of the clinical status of the patient, cesarean delivery was performed, and the intracranial hematoma that developed was evacuated. However, the patient did not recover and died.

Case 11 (spontaneous intracranial hypotension): According to clinical findings, CSF pressure, and cerebral MRI features, Case 11 was diagnosed as having spontaneous intracranial hypotension, and developed seizures during this condition. She improved with bedrest and liquid support and the seizures were controlled with antiepileptic drug treatment.

Case 12 (ophthalmological migraine): The patient in our sample diagnosed with ophthalmological migraine was treated with prednisolone; patient outcomes of both the mother and her baby turned out very well.

Case 13 (hemiplegic migraine): Our patient's symptoms and signs of hemiplegic migraine resolved spontaneously. MRI and MR venography performed to exclude cerebrovascular diseases were normal.

Case 14 (spinal segmental myoclonus): We previously reported a unique case with spinal segmental myoclonus during pregnancy.³ Abdominal rhythmic myoclonus, not in contact with labor, in a 33-year-old pregnant woman (gestational age, 39 weeks and 2 days) was recorded. The involuntary contractions had disappeared within two days after delivery. The explanation for this clinical picture was disorder of spinal cord circulation due to pressure on the intra-abdominal vascular structures of the mass effect.

Cases 15 and 16 (acute motor axonal neuropathy [AMAN]): Our patient with AMAN improved almost completely with plasmapheresis treatment. However, the case with external ophthalmoplegia showed minimal improvement with plasma exchange (PE) and intravenous immunoglobulin (IVIg) treatments, and she was monitored in the intensive care unit for a long time and ventilation was required for some time. She continues to receive rehabilitation therapy.

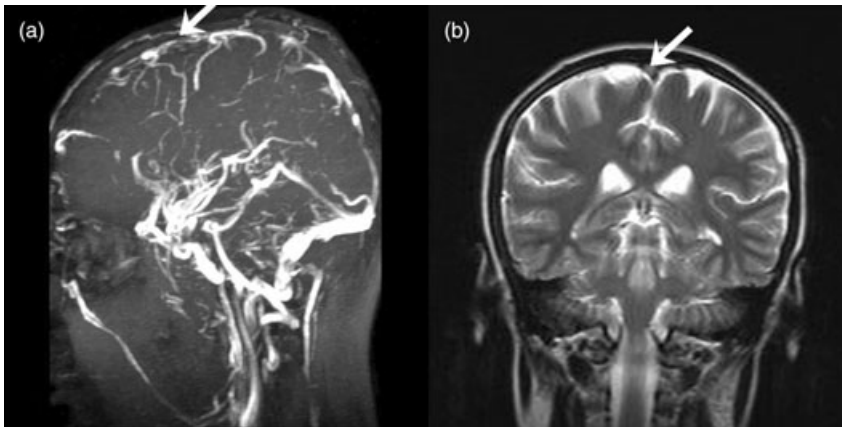
Discussion

In our case series, we determined the most frequent cerebrovascular diseases during pregnancy apart from eclampsia (56%). CVST constituted 33% of these cerebrovascular diseases. Pregnancy is a condition in which the risk of thrombotic diseases increases. Pregnancy itself is a predisposing factor for thrombosis. During normal pregnancy, the coagulant and anti-coagulant pathways of blood coagulation, and the fibrinolytic pathway undergo a series of changes.⁴ The plasma concentration of several proteins and their activities undergo change and a hemostatic imbalance towards a prothrombotic state develops. Procoagulant factors (such as VIII, XII, VII, V) and the vWF and fibrinogen are accentuated, protein S and the activated protein C resistance are reduced and fibrinolytic activity is diminished.⁵ Placenta and myometrium also contribute to a high concentration of a specific fibrinolytic inhibitor during normal pregnancy.⁶ In addition, the hormonal changes that occur during pregnancy tilt the thrombohemorrhagic balance towards thrombosis. As a result of all these changes or as the first manifestation

Table 1 Features of the patients

Case no.	Age	Gestation (weeks)	Neurological disease	Pregnancy outcome	Neonatal outcome	Maternal outcome	Cause	Specific treatment
1	21	11	CVST + ICHyperT	Term	Healthy	Sequel	Coagulation disorder	LMWH
2	39	6	CVST + hemorrhagic infarct	Term	Healthy	Sequel	IVF	LMWH
3	43	10	Left cerebellar infarct	Terminated	Medical abortus	Recovery	Age	LMWH
4	31	35	TIA	Preterm	Healthy	Recovery	vWF deficiency	LMWH
5	27	15	TIA	Term	Healthy	Recovery	MTHFR Homozygote mutation	LMWH
6	22	30	Cerebral infarct	Preterm	Healthy	Recovery	MVR	Oral anticoagulant-heparin
7	21	26	CVST + ICHyperT	Term	Healthy	Recovery	-	LMWH
8	27	35	RIND	Preterm	Healthy	Recovery	-	LMWH
9	32	7.5	Headache-jugular venous thrombosis	Missed abortus	Missed abortus	Recovery	IVF	Embolectomy + Oral anticoagulant
10	18	20	PNET	Preterm	Healthy	Exitus	-	Operation for tumor
11	26	30	Headache, seizure, ICHypoT	Term	Healthy	Recovery	-	Anti-epileptic drug
12	33	23	Ophthalmoplegic migraine	Term	Healthy	Recovery	-	Prednisolone
13	25	10	Hemiplegic migraine	Term	Healthy	Recovery	-	-
14	35	39.5	Spinal segmental myoclonus	Term	Healthy	Recovery	-	-
15	17	28	AMAN	Term	Healthy	Recovery	-	PE
16	28	34	AMAN + External ophthalmoplegia	Preterm	Healthy	Sequel	-	PE + IVIg

AMAN, acute motor axonal neuropathy; CVST, cerebral venous sinus thrombosis; ICHyperT, intracranial hypertension; ICHypoT, intracranial hypotension; IVF, *in vitro* fertilization; IVIg, intravenous immunoglobulin; LMWH, low-molecular-weight heparin; MTHFR, 5,10-methylenetetrahydrofolate reductase; MVR, mitral valve repair; PE, plasma exchange; PNET, primitive neuroectodermal tumor; RIND, reversible ischemic neurological deficit; TIA, transient ischemic attack; vWF, von Willebrand factor.



Figures 3 Cerebral (a) magnetic resonance image and (b) venography of Case 1 showed right-sided superior sagittal sinus thrombosis.

of a hereditary thrombophilia, the risk of venous thrombosis in pregnancy increases seven-to-eightfold. However, postpartal venous thrombosis is far more common than antenatal venous thrombosis.⁵ Other risk factors for thrombosis associated with pregnancy are maternal age, hyperemesis, infection, and maternal hypertension. Case 2 (diagnosed with CVST) and Case 9 (with jugular venous thrombosis) had become pregnant by IVF. Case 1 with CVST was found to have MTHFR C677T heterozygote mutation, protein S deficiency, and activated protein C resistance.⁷ Case 3 with cerebellar infarct was older, Case 6 with cerebral infarct had MVR, and Case 4 with TIA was found to have vWF deficiency. Two of our three patients with CVST developed this condition during the first trimester, contradicting reports state CVST mostly occurs during the puerperium or in the last trimester of pregnancy. Although little is known about the incidence of CVST associated with pregnancy or the puerperium, only a small proportion of patients are believed to develop CVST during pregnancy, and 66–80% of cases occur during the puerperium or in the last trimester of pregnancy.⁸

The diagnostic approach of cerebrovascular diseases during pregnancy includes rigorous laboratory and imaging tests if eclampsia or pre-eclampsia are not the cause or if they are only comorbid conditions. A full series of tests may be required, including echocardiogram, MRI, MR angiography or venography and carotid ultrasound. If the cause is still not evident, evaluation of the hypercoagulable state should be performed by evaluating protein C, protein S, antithrombin III, Factor V Leiden, fibrinogen, and antiphospholipid antibodies, in addition to a routine complete blood count, prothrombin time and activated partial thrombo-

plastin time. The hematological tests should be repeated weeks to months postpartum because many of the coagulation system markers may be altered during pregnancy. In the treatment of ischemic stroke and CVST, a platelet antiaggregant, heparin or warfarin, may be used, and sometimes surgery may be required. However, warfarin use should be avoided during pregnancy if it is not absolutely necessary.⁹

The frequency of brain tumor occurrence during pregnancy is the same as in age-matched non-pregnant patients.¹⁰ However, some brain tumors may develop and show initial signs and symptoms during pregnancy. Hormonal changes could affect receptors and trigger tumor growth. The brain tumors seen during pregnancy are glioma, meningioma, and acoustic neuroma, respectively. The diagnosis of primary brain tumors is made by neuroimaging with MRI or computed tomography scanning. In general, MRI scans are preferred because of better tissue resolution and because the magnetic field used is safe and does not affect the fetus. Most intracranial neoplasms are treated by surgical excision. However, surgery in benign tumors, such as meningiomas and in slowly growing low-grade malignant tumors (such as gliomas), may be delayed until after delivery. Symptoms due to pressure on surrounding structures or raised intracranial tension are treated with corticosteroids, preferably with prednisone to reduce tumor edema. If the patient continues to worsen despite maximum conservative measures, surgical excision should be undertaken, regardless of the stage of the pregnancy. High-grade gliomas are surgically excised during pregnancy. Chemotherapy and radiotherapy should be administered only after weighing the risks and benefits.¹⁰ Case 10, who developed supratentorial

primitive neuroectodermal tumor, was the third case of this type of tumor during pregnancy cited in the literature.¹¹⁻¹³ These lesions require diagnostic intervention and treatment, regardless of the gestational age of the fetus because of their poor prognosis. The primary choice in treatment is radical surgical resection.¹¹⁻¹³ Our patient had undergone surgery for the resection of the tumor. However, the clinical status of the patient deteriorated, and she died.

Spontaneous intracranial hypotension is characterized by postural headache associated with low cerebrospinal fluid pressure. MRI generally help to confirm the diagnosis and to localize the site of the cerebrospinal fluid leak. This condition may heal with bedrest, however, an epidural blood patch or a percutaneous injection of fibrin glue may be needed.¹⁴ According to clinical findings, CSF pressure, and cerebral MRI features, Case 11 was diagnosed as having spontaneous intracranial hypotension, and developed seizures during this condition. In the literature, one pregnant woman with spontaneous intracranial hypotension has been reported.¹⁵ However, our patient is the first pregnant case of intracranial hypotension accompanying seizures. These two cases of spontaneous intracranial hypotension indicate that physicians, especially obstetricians, should bear in mind that this condition can occur during pregnancy.

Many types of headache may be triggered during pregnancy because estrogen and other reproductive hormones interact with the trigeminovascular system directly and indirectly affecting blood flow and neurochemical substances. The types of headache most frequently encountered during pregnancy are migraine without aura, and the tension-type headache.^{2,16} History and targeted physical examination are essential factors in the diagnosis of headaches, and almost all can be assigned to a diagnostic group. New-onset migraine in pregnancy, especially with aura, which does not fit the classic scheme of migraine or tension-type headaches, should be carefully investigated for other pathologies. Prophylactic treatment includes low-dose aspirin, amitriptylline, nifedipine and beta-blockers. When migraine occurs during pregnancy, treatment options may be non-narcotic analgesics or triptans.^{2,17} Ophthalmological migraine during pregnancy has not been encountered in the literature. The patient in our sample diagnosed with ophthalmological migraine was treated with prednisolone; patient outcomes of both the mother and her baby turned out very well. Hemiplegic migraine during pregnancy has been rarely reported. This condition may occur during pregnancy with or

without a previous history of such a condition, usually in the third trimester.^{18,19} Our patient's symptoms and signs of hemiplegic migraine resolved spontaneously.

We reported a unique case with spinal segmental myoclonus during pregnancy.³ After delivery the involuntary contractions disappeared within two days. The explanation for this clinical picture was disorder of spinal cord circulation due to pressure on the intra-abdominal vascular structures of the mass effect.

Guillain-Barré syndrome (GBS) during pregnancy has been rarely reported.²⁰ However, its variants, acute motor axonal neuropathy (AMAN) or AMAN + external ophthalmoplegia, have not been encountered in the literature. GBS is suspected when a patient presents with progressive motor weakness and areflexia. Albuminocytological dissociation in cerebrospinal fluid with elevated protein content and a normal mononuclear leukocyte count (10/mm³) and nerve conduction studies can be useful in diagnosing GBS in both non-pregnant and pregnant patients.²¹ In treatment of GBS, i.v. immunoglobulin and plasmapheresis were found to be equally effective, and both of them have been used confidently during pregnancy.²²⁻²⁴ Our patient with AMAN improved almost completely with plasmapheresis treatment. But the case with external ophthalmoplegia showed minimal improvement with PE and IVIg treatments.

The aim of this study was to draw attention to the rare neurological diseases – other than eclampsia – that develop during pregnancy or the diseases initially described as associated with pregnancy. Our results suggest that by adopting a careful and correct approach and accurate neurological diagnosis, most of these patients could be treated successfully with good prognosis of newborns.

References

1. Block F. [Neurologic diseases and pregnancy]. *Nervenarzt* 1999; **70**: 1062–1071.
2. Shehata HA, Okosun H. Neurological disorders in pregnancy. *Curr Opin Obstet Gynecol* 2004; **16**: 117–122.
3. Yerdelen D, Karataş M, Aslan E, Giray S, Tan M. Spinal segmental myoclonus related to pregnancy. *Acta Neurol Belg* 2007; **107**: 11–13.
4. De Santis M, Cavaliere AF, Straface G, Di Gianantonio E, Caruso A. Inherited and acquired thrombophilia: pregnancy outcome and treatment. *Reprod Toxicol* 2006; **22**: 227–233.
5. Vora S, Ghosh K, Shetty S, Salvi V, Satoskar P. Deep venous thrombosis in the antenatal period in a large cohort of pregnancies from western India. *Thromb J* 2007; **5**: 9.
6. Uszynski M, Maciejewski K, Uszynski W, Kuczyński J. Placenta and myometrium – the two main sources of fibrinolytic

- components during pregnancy. *Gynecol Obstet Invest* 2001; **52**: 189–193.
7. Yerdelen D, Ozdogu H, Karatas M, Pelit A, Yildirim T. Cerebral venous thrombosis in pregnancy associated with MTHFR C677 T mutation, protein S deficiency, and activated protein C resistance during pregnancy. *Neurosurg Q* 2009; **19**: 144–146.
 8. Karnad DR, Guntupalli KK. Neurologic disorders in pregnancy. *Crit Care Med* 2005; **33**: S362–S371.
 9. Skidmore FM, Williams LS, Fradkin KD, Alonso RJ, Biller J. Presentation, etiology, and outcome of stroke in pregnancy and puerperium. *J Stroke Cerebrovasc Dis* 2001; **10**: 1–10.
 10. Stevenson CB, Thompson RC. The clinical management of intracranial neoplasms in pregnancy. *Clin Obstet Gynecol* 2005; **48**: 24–37.
 11. Bodner-Adler B, Bodner K, Zeisler H. Primitive neuroectodermal tumor (PNET) of the brain diagnosed during pregnancy. *Anticancer Res* 2006; **26**: 2499–2501.
 12. Olivieri S, Oliveri G, Filosomi F, Petraglia F. Supratentorial primitive neuroectodermal tumor during pregnancy. *Minerva Ginecol* 2007; **59**: 199–201.
 13. Sarica FB, Tufan K, Sen O, Therapeutic EB. Difficulty in a case of supratentorial primitive neuroectodermal tumor diagnosed during pregnancy. *J Korean Neurosurg Soc* 2009; **45**: 39–42.
 14. Gordon N. Spontaneous intracranial hypotension. *Dev Med Child Neurol* 2009; **51**: 932–935.
 15. Asakura H, Hayashi Z, Seto M, Araki T. Spontaneous intracranial hypotension during pregnancy. *Obstet Gynecol* 2001; **97**: 804–805.
 16. Von Wald T, Walling AD. Headache during pregnancy. *Obstet Gynecol Surv* 2002; **57**: 179–185.
 17. Nezvalová-Henriksen K, Spigset O, Nordeng H. Maternal characteristics and migraine pharmacotherapy during pregnancy: cross-sectional analysis of data from a large cohort study. *Cephalalgia* 2009; **29**: 1267–1276.
 18. Gonzalez-Alegre P, Tippin J. Prolonged cortical electrical depression and diffuse vasospasm without ischemia in a case of severe hemiplegic migraine during pregnancy. *Headache* 2003; **43**: 72–75.
 19. Barbour PJ, Castaldo JE, Shoemaker EI. Hemiplegic migraine during pregnancy: unusual magnetic resonance appearance with SPECT scan correlation. *Headache* 2001; **41**: 310–316.
 20. Chan LY, Tsui MH, Leung TN. Guillain-Barré syndrome in pregnancy. *Acta Obstet Gynecol Scand* 2004; **83**: 319–325.
 21. Asbury AK, Cornblath DR. Assessment of current diagnostic criteria for Guillain-Barré syndrome. *Ann Neurol* 1990; **27** (Suppl): S21–S24.
 22. Watson WJ, Katz VL, Bowes WA Jr. Plasmapheresis during pregnancy. *Obstet Gynecol* 1990; **76**: 451–457.
 23. Branch DW, Porter TF, Paidas MJ, Belfort MA, Gonik B. Obstetric uses of intravenous immunoglobulin: successes, failures, and promises. *J Allergy Clin Immunol* 2001; **108** (Suppl. 4): S133–S138.
 24. Hughes RA, Swan AV, Raphaël JC, Annane D, van Koningsveld R, van Doorn PA. Immunotherapy for Guillain-Barré syndrome: a systematic review. *Brain* 2007; **130**: 2245–2257.