

7. O'Keefe J. Place units in the hippocampus of the freely moving rat. *Exp Neurol* 1976;**51**:78–109.
8. O'Keefe J, Burgess N. Dual phase and rate coding in hippocampal place cells: theoretical significance and relationship to entorhinal grid cells. *Hippocampus* 2005;**15**:853–66.
9. Ekstrom AD, Kahana MJ, Caplan JB, et al. Cellular networks underlying human spatial navigation. *Nature* 2003;**425**:184–8.
10. Burgess N. Spatial memory: how egocentric and allocentric combine. *Trends Cogn Sci* 2006;**10**:551–7.
11. Thinus-Blanc C, Gaunet F. Representation of space in blind persons: vision as a spatial sense? *J Visual Impair Blindness* 1997;**86**:221–4.
12. Wolbers T, Buchel C. Dissociable retrosplenial and hippocampal contributions to successful formation of survey representations. *J Neurosci* 2005;**25**:3333–40.

doi:10.1016/j.jocn.2010.06.009

Movement-induced focal tonic–clonic seizure-like movements after ipsilateral basal ganglia hemorrhage

Dong-Ha Lee^a, Dong Wook Kim^b, Han-Joon Kim^{c,*}^a Department of Neurology, Inje University Ilsan Paik Hospital, Goyang-si, Gyeonggi-do, Republic of Korea^b Department of Neurology, Konkuk University Medical Center, Seoul, Republic of Korea^c Department of Neurology and the Movement Disorder Center, Clinical Research Institute, College of Medicine, Seoul National University, 28 Yongon-dong, Chongno-gu, Seoul 110-744, Republic of Korea

ARTICLE INFO

Article history:

Received 18 June 2009

Accepted 29 May 2010

Keywords:

Basal ganglia hemorrhage

Ipsilateral

Involuntary movement

Tonic–clonic seizure

ABSTRACT

We present a 46-year-old man who developed repetitive focal tonic–clonic seizure-like involuntary movement in the left lower extremity after a left basal ganglia (BG) hemorrhage. His symptoms were induced only by voluntary movement of the left lower extremity and were followed by transient paralysis. Electroencephalography during an attack showed no epileptiform discharges. Carbamazepine completely abolished his symptoms. This report implies that damage to the BG and/or its connections might cause seizure-like involuntary movement.

© 2010 Elsevier Ltd. All rights reserved.

1. Introduction

Many different types of abnormal involuntary movement (AIM) are associated with lesions of the basal ganglia (BG). Among the AIM, dystonia is the most common, but chorea, tremor, parkinsonism, and myoclonus have also been reported.^{1,2} We describe a man who developed movement-induced focal tonic–clonic seizure-like movements after an ipsilateral BG hemorrhage.

2. Case report

A 46-year-old man with no significant medical history was referred to our department due to repetitive AIM in the left leg. Three weeks earlier, he had suddenly developed right hemiplegia. A brain CT scan in the emergency room revealed a left BG hemorrhage accompanied by intraventricular hemorrhage (Fig. 1A). After immediate evacuation of the hematoma, the right hemiplegia improved and only mild weakness remained on the right side. One week later, he developed recurrent paroxysmal painful muscle contractions in the left calf. The attacks were only induced by voluntary movement of the left leg: usually during walking or when he raised his left leg while lying in bed. Sensory stimuli, such as touch or pain, did not provoke an attack. Each attack started with painful tonic spasm of the left distal leg, which lasted 10 s to 30 s (Supplementary Video). The tonic spasm was followed by a clonus-like jerking movement that lasted for about 1 minute. After the clonus-like movement ceased, transient monoplegia and hypesthesia in the left leg followed, which lasted a few

minutes. The patient's consciousness was not impaired during an attack. During the next 10 days, the attacks became more frequent, occurring 30 times per day, with spread to the proximal muscles: first the left distal leg, then the left hamstrings, and eventually the left flank muscles.

The neurologic examination between attacks revealed a mild right hemiparesis (Medical Research Council grade IV). The sensory and mental status examinations were normal. The laboratory tests were normal except for a random blood glucose concentration of 419 mg/dL. The brain MRI performed on day 7 after the development of involuntary movement showed high signal intensity in the left BG on the T2-weighted MRI and mixed signal intensity on the T1-weighted MRI (Fig. 1B, C). An electroencephalogram (EEG) performed on day 14 showed persistent slowing in the theta range in all leads with no epileptiform discharge, even though the patient had an attack during EEG monitoring.

The involuntary movements disappeared completely 1 week after treatment with carbamazepine, which was discontinued without recurrence or symptoms. He was also treated for newly diagnosed diabetes mellitus from the first day of hospitalization. Despite vigorous treatment, he sometimes had hyperglycemia in the range of 300–400 mg/dL of glucose, particularly in the evening. Intermittent hyperglycemia continued even after the remission of involuntary movements.

3. Discussion

Although the AIM of the patient described in this report was not completely characterized, it had many features in common with simple partial seizures. First, the AIM began with painful tonic posturing of the leg and subsequent clonic jerking movements, fol-

* Corresponding author. Tel.: +82 2 2072 2237; fax: +82 2 3672 7553.

E-mail address: movement@snuh.org (H.-J. Kim).

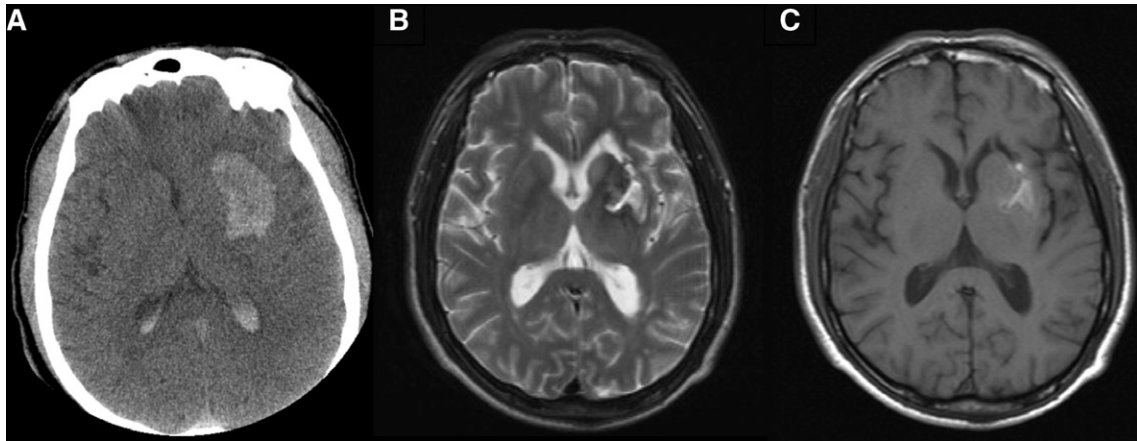


Fig. 1. (A) Initial CT scan showing left basal ganglia (BG) hemorrhage accompanied by intraventricular hemorrhage. (B, C) Brain MRI performed on day 7 after development of the involuntary movements showing a high signal intensity lesion in the left BG on (B) the T2-weighted MRI and a mixed signal intensity on (C) the T1-weighted MRI.

lowed by transient motor weakness and sensory deficits, which are typical for tonic–clonic seizures and postictal Todd's paralysis. Second, the AIM in our patient had an excellent response to anti-epileptic drugs. The lack of epileptiform discharges on the EEG, even during an attack, would not be inconsistent with a diagnosis of epilepsy because it is not uncommon for a scalp EEG to lack abnormalities in simple partial seizures.³

However, provocation by voluntary movements, as in our patient, is not a typical feature of focal tonic–clonic seizures. Involuntary movements of cortical origin such as cortical myoclonus can be precipitated by movement, but in such instances there is no tonic posturing phase that precedes the clonic movements, as was seen in our patient. In patients with paroxysmal kinesigenic choreoathetosis, AIM can be provoked by voluntary movement, but the phenomenology is different to the AIM of our patient. Another well-known movement-induced involuntary movement is reflex epilepsy in non-ketotic hyperglycemia (NKH).^{4,5} Because our patient had intermittent hyperglycemia, we cannot fully exclude a diagnosis of movement-induced reflex epilepsy associated with hyperglycemia. However, in reflex epilepsy in NKH, seizures are usually of the clonic type, although tonic–clonic seizures and impairment of consciousness have been described,^{5–7} and most EEG will show epileptiform discharges. Anti-epileptic drugs are usually ineffective and seizure control is achieved with control of the glucose level. Our patient had no EEG changes during attacks and the involuntary movements had an excellent response to antiepileptic drugs. More importantly, involuntary movements occurred even in the normoglycemic state and the blood glucose levels were not different before and after remission of involuntary movements.

It is difficult to explain the relationship between the BG hemorrhage and the tonic–clonic seizure-like movements in our patient. One may argue that the BG hemorrhage was not associated with the development of the AIM, but was just a coincidence. However, because our patient had no history of AIM before the BG hemorrhage, we believe that the left BG hemorrhage was related to the AIM in our patient. Indeed, there is evidence for subcortical structures being involved in the generation of tonic–clonic seizures.^{8,9} Furthermore, the BG have an important role in the regulation of seizures.¹⁰ It is thus plausible to think that disruption of the BG and/or the connections to cortical structures by hemorrhage might have caused seizure-like movements in our patient. However, we cannot exclude the possibility that the frontal cortical lesion made during stereotactic hematoma evacuation caused the AIM in our patient.

Another interesting feature of our patient was that the AIM occurred ipsilateral to the BG lesion. Unilateral tonic posturing and clonus ipsilateral to an epileptogenic region can occur in frontal lobe epilepsy.¹¹ Ipsilateral epilepsy partialis continua with periodic lateralized frontal epileptiform discharges has also been reported in a patient with massive frontal lobe damage.¹² Furthermore, Guak et al.¹³ reported a patient who developed repetitive attacks of unilateral irregular throwing-like arm movement followed by tonic posturing, reminiscent of our patient, with an ipsilateral thalamic lesion. The mechanism for these involuntary movements ipsilateral to the cerebral lesion is poorly understood, although projections from the premotor area to subcortical motor areas such as medullary reticular formation has been implicated.¹²

Appendix A. Supplementary material

Supplementary data associated with this article can be found, in the online version, at doi:10.1016/j.jocn.2010.05.029.

References

- Bhatia KP, Marsden CD. The behavioural and motor consequences of focal lesions of the basal ganglia in man. *Brain* 1994;**117**:859–76.
- Handley A, Medcalf P, Hellier K, et al. Movement disorders after stroke. *Age Ageing* 2009;**38**:260–6.
- Devinsky O, Kelley K, Porter RJ, et al. Clinical and electroencephalographic features of simple partial seizures. *Neurology* 1988;**38**:1347–52.
- Brick JF, Gutrecht JA, Ringel RA. Reflex epilepsy and nonketotic hyperglycemia in the elderly: a specific neuroendocrine syndrome. *Neurology* 1989;**39**:394–9.
- Hennis A, Corbin D, Fraser H. Focal seizures and non-ketotic hyperglycaemia. *J Neurol Neurosurg Psychiatry* 1992;**55**:195–7.
- Siddiqi ZA, VanLandingham KE, Husain AM. Reflex seizures and non-ketotic hyperglycemia: an unresolved issue. *Seizure* 2002;**11**:63–6.
- Suárez-Moro R, Salas-Puig M, Amorín M, et al. SPECT findings in reflex seizures induced by movement in non-ketotic hyperglycemia. *Epileptic Disord* 1999;**1**:199–201.
- Blumenfeld H, Varghese GI, Purcaro MJ, et al. Cortical and subcortical networks in human secondarily generalized tonic-clonic seizures. *Brain* 2009;**132**:999–1012.
- Gale K. Subcortical structures and pathways involved in convulsive seizure generation. *J Clin Neurophysiol* 1992;**9**:264–77.
- Blandini F, Fancelli R, Armentero MT, et al. Unilateral lesion of the subthalamic nucleus enhances cortical fos expression associated with focally evoked seizures in the rat. *Brain Res* 2006;**1101**:145–50.
- Janszky J, Fogarasi A, Jokeit H, et al. Lateralizing value of unilateral motor and somatosensory manifestations in frontal lobe seizures. *Epilepsy Res* 2001;**43**:125–33.
- Young GB, Blume WT. Periodic lateralized frontal epileptiform discharges with ipsilateral epilepsy partialis continua. *Epilepsia* 2007;**48**:597–8.
- Guak TH, Kim YI, Park SM, et al. Paroxysmal focal dystonia in neuro-Behçet by a small ipsilateral thalamic lesion. *Eur Neurol* 2002;**47**:183–4.